

## Effects of Oral Administration of Red Palm Oil on Dichlorvos Induced Testicular Toxicity and Sperm Parameters in Albino Rats

I. K. Lawal<sup>1\*</sup>, A. D. Olasupo<sup>1,2</sup>, A. A. Adekanmi<sup>3</sup>, M. T. Afolabi<sup>4</sup>, O. A. Owolabi<sup>1</sup>  
and I. O. Aina<sup>1</sup>

<sup>1</sup>Department of Science Laboratory Technology, Osun State College of Technology, Esa-Oke, Nigeria.

<sup>2</sup>Department of Industrial Chemistry, Federal University, Oye-Ekiti, Nigeria.

<sup>3</sup>Raw Materials Research and Development Council (RMRDC), Abuja, Nigeria.

<sup>4</sup>Department of Physiology, Ladoké Akintola University of Technology, P.M.B 4000, Ogbomosho, Oyo State, Nigeria.

### Authors' contributions

This work was carried out in collaboration among all authors. Authors IKL, ADO and MTA were responsible for study designed and supervision of the research. Authors IKL and MTA performed the statistical analysis and wrote the protocol. Authors IKL and ADO wrote the first draft of the manuscript. Authors AAA and OAO managed the analyses of the study. Author IOA managed the literature searches. All authors read and approved the final manuscript.

### Article Information

#### Editor(s):

(1) Dr. Punit Bansal, RG Stone and Superspeciality Hospital, India.

#### Reviewers:

(1) Kadry M. Sadek, Damahour University, Egypt.

(2) Naresh Chandra, SVPUAT, India.

Complete Peer review History: <http://www.sdiarticle4.com/review-history/64667>

Original Research Article

Received 15 November 2020

Accepted 21 January 2021

Published 13 February 2021

### ABSTRACT

Dichlorvos (2, 2-Dichlorovinyl Dimethyl Phosphate also known as DDVP) is an organophosphate pesticide/ insecticide having oncogenic, genotoxic, neurotoxic and reproductive toxicity effects on the body. *Elaeis guineensis* (Palm oil) is an edible vegetable oil derived from the mesocarp (reddish pulp) of fruit of the oil with antioxidant properties, beta-carotene content with highly saturated vegetable fats and is semi-solid at room temperature. This study was carried out to investigate the effects of oral administration of Red Palm Oil (RPO) on Dichlorvos (DDVP) induced testicular toxicity and sperm parameters in male albino rats. Concentration of 1ml of DDVP was diluted in 1000mls of distilled water and kept in a bottle for 3 days. 2 mls of red palm oil, 2 mls of

\*Corresponding author: Email: [hearthoyeabi@gmail.com](mailto:hearthoyeabi@gmail.com);

red palm oil plus 1 ml of diluted DDVP, 1ml of diluted DDVP and 1 ml ordinary water were administered orally for 14 days respectively. Sperm parameters carried out were sperm count, motility, morphology and testicular histology analysis. The result obtained showed that DDVP administration significantly decrease sperm count, motility and morphological analysis ( $p < 0.05$ ). There is no significant difference in the value obtained for RPO induced rats in sperm count but significantly decrease in sperm motility and morphological analysis when compared with the value of the control ( $p < 0.05$ ). However, the group administered with RPO + DDVP shows significant increase in sperm count only. RPO histological analysis shows increase and well-formed seminiferous tubules with increase spermatogenic cells while DDVP shows laminar vacuolation, cellular degeneration and disruptions of seminiferous tubules. The group administered with RPO + DDVP shows an improving spermatogenic cells and normal seminiferous tubules. Therefore, this study establishes that RPO could offer positive protection against DDVP induced testicular damages.

**Keywords:** Red palm oil; dichlorvos; testis; sperm count; motility and morphology.

## 1. INTRODUCTION

*Elaeis guineensis* (palm oil) originated from West Africa and derived from mesocarp of the oil palm. It is widely used as cooking oil, basis of soap products (Unilever), American palm olive brand and industrial lubricant for machinery during Britain industrial revolution [1]. Palm oil is a perennial, evergreen tree adapted to cultivation in biodiversity rich equatorial land areas [2] and it is classified to be the most productive oil crop alone capable of fulfilling large growing world demand estimated to about 240 million tons by 2050 [3,4]. Palm oil is known to be the richest natural plant source of carotenoids in term of provitamin A (retinol) equivalents such as  $\alpha$ -carotene and  $\beta$ -carotene [5]. Red palm oil (RPO) exerts effects on reproductive capacity by improving the efficiency of protein utilization or biosynthesis in order to boost and improve sex hormone function. Red palm oil provides vitamin A which is a major factor in reproduction through the synthesis of sexual steroids, embryogenesis and spermatogenesis ([6], Chandrasekharan et al., 2004). *Elaeis guineensis* has been reported to have protective antioxidant properties and carotenoids present in it have protective effects in cellular ageing, atherosclerosis, cancer, arthritis and Alzheimer's diseases (Nagendran et al., 2005). Presently, according to WHO Health Organization (WHO) approximately 80% of the World's population depends on indigenous or traditional medicine for their primary health needs (Panti et al., 2011)[7]. Red palm oil is distinctive from other plant and animal oil because it contain 50% saturated fatty acids, 40% unsaturated fatty acids and 10% polysaturated fatty acids [8].

Dichlorvos (2, 2-dichlorovinyl dimethyl phosphate) is an organophosphate insecticides

cum pesticides widely use to control household pests in developing countries [9]. It is traded under the names such as Dedeva, DDVP, Nogos, Nuvan, Sniper and Dasksh [10]. It was classified as 1B highly hazardous chemical [11]. The compound has been under controversial because of its prevalence in urban water ways and toxicity extends beyond insects [12,13]. DDVP is effective against amphids, mites, caterpillars, white flies, thrips and also for the treatment of parasitic worms infection in humans and animals. The major use of dichlorvos is for space treatment of food poisoning, handling and storage of plant, corral, holden pens, poultry houses, feed lots, commercial and institutional building [14]. The exposure of Dichlorvos has an effect on human health such as genotoxic, oncogenic, neurotoxic and reproductive effects [15]. However, the study on effects of DDVP on fertility of male rat via intra-peritoneal injection has significant decrease in sperm numbers and increase in sperm abnormalities [16]. Further study reported significant reduction in testosterone levels, distortion in the cells of seminiferous levels and hypertrophy of spermatogenic cell levels of adult rats fed with water contaminated with dichlorvos [17]. This study was designed specifically to attenuate/reduce/minimize the effects of Dichlorvos (DDVP) induced testicular toxicity and sperm parameters using red palm oil.

## 2. MATERIALS AND METHODS

### 2.1 Materials

Red palm oil, DDVP, Formal saline, Distilled water, Oral cannula, Needle and Syringe, Manual weighing machine, Sample bottles, Dissecting set, Gloves, Microscope, Feeding and drinking

trough, Glass slide, Normal saline, Bouin's fluid, Alcohol, Hematoxylin, Chloroform, and Slab.

## 2.2 Animals and Materials

Eighteen (18) adult albino rats of average body weight between 125g and 250g were bought from Animal house section of Physiology Department Ladoke Akintola University of Technology, Ogbomoso, Oyo State, Nigeria. The animals were housed in clean polypropylene cages and maintained in animal house at constant 12h/12h dark and light cycle with strict adherence to the ethical procedure. The animals were acclimatized for 2 weeks (14 days). Red palm oil (RPO) with viscosity that can pass through oral cannula purchased from Oja Oosa Market Apomu, Osun State, Nigeria. Analytical grade Dichlorvos (DDVP) chemical was purchased from Agro ally store Ogbomoso, Oyo State Nigeria. Concentration of 1ml of DDVP was diluted in 1000mls of distilled water and kept in a bottle for 3 days.

## 2.3 Experimental Protocol

The rats were divided into three groups (n=6), labeled as group A, B, C and D. Group A represent Control and were given water only, Group B were orally administered with 2 ml of red palm oil, Group C orally received 1 ml/100 g of DDVP and Group D orally received 2 ml of red palm oil plus 1 ml/100 g of DDVP as shown in Table 1. Feed and water were made available. The oral administration lasted for 2 weeks (14days) with oral cannula. Twenty four hours (24hrs) after the last treatment, the animals were sacrificed by cervical dislocation after which the testis.

Were remove into formal saline filled sample bottles and the epididymis were mince in pre-warmed normal saline (37<sup>o</sup>C) for sperm assessment. The sperm counts were analyzed using microscope.

## 2.4 Semen Analysis

The sperm count was evaluated /examined using new improved Neubauer's hemocytometer (Deep 1/10 mm, LABART, Germany). The procedure reported by Jegede et al. [18] was adopted for the evaluation of sperm motility and sperm morphology. The sperm morphology grading is done using 2 drops of Wall and Ellas stain and air dried with the aid of microscope to view the shape and structure of spermatozoa in order to

distinguish if there are any defects. Four grading were examined, which are morphology grading, head defect, middle- piece defect and tail defect.

## 2.5 Testicular Analysis

The method describe by Akpantal, (2000) was adopted in which the organ were cut in a slab of about 0.5cm thick transversely and fixed in Bouin's fluid for a day after which it was transferred to 70% alcohol for dehydration. The tissues were passed through 90% alcohol and chloroform for different durations before been transferred into moisten paraffin wax for 20minutes each in an oven at 57<sup>o</sup>C. Serial sections were cut at 5microns and the slides were prepared from the tissues. The slides were dewaxed and passed absolute alcohol (2 changes), 70% alcohol and then to water for 5minutes and the slides were then stained with hematoxylin.

## 2.6 Data Analysis

Data obtained were analyzed using Microsoft Excel and results were expressed as mean +- standard deviation.

## 3. RESULTS AND DISCUSSION

### 3.1 Results

#### 3.1.1 Physical appearance

No clinical signs indicative of systemic toxicity were observed in any animal during the study. The untreated rats appeared to be stronger, agile, well-fed and much better than the treated group which appeared slightly skinny, haggard, and aggressive. These changes are as a result of RPO and DDVP administered into the body of the rats. The results recorded for sperm count, sperm motility, morphology and testis histological analysis were presented below using each respective figure.

### 3.2 Discussion

#### 3.2.1 Evaluation of sperm count

Sperm count analysis of the rats from all the groups were summarized in Fig. 1. The results obtained for sperm count showed that DDVP administration significantly reduced sperm count (p<0.05). There was no significant difference in the value obtained for RPO (Group B) induced rats in sperm count when compared with the

value of the control (Group A). However, the group administered with RPO + DDVP (Group C) indicates significant increase in sperm counts.

### 3.2.2 Evaluation of sperm motility and morphology

The sperm motility and morphological analyses showed significant changes in all motion parameters of rats as shown in Fig. 1. The study showed that DDVP administration significantly reduced both sperm motility and sperm morphology ( $p < 0.05$ ). There is significant decrease in the values recorded for RPO (Group B) as well as RPO + DDVP (Group C) administration when compared with the control (Group A). The seminal fluid assessments (sperm motility and sperm morphology) were significantly decreased in the treated groups (B, C, and D) compared with Group A. Similar observations were recorded in the work of Jegede et al. [19]. This study shows that the use of DDVP toxicity may cause oligospermia if administered in large volume for a long period of time. However, the motility and morphological values recorded for RPO administration is significantly higher compared to the values recorded for DDVP only and co-administered with RPO + DDVP. This agrees with previous report that palm oil is a potential supplement to increase fertility [20].

### 3.2.3 Histological analysis of the testis

In the present study, results indicates significant decline in sperm count, sperm motility and sperm morphology of the rats exposed to DDVP. Slightly increase in sperm count of the rat exposed to co-administered with RPO + DDVP but there is no significant difference in sperm count of the rats exposed to RPO. Cross section of histological analysis of the testis were presented in Fig. 2 for Group A, Fig. 3 for Group B, Fig. 4 for Group C and Fig. 5 for Group D respectively.

**Group A:** shows normal seminiferous tubules, spermatogenic cells and interstitial cells as

shown in Fig. 2. According to the result of the analysis normal animal possess normal seminiferous tubules, spermatogenic cells and interstitial cells. It is evident that Group A was not administered with any of the substances and this serves as the control.

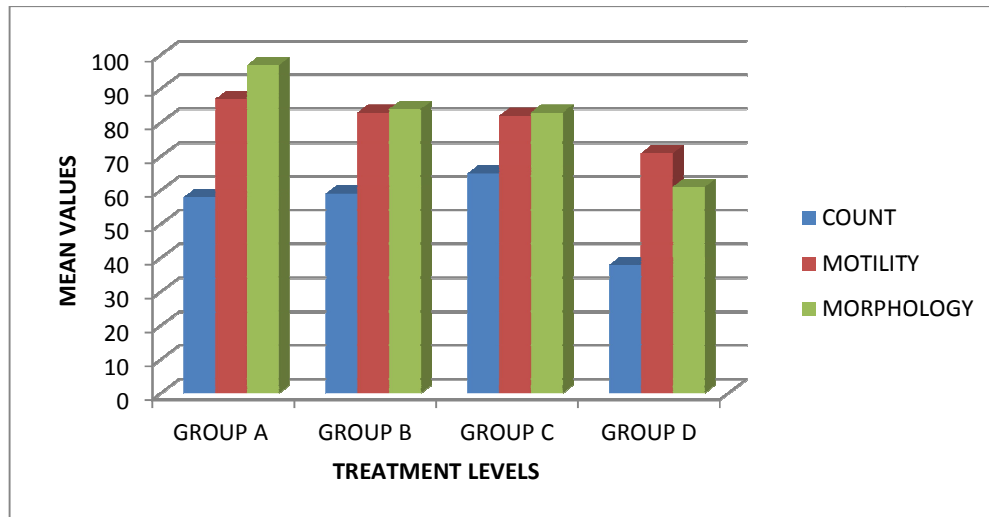
**Group B:** shows increase and well-formed seminiferous tubules with increase spermatogenic cells, Fig. 3. RPO (*Elaeis guinnensis*) is known to be the richest natural plant source of carotenoids in terms of provitamin A equivalent [21]. Vitamin A is known to play a part in reproduction through synthesis of sexual steroids. Aboua et al. [22] reported that the intake of palm oil promote the male sperm functions thus promoting spermatogenesis and embryogenesis.

**Group C** shows an improving spermatogenic cells and normal seminiferous tubules, Fig. 4. From the analysis disruption of seminiferous tubules in testis and reduction in sperm were able to come back to normal as a result of the presence of RPO induced. This is evident that palm oil contains antioxidants that act against free radicals caused by pollutant and pesticide reported by Nagendran et al. [23].

**Group D** shows laminar vacuolation, cellular degeneration and disruptions of seminiferous tubules, Fig. 5. The disruptions are due to the effects of 2, 2- dichlorovinyl dimethyl phosphate (DDVP) as one of the toxic substances causing damage on testis during spermatogenesis and resulted to testicular damage. Dichlorvos has been described by various studies as one of the toxic substances that cause damages on testis during spermatogenesis. According to Amara et al. [24] Dichlorvos toxicity on testis causes circulatory failure due to vascular damage and decreased utilization of electrolyte by spermatogenic cells due to its competitive action on the testis. This may further weaken fertility, suppress libido and deteriorate semen quality and testicular degeneration in animals.

**Table 1. Grouping and treatment of the animals**

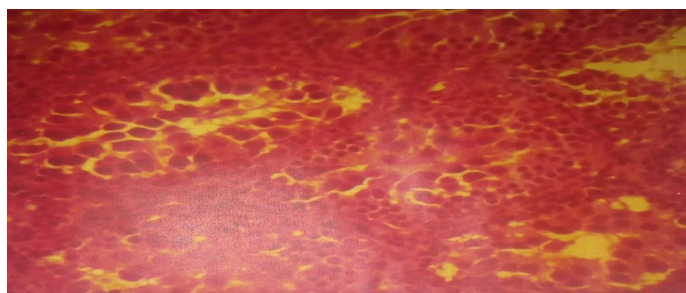
Grouping	Number of Rats	RPO	diluted DDVP	Ordinary Water
Group A	6	-	-	+
Group B	6	+	-	-
Group C	6	+	+	-
Group D	6	-	+	-




**Fig. 1. Graph of mean values for sperm parameters**



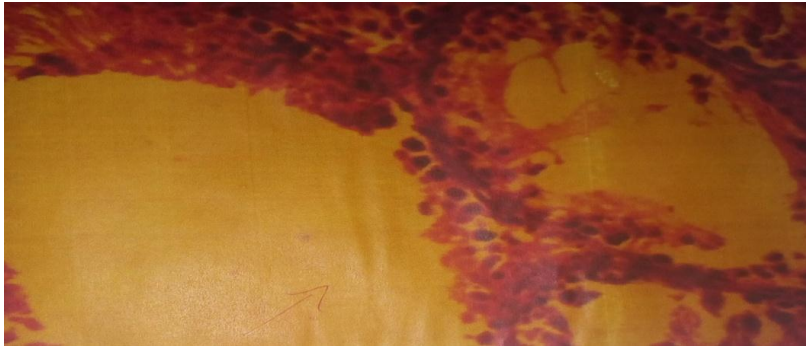
**Fig. 2. Cross section of testicular histology analysis of Group A rat**



**Fig. 3. Cross section of testicular histology analysis of Group B rat**



**Fig. 4. Cross section of testicular histology analysis of Group C rat**



**Fig. 5. Cross section of testicular histology analysis of Group D rat**

#### 4. CONCLUSION

In conclusion, the results showed that RPO recorded better results over DDVP. There is no significant difference in the value obtained for RPO induced rats in sperm count when compared with the value of the control. RPO histological analysis shows increase and well-formed seminiferous tubules with increase spermatogenic cells. However, the motility and morphological values recorded for RPO administration is significantly higher compared to the values recorded for DDVP. Therefore, RPO offers positive protection against DDVP induced testicular damages. This study establishes that RPO exhibit no adverse effect on sperm parameters and could afford a protection against DDVP induced testicular toxicity.

#### CONSENT

It is not applicable.

#### ETHICAL APPROVAL

It is not applicable.

#### COMPETING INTERESTS

Authors have declared that no competing interests exist.

#### REFERENCES

1. Obahiaghon. Review of the African oil and implications of its bioactive in human health; American Journal of Biochemistry and Molecular Biology; 2012.
2. Corley RHV, Tinker PBH. Assessment of growth, carbon stock and sequestration potential of oil palm plantations in Mzoram, Northeast India. Journal of environmental protection. 2018;9(9).
3. Corley RHV. How much palm oil do we need? Environ. Sci. Policy. 2009;12:134–139. DOI: 10.1016/j.envsci.2008.10.011
4. Tiemen Rhebergen, Shamie Zingore, Ken E Giller, Charles Adu Frimpong, Kwame Acheampant, Francis Ohipeni, Edward Kofi Payin. Closing yeild gap in oil palm production system in Ghana through best management practices: European Journal of Agronomy, 2020;115:126011.
5. Poku K. Small-scale palm oil processing in Africa. FAO agricultural services bulletin N°148, FAO, Roma; 2002.
6. Machini A, Imperlin E, Nigro E, Montagnese C, Daniele A, Orru S, Buono P. Biological and nutritional properties of Palm oil and palmitic acid: Effects on health, Molecules. 2015;20(9):17339–17361
7. Pantsi W, Marnewick J, Esterhuysen A, Rautenbach F, Van Rooyen J. Rooibos (*Aspalathus linearis*) offers cardiac protection against ischaemia/reperfusion in the isolated perfused rat heart. Phytomedicine. 2011;18(14):1220–1228.
8. Atawodi SE, Yusufu L, Atawodi JC, Asuku O, Yakubu OE. Phenolic compounds and antioxidant potential of Nigerian red palm oil (*Elaeis guineensis*) Int J Biol. 2011;3(2):153–161.
9. USEPA. United States Environmental Protection Agency. Dichlorvos TEACH Chemical summary U.S EPA. Toxicity and exposure assessment for children. 2007;1–13.
10. Owoeye O, Edem FV, Akinyoola BS, Rahaman S, Akang EE, Arinola GO.

- Toxicological changes in liver and lungs of rats exposed to dichlorvos before and after vitamin supplementation. *Eur. J Anat.* 2012;16(3):190–8.
11. WHO (1994–1995). World Health Organization. International Programme on chemical safety. UNEP/ILO/WHO. Recommended classification of pesticide by hazards and guidelines to classification; 1992.
  12. Das S. A review of Dichlorvos toxicity in fish". *Current World Environment Journal.* 2013;8(1).
  13. Wines M. Pesticide levels in waterways have dropped, reducing the risks to humans. *The New York Times*; 2014.
  14. Hensaw Uchech, Okorowu Iwara, Arikpo Iwara. Dichlorvos toxicity: A public health perspective. *Interdisciplinary Toxicology.* 2018;12(2):129-132.
  15. Booth ED, Jones E, Elliott BM. Review of the in vitro and in vivo genotoxicity of dichlorvos". *Regulatory Toxicology and Pharmacology.* 2007;49 (3): 316-26.
  16. Faris SK. Effects of dichlorvos pesticide on fertility of laboratory male mice (*Mus musculus* L.) *Bas J Vet Res.* 2008;7(1):9–18.
  17. Ezeji EU, Ogueri OD, Udebuani AC, Okereke JN, Kalu OO. Effects of Dichlorvos on the fertility of adult male albino rats. *Nature and Science.* 2015;13(12):1–5.
  18. Jegede AI, Ajadi MB, Akinloye O. Modulatory effects of Kolaviron (Garcina kola extract) on spermogram and reproductive system of adult male Wistar rats in lead acetate induced toxicity," *Journal of Toxicology and Environmental Health Sciences.* 2013;5(7):121–130.
  19. Jegede AI, Offor U, Azu OO, Akinloye O. Red palm oil attenuates lead acetate induced testicular damage in adult male sprague-dawley rats. *evidence-based complementary and Alternative Medicine.* 2015;7. Article ID 13026.
  20. Nicholson DW. From bench to clinic with apoptosis-based therapeutic agents, *Nature.* 2000;407(6805):810–816.
  21. Sundram K, Sambanthamurthi R, Tan YA. Palm fruit chemistry and nutrition, *Asia Pacific Journal of Clinical Nutrition.* 2003;12(3):355–362.
  22. Aboua YG, Brooks N, Mahfouz RZ, Agarwal A, Du Plessis SS. A red palm oil diet can reduce the effects of oxidative stress on rat spermatozoa. *Andrologia.* 2012;44:32- 40.
  23. Nangendran Balasundran, Tan Yew Ali, Ravigadevi Samban Thamuthi, Kalyana Sundran, Samir Samman. Antioxidant properties of palm fruit: *Asia Pacific Journal of clinical nutrition.* 2005;14(4):319-24.
  24. Amaral S, Oliveira PJ, Ramalho-Santos J. Diabetes and the impairment of reproductive function: Possible role of mitochondria and reactive oxygen species. *Curr Diabetes Rev.* 2008;4(1):46-54.

© 2021 Lawal et al.; This is an Open Access article distributed under the terms of the Creative Commons Attribution License (<http://creativecommons.org/licenses/by/4.0>), which permits unrestricted use, distribution, and reproduction in any medium, provided the original work is properly cited.

*Peer-review history:*

*The peer review history for this paper can be accessed here:*  
<http://www.sdiarticle4.com/review-history/64667>