



## Visceral Leishmaniasis: An Unusual Cause of Bone Marrow Failure in Jos, Nigeria-A Case Report and Review of Literature

Jatau Ezra Danjuma <sup>a\*</sup>, Ayuba Zakari <sup>a</sup>, Dahal Abednego Samuel <sup>b</sup>,  
Okeke Chinedu Nnawike <sup>c</sup>, Adeyemi Ayobola Olusegun <sup>a</sup>, Boli Elias Wada <sup>a</sup>,  
Bangalu Dauda Yohanna <sup>a</sup>, Ma'an Victoria Tapsuk <sup>b</sup>,  
Damulak Obadiah Dapus <sup>a</sup> and Egesie Ochaka Julie <sup>a</sup>

<sup>a</sup> Department of Haematology and Blood Transfusion, Jos University Teaching Hospital, Nigeria.

<sup>b</sup> Department of Medical Microbiology, Jos University Teaching Hospital, Nigeria.

<sup>c</sup> Department of Haematology and Blood Transfusion, Bingham University Teaching Hospital, Nigeria.

### **Authors' contributions**

*This work was carried out in collaboration among all authors. All authors read and approved the final manuscript.*

### **Article Information**

#### **Open Peer Review History:**

This journal follows the Advanced Open Peer Review policy. Identity of the Reviewers, Editor(s) and additional Reviewers, peer review comments, different versions of the manuscript, comments of the editors, etc are available here: <https://www.sdiarticle5.com/review-history/93970>

**Case Study**

**Received 07 September 2022**  
**Accepted 20 November 2022**  
**Published 23 November 2022**

### **ABSTRACT**

Visceral leishmaniasis is an uncommon parasitic disease in our environment. It can present with features of bone marrow failure characterized by anaemia, leucopenia, and thrombocytopenia which can be fatal if untreated.

We present the case of a 23-year-old male, a foreign undergraduate student in a Cyprus University who presented with a 10 months history of recurrent fever, easy fatigability and abdominal enlargement. History, physical examination and investigations carried out including a bone marrow aspiration cytology led to a diagnosis of visceral leishmaniasis.

He was successfully managed using amphotericin B infusion and packed red blood cells transfusion.

Leishmaniasis and other common tropical diseases have overlapping symptoms and signs but with a high index of suspicion and prompt specialist intervention, fatal complications can be averted.

**Keywords:** *Visceral; leishmaniasis; tropical disease; bone marrow failure; treatment.*

## 1. INTRODUCTION

Leishmania is a widely distributed haemoflagellate usually transmitted through the infective bite of female phlebotomine sand fly though it can also be transmitted through blood transfusion, congenital route and sharing of a needle by intravenous drug abusers [1]. Rodents such as mice, rats and animals like dogs, Foxes, Jackals and Wolves could serve as natural reservoirs [2]. These protozoan flagellates are known to cause visceral and cutaneous leishmaniasis which is said to be second to malaria as the most common parasitic cause of mortality Worldwide. Visceral leishmaniasis are caused by the species *L. donovani* and *L. infantum* [3]. It has been reported to be prevalent in 98 Countries Worldwide with an estimated annual new case of between 700,000 to 1.2 million and additional 350 million individuals at risk of being infected with fatalities if left untreated [4]. Bangladesh, Brazil, India, South East Asia, Middle East, Mediterranean area, and Sudan account for 90% of all cases with the majority of adults infected having associated human immunodeficiency virus disease [5]. Data from some West African Countries to the World Health Organization (WHO) between 2005 to 2017 indicated that 60 cases of visceral leishmaniasis were reported and 57 of these cases occurred in Nigeria in 2012 [6]. Visceral leishmaniasis could present to the haematologist as hepatomegaly, lymphadenopathy, splenomegaly with resultant hypersplenism and consequent pancytopenia and its attendant complications. Haematological abnormalities associated with visceral leishmaniasis include normocytic normochromic anaemia, leucopenia with high lymphocyte and monocyte counts, neutropenia, thrombocytopenia and high erythrocyte sedimentation rate. Diagnosis of Leishmaniasis is based on detecting the amastigotes referred to as Leishman-Donovan bodies from bone marrow, spleen, lymph nodes or skin lesion smear stained with Leishman or Giemsa stain [7]. An enzyme immunosorbent assay (ELISA) technique using a 70-kDa antigen has been used as a rapid and accurate field-applied tool to detect visceral leishmaniasis. Polymerase chain reaction (PCR), especially when combined with Southern immunoblotting gives more sensitive and specific result while direct antihuman globulin test may give an inconclusive finding in immunocompromised individuals [8].

There is little or no information on visceral leishmaniasis as a cause of bone marrow failure

in our environment and hence we share this case report with a review of some literature to address this knowledge gap through further studies and research. It is also aimed at creating reasonable awareness of this disease and its fatal haematologic complication of pancytopenia if not diagnosed and promptly managed.

## 2. CASE REPORT

BC is a 23-year-old, male. He first presented at a private facility on the 15th of November, 2017 with a 10 months history of recurrent fever, easy fatigability and abdominal swelling. He was empirically treated for malaria and typhoid fever on several occasions with little or no improvement until a progressively declining packed cell volume (PCV) was noticed thereby necessitating referral to the haematologist eight months later. A review by the haematologist confirmed the history of fever, easy fatigability and abdominal swelling with associated loss of weight. No history of jaundice, bone pain or bleeding from any orifice and no swellings were noticed in other parts of the body. A general systemic review did not reveal any significant finding. The patient was treated on several occasions with artemisinin combination therapy for malaria, analgesics (ibuprofen) and had several doses of antibiotics that include amoxicillin-clavulanic acid formulation as a treatment for suspected typhoid fever at some private hospitals. No previous history of blood transfusion since the onset of the illness but was placed on haematinics (Folic acid and iron tablets) with no significant improvement. The patient is single, an undergraduate student at a University in Cyprus but dropped out due to involvement in drug abuse about a year prior to the presentation. He occasionally drinks alcohol but smokes at least five (5) sticks of cigarettes daily along with marijuana. He is the last of 6 children with no known family history of similar illness.

On examination at presentation, the patient was not in obvious distress, chronically ill-looking, febrile with a temperature of 37.9°C, moderately pale, acyanosed, anicteric with no significant peripheral lymphadenopathy and no pedal oedema.

The significant finding on systems examination was a blood pressure of 96/60 mmHg, pulse rate of 110 beats per minutes, an enlarged liver of about 10 centimetres below the right costal margin, smooth and tender with spleen

enlargement of 12 centimetres below the left costal margin.

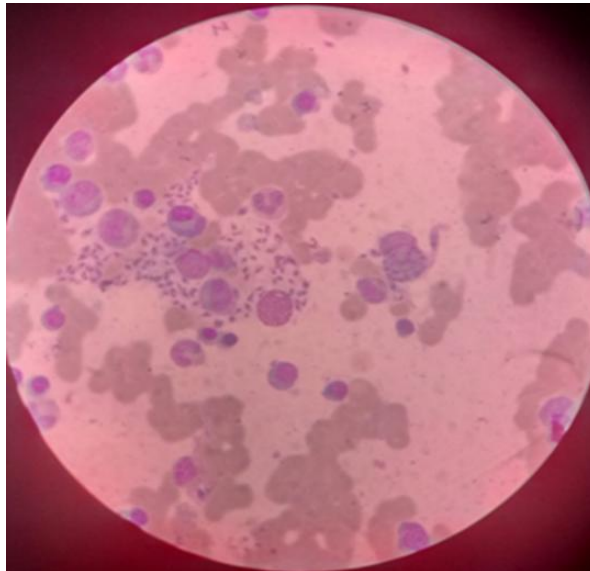
Blood samples were aseptically collected for full blood count (FBC), reticulocyte count, and blood grouping. Bone marrow aspiration cytology, hepatitis B and C viral (HBsAg, HCV) screenings,

retroviral screening (RVS), renal and liver function tests, and stool microscopy were carried out. A request for an Abdominal ultrasound scan was also made.

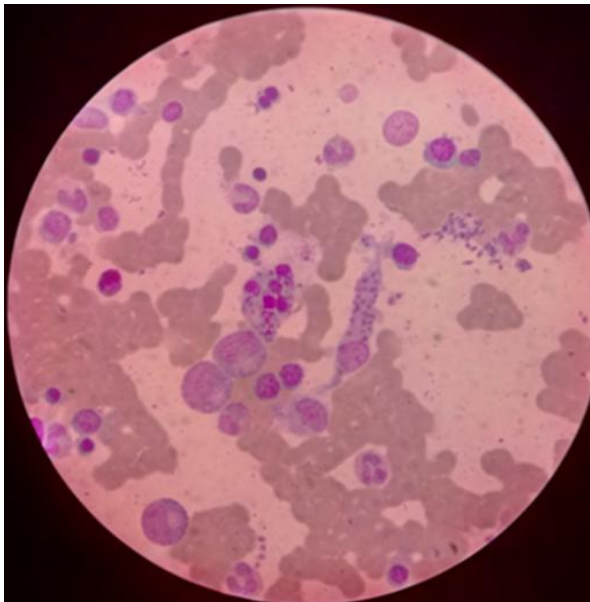
The results of the Investigations done is presented in the table below.

**Table 1. Investigations and findings at diagnosis**

<b>Investigation</b>	<b>Result/Remarks</b>
<b>FBC</b>	
Haematocrit (Hct)	0.21
Haemoglobin Concentration (Hb)	7.1g/dl
Total White Blood Cell (WBC) Count	1.6 x 10 <sup>9</sup> /L
Neutrophils	0.61 x 10 <sup>9</sup> /L
Lymphocytes	0.93 x 10 <sup>9</sup> /L
Monocytes	0.02 x 10 <sup>9</sup> /L
Eosinophils	0.01 x 10 <sup>9</sup> /L
Basophils	0.01 x 10 <sup>9</sup> /L
Platelet Count	129 x 10 <sup>9</sup> /L
Mean Corpuscular Volume (MCV)	69.7 fl
Mean Corpuscular Haemoglobin (MCH)	24.1g/dl
Mean Corpuscular Haemoglobin Conc. (MCHC)	34.6g/dl
Red Cell Distribution Width (RDW)	19.5%
Reticulocyte Count	0.3%
Blood grouping	B positive
<b>Electrolyte, Urea and Creatinine (EUC)</b>	
Sodium (Na <sup>+</sup> )	141 mmol/L
Potassium (k <sup>+</sup> )	4.1 mmol/L
Chloride (Cl <sup>-</sup> )	104 mmol/L
Urea	4.3 mmol/L
Creatinine	100 mmol/L
<b>Liver Function Test (LFT)</b>	
Total protein	75 g/L
Albumin	35 g/L
Bilirubin (Total)	14.2 µmol/L
Bilirubin (Conjugated)	5.3 µmol/L
Alkaline Phosphatase	56 IU/L
Alanine transaminase	24 IU/L
Aspartate transaminase	16 IU/L
<b>Malaria Parasite-MP (Thick/Thin) film</b>	No MP seen
<b>Stool Microcopy</b>	No parasite seen
<b>HBsAg/HCV/RVS</b>	Non-Reactive
<b>Abdominal Ultra Sound Scan (USS)</b>	Liver enlargement (21.1cm) with normal echo pattern, Spleen enlargement (19.4cm), Normal kidneys, Nil ascites or lymphadenopathy
<b>Bone Marrow Aspiration (BMA) Cytology</b>	Hypocellular bone marrow having a depressed erythropoiesis with few megaloblast, depressed myelopoiesis and lymphopoiesis but normal megakaryopoiesis. Numerous intra-mononuclear and extra cellular amastigotes (Fig. 1A & 1B)



**Fig. 1A. Bone marrow cytology film at diagnosis showing numerous intra-mononuclear and extracellular amastigotes (X100)**



**Fig. 1B. Bone marrow cytology films at diagnosis showing numerous intra-mononuclear and extracellular amastigotes (X100)**

Based on our laboratory findings a diagnosis of visceral leishmaniasis with bone marrow failure was established and supportive management was instituted. Given already established anaemia with symptoms which was non-responsive to administered haematinics, the patient was transfused three (3) units of packed red blood cells. He was also commenced on intravenous ceftriaxone 1 gram, 12 hourly for 72 hours while a prescription for liposomal

amphotericin B was made. Conventional amphotericin B in a dose of 1 milligram per kilogram body weight daily, in slow infusion for 20 days was eventually utilized due to the non-availability of the liposomal formulation. Fever subsided to 36.9°C on the second day of commencement of treatment and by the fourth week, hepatosplenomegaly had regressed and the patient had the following haemogram.

**Table 2. Post treatment haemogram**

Investigation	Result
<b>FBC</b>	
Haematocrit (Hct)	0.36
Haemoglobin Concentration (Hb)	11.9 g/dl
Total White Blood Cell (WBC) Count	$3.8 \times 10^9/L$
Neutrophils	$1.71 \times 10^9/L$
Lymphocytes	$1.86 \times 10^9/L$
Monocytes	$0.02 \times 10^9/L$
Eosinophils	$0.01 \times 10^9/L$
Basophils	$0.0 \times 10^9/L$
Platelet Count	$256 \times 10^9/L$
Mean Corpuscular Volume (MCV)	84.5 fl
Mean Corpuscular Haemoglobin (MCH)	30.8 g/dl
Mean Corpuscular Haemoglobin Conc. (MCHC)	35.0 g/dl
Red Cell Distribution Width (RDW)	19.5 %
Reticulocyte Count	1.9 %

### 3. DISCUSSION

Leishmaniasis is one of the neglected tropical diseases (NTD) predominantly common as cutaneous leishmaniasis in the northern parts and middle belt regions of Nigeria. Visceral leishmaniasis is an uncommon parasitic disease in our environment compared to the cutaneous and mucocutaneous forms of the disease [9]. However, with increased globalization in search of better means of livelihood and education, certain diseases have been globalized. This intracellular protozoan disease is widely spread with a disease burden estimated at 1.5-2 million new cases per annum. Visceral leishmaniasis is the most severe form of the disease involving major organs like the liver, spleen and bone marrow with fatal consequences if left untreated. It accounts for up to 500 000 cases of the disease while the mucocutaneous form accounts for about 1.5 million cases [10]. It presents with severe symptoms of fever, hepatosplenomegaly and or lymphadenopathy, loss of weight, anaemia, leucopenia and occasionally thrombocytopenia with or without bleeding. The index patient presented with these classical features but because of the similarity of clinical features with some common tropical diseases like malaria, he was on treatment for malaria and enteric fever for several months until he developed symptomatic anaemia.

There are very limited reports on visceral leishmaniasis in this environment, but worthy of note is the fact that the index patient was a foreign student in Cyprus a country within the middle east and Mediterranean region endemic

for the disease [11]. Leishmaniasis in humans is caused by about twenty leishmania species that are morphologically similar and only differentiated by laboratory analysis. Visceral leishmaniasis in India, South East Asia and West Africa are commonly caused by *L. donovani* while *L. infantum* is the commonest agent in the Middle East and the Mediterranean region [12]. We were not able to characterize the leishmania specie in our patient to identify the specie he was infected with having lived as a student in a Middle Eastern country. Kazeem et al. [13], reported a rare case of leishmaniasis presenting with severe anaemia in an adult female in Ile-Ife, Nigeria which is comparable to the current case though this is in an adult male who are twice more susceptible to contracting the infection. A recent report from Gboko in Benue State of North Central Nigeria showed a visceral leishmaniasis rate of 13% with a male-female prevalence rates of 12.5% and 13.5% in contrast to the known male-female ratio [14]. Children, young adults like the index patient as well as immunocompromised individuals are also highly susceptible to this infection. Leishmania and Human Immunodeficiency Virus (HIV) co-infection has become a major cause of morbidity and mortality among patients with leishmaniasis warranting its recognition as an acquired immunodeficiency syndrome (AIDS) defining illness. Furthermore, migration from the rural areas to the urban areas commonly experienced in Africa and the increase incidence of HIV infection among rural dwellers has further multiplied the rate of this co-infection now considered a global emerging disease [15]. A Report has shown that 70% of adults with visceral leishmaniasis in Africa, especially in

Sudan and Ethiopia, have associated HIV infection further compounding the immunosuppressive tendency associated with the disease [16]. This therefore calls for a programmed routine screening for visceral leishmaniasis in patients diagnosed with HIV in our environment. Viral screenings for HIV, hepatitis B and C carried out in our patient were negative and this might have contributed to the positive treatment outcome seen in the patient. Treatment of leishmaniasis is dependent on the clinical presentation of the disease, guided by the availability and effectiveness of the therapeutic agent. Pentavalent antimony was the mainstay of treatment for leishmaniasis but its multiple toxicities and parasite resistance has rendered it ineffective [17]. Other therapeutic agents use in the treatment of this disorder are Paromomycin an aminoglycoside antibiotic, Pentamidine and Amphotericin B, the agent used in managing the index patient [18]. Successfully managed patients with visceral leishmaniasis sometimes develop a fulminant, progressive proliferation of parasites within the skin with characteristic diffuse macular, maculopapular or nodular lesions referred to as post-kala-azar dermal leishmaniasis (PKDL) [19]. Our patient has so far remained free from any post-treatment complications in the class of PKDL.

#### 4. CONCLUSION

Visceral Leishmaniasis is a global public health problem further complicated by its ability to invade the reticuloendothelial system with resultant bone marrow failure and immunosuppression. A high index of suspicion given its shared symptoms and signs with other tropical diseases is necessary for the successful management of this highly underestimated and understudied disease.

#### 5. RECOMMENDATION

We recommend a multidisciplinary training of health personnels, development of laboratories and field diagnosis skills as well as robust vector and reservoir control mechanisms while also focusing on screenings for travelers from endemic areas.

#### CONSENT

As per international standard or university standard, patient(s) written consent has been collected and preserved by the author(s).

#### ETHICAL APPROVAL

As per international standard or university standard written ethical approval has been collected and preserved by the author(s).

#### ACKNOWLEDGEMENT

The authors wish to thank Rayfield Medical Services and Jos University Teaching Hospital management for making available, a conducive environment for managing patients and research. Special appreciation to all the resident physicians in the department of haematology.

#### COMPETING INTERESTS

Authors have declared that no competing interests exist.

#### REFERENCES

1. Omer BN, Blaise D. Leishmaniasis in Cameroon and Neighbouring countries: An overview of current status and control challenges. *Current Research in Parasitology & Vector-Borne Diseases* 2022;2. Available: <https://doi.org/10.1016/j.crpvbd.2022.100077>.
2. Quinnell RJ, Courtenay O. Transmission, reservoir hosts and control of zoonotic visceral leishmaniasis. *Parasitology*. 2009; 136(14):1915-1934. DOI: 10.1017/S003118200991156
3. Okwor I, Uzonna J.E. The immunology of Leishmania/HIV co-infection. *Immunol Res* 2013;56:163-71. DOI: 10.1007/s12026-013-8389-8
4. World Health Organization: Control of the leishmaniasis: Report of a meeting of the WHO Expert Committee on the Control of Leishmaniases, Geneva, 22-26 March 2010. (WHO technical report series; no. 949) Available: [http://whqlibdoc.who.int/WHO\\_TRS\\_949\\_eng](http://whqlibdoc.who.int/WHO_TRS_949_eng)
5. Ready PD. Epidemiology of visceral leishmaniasis. *J Clinical Epidemiology* 2014;6:147-154. DOI: 10.2147/CLEP.S44267.
6. Kone AK, Niare DS, Piarroux M, Izri A, Marty P, Laurens MB, et al. Visceral Leishmaniasis in West Africa: Clinical characteristics, vectors, and reservoir. *J Parasitol Res*. 2019;9282690:1-8.

- DOI: 10.1155/2019/9282690
7. Karunaweera ND, Ferreira MU. Leishmaniasis: Current challenges and prospects for elimination with special focus on the South Asian region. *Parasitology* 2018;145:425-429. DOI: 10.1017/S0031182018000471
  8. Davies CR, Kaye P, Croft SL, Sundar S. Leishmaniasis: New approaches to disease control. *BMJ*. 2003;326:377-382. DOI: 10.1136/bmj.326.7385.377
  9. Igbe M, Duhlińska D, Agwale S. Epidemiological Survey of Cutaneous Leishmaniasis in Jos East L.G.A. Of Plateau State Nigeria. *Internet J Parasit Dis*. 2008;4(1):1-3. Available: <https://ispub.com/IJPD/4/1/11715>
  10. Wang J, Cui G, Chen H, Zhou X, Gao C, Yang Y. Current epidemiological profile and features of visceral leishmaniasis in People's Republic of China. *Parasites and Vectors*. 2021;5(31):1-11. Available: <https://www.parasitesandvectors.com/content/5/1/31>
  11. Kerküklü NR, Güran M. An overview of Leishmaniasis with a focus on the island of Cyprus. *J Vector Borne Dis*. 2020;57:197-203. Available: <http://www.jvbd.org>
  12. Kimutai A, Ngure PK, Tonui WK, Gicheru MM, Nyamwamu LB. Leishmaniasis in Northern and Western Africa: A review. *Afr J Infect Dis*. 2009;3(1):14-25. Available: [www.africanethnomedicines.net](http://www.africanethnomedicines.net)
  13. Kazeem OD, Oyekunle AA, Salawu L, Adediran IA, Akinola NO, Badmos KB, et al. Leishmaniasis presenting as severe anaemia in an adult female Nigerian. *Afr J Clin Exper Microbiol*. 2005;6(3):253-255. Available: <https://www.ajol.info/journals/ajcem>
  14. Orpin JB, Mzungu I, Usman-Sani H. Visceral leishmaniasis infection in patients from Gboko Health Division, Benue State, Nigeria. *J Appl Life Sci Int*. 2019;20:1-6. DOI: 10.9734/JALSI/2019/v20i130071
  15. Costa, R. K. E. da, Holanda EC, Andrade S. M. de, Nascimento M. do S. V. do, Soares LF, Oliveira E. H. de. Visceral leishmaniasis and human immunodeficiency virus coinfection: epidemiological profile of cases reported in São Luís-Maranhão, Brazil. *Research, Society and Development*, [S. l.]. 2021; 10(4):e2310413317. Available: <http://dx.doi.org/10.33448/rsd-v10i4.13317>.
  16. Desjeux P. The increase in risk factors for leishmaniasis worldwide. *Trans R Soc Trop Med Hyg*. 2001;95:239-243. DOI: 10.1016/s0035-9203(01)90223-8
  17. Sundar S, Agrawal G, Rai M, Makharia MK, Murray HW. Treatment of Indian visceral leishmaniasis with single or daily infusion of low dose liposomal amphotericin B: Randomised trial. *BMJ*. 2001;323:419-422. DOI: 10.1136/bmj.323.7310.419
  18. Guerin PJ, Olliaro P, Sundar S. Visceral leishmaniasis: Current status of control, diagnosis, and treatment, and a proposed research and development agenda. *Lancet Infect Dis*. 2002;2:494-501. DOI: 10.1016/s1473-3099(02)00347-x
  19. McGwire BS, Satoskar AR. Leishmaniasis: clinical syndromes and treatment. *Q J Med* 2014;107:7-14. DOI: 10.1093/qjmed/hct11

© 2022 Jatau et al.; This is an Open Access article distributed under the terms of the Creative Commons Attribution License (<http://creativecommons.org/licenses/by/4.0>), which permits unrestricted use, distribution, and reproduction in any medium, provided the original work is properly cited.

*Peer-review history:*

*The peer review history for this paper can be accessed here:*  
<https://www.sdiarticle5.com/review-history/93970>