



# Comparing the Efficacy of Carvedilol and Celecoxib to Prednisolone in Acetic Acid-Induced Ulcerative Colitis in Male Albino Rats

Norhan Ahmed Abuohashish <sup>a\*</sup>, Sarah Ibrahim <sup>b</sup>  
and Enass Y. Osman <sup>c</sup>

<sup>a</sup> Department of Pharmacology, Faculty of Medicine, Tanta University, Egypt.

<sup>b</sup> Department of Anatomy, Faculty of Medicine, Tanta University, Egypt.

<sup>c</sup> Department of Pharmacology & Toxicology, Faculty of Pharmacy, Tanta University, Egypt.

## **Authors' contributions**

*This work was carried out in collaboration among all authors. Author NAA designed study, performed statistical analysis, wrote the protocol and performed the experimental model and biochemical assays in lab of pharmacology department. Authors SI and EYO wrote the first draft of manuscript. Author SI managed the analyses of the study and histological examination. Author EYO managed the literature searches. All authors read and approved the final manuscript.*

## **Article Information**

DOI: 10.9734/JAMMR/2023/v35i165089

### **Open Peer Review History:**

This journal follows the Advanced Open Peer Review policy. Identity of the Reviewers, Editor(s) and additional Reviewers, peer review comments, different versions of the manuscript, comments of the editors, etc are available here: <https://www.sdiarticle5.com/review-history/101224>

**Original Research Article**

**Received: 05/04/2023**

**Accepted: 09/06/2023**

**Published: 21/06/2023**

## **ABSTRACT**

Ulcerative colitis refers to destruction of mucosal layer of distal colon and rectum. Exact mechanism for pathophysiology is still unclear but inflammation and oxidative stress may play a caustic role. Neutrophil and monocyte infiltration results in free radical generation which damages intestinal mucosa. Many treatments as steroids are used to reduce inflammation but cannot cause remission. Carvedilol is a third-generation nonselective  $\beta$ -blocker which possesses anti-oxidant,

\*Corresponding author: E-mail: [nourhan.abohashesh@med.tanta.edu.eg](mailto:nourhan.abohashesh@med.tanta.edu.eg), [Drnourahmed2015@yahoo.com](mailto:Drnourahmed2015@yahoo.com);

anti-inflammatory properties and can reduce gastric ulceration. Celecoxib is a selective cyclooxygenase -2 (COX-2) inhibitor which decrease risk of gastrointestinal bleeding. The current study was designed to compare the efficacy of carvedilol and celecoxib to prednisolone in acetic acid-induced ulcerative colitis model. A total of 40 adult male albino rats were randomly divided into five groups: Control group: Rats received 2 ml of saline transrectal. Acetic acid (AA) group: Rats were transrectal injected with 2ml acetic acid. Prednisolone +AA group: Rats were pre-treated with prednisolone in a dose 4mg/kg /day. Carvedilol +AA group: Rats were pre-treated with carvedilol in a dose 30 mg/kg/day. Celecoxib +AA group: Rats were pre-treated with celecoxib in a dose 5mg/kg/day. All drugs were given orally for 7 days. At end of experiment, distal colon was removed, one part of specimen was preserved in 10% formalin for histological examination and other part was homogenized for evaluation of tumor necrosis factor alpha (TNF- $\alpha$ ), reduced glutathione (GSH), malondialdehyde (MDA), nitric oxide (NO) and mitogen-activated protein kinase ( p38 MAPK). Data of present study revealed that treatment of rats with carvedilol or celecoxib before induction of colitis significantly reduced levels of TNF- $\alpha$ , MDA, NO and mRNA level of p38 MAPK while both drugs increased GSH level. Protective effects of Carvedilol and celecoxib are due to anti-inflammatory, anti-oxidant effects and ability to decrease synthesis of MAPK which reduce cytokines signaling in epithelial cells of gut mucosa.

**Keywords:** *Ulcerative colitis; celecoxib; carvedilol; anti-inflammatory; oxidative stress; P38 MAPK.*

## 1. INTRODUCTION

“Ulcerative colitis (UC) is an inflammatory bowel disorder characterized by damage to mucosal layer of distal part of colon and rectum” [1,2]. The disease leads to disturbance in homeostasis in the digestive tract and intestinal inflammation [3]. Symptoms include diarrhea, abdominal cramps and recurrent blood in the stools due to mucosal ulcers [4]. The exact cause of UC is still unknown, but many factors may contribute to its pathogenesis, including genetic susceptibility, environmental factors and imbalance between the immune system and the intestinal microbes [5,6]. “Also, oxidative stress and inflammation play a causative role in the pathogenesis of UC because neutrophils and monocytes infiltration results in high amounts of oxygen free radicals that leads to inflammatory and immune responses which damages intestinal epithelial cells and affects mucosal integrity ultimately leading to UC” [7,8]. Prednisolone belongs to steroid drugs which used in treatment of inflammatory bowel disorders, steroidal drugs are used to reduce inflammation and allow bowel healing. Previous studies have shown that steroids can help controlling active UC, but do not maintain remission state and therefore, cannot be used as long-term maintenance therapy to prevent relapse [9]. “Carvedilol is a third-generation nonselective  $\beta$ -blocker that is used as antihypertensive drug and also in treatment of myocardial infarction” [10]. Carvedilol possesses both anti-apoptotic and anti-inflammatory properties [11] with mitochondrial protection ability [12]. It can also

inhibit lipid peroxidation [13]. In addition, it was found to reduce gastric secretion and ulceration owing to its antioxidant activity [14]. Celecoxib is a nonsteroidal anti-inflammatory drug that belongs to selective cyclooxygenase-2 (COX-2) inhibitors. It is associated with decreased risk of gastrointestinal bleeding [15]. COX-2 is expressed in inflamed tissues due to induction by inflammatory mediators [16]. “COX-2 enzyme inhibition decreases the synthesis of prostaglandin E2 (PGE2), prostacyclin (PGI2), thromboxane (TXA2), prostaglandin D2 (PGD2), and prostaglandin F2 (PGF2) which leads to alleviation of pain and inflammation” [16,17]. “Acetic acid–induced ulcerative colitis is a simple model which is similar to human ulcerative colitis. High concentrations of acetic acid cause perforations of the colon. The use of 4% acetic acid through intrarectal administration causes inflammation and ulceration of the colon without perforation” [18]. This study aimed to investigate the potential protective effects of carvedilol and celecoxib compared to prednisolone as standard drug against acetic acid-induced ulcerative colitis.

## 2. MATERIALS AND METHODS

### 2.1 Chemicals

Acetic Acid was purchased from Sigma Company, Cairo, Egypt. Carvedilol was purchased as 25mg tablets from Multi Apex Pharma, Egypt. Each tablet was dissolved in 5ml saline, so 1ml of the solution contained 5mg carvedilol. Celecoxib was purchased as 100mg

capsule from Pfizer, Egypt. Each tablet was dissolved in 5ml saline, so 1ml of solution contained 20mg celecoxib. Prednisolone was purchased as 5mg tablets from Adco, Egypt. Each tablet was dissolved in 5ml saline, so 1ml of the solution contained 1mg prednisolone.

## 2.2 Animals and Grouping

In this study, 40 adult male albino rats of average weight (150-200 grams each), aging 3-4 months were used and maintained under specific clean conditions in the animal house of Faculty of Medicine, Tanta University. The rats were housed in plastic cages with free access to food ad libitum and water. All experimental procedures described in this study comply with the ethical principles and guidelines for care and the use of laboratory animals adopted by the "Research Ethics Committee" Faculty of Medicine, Tanta University (NIH publication NO.8023, revised 1978) to minimize animal suffering. The study had approval code number: 34689/5/21 according to research ethics committee review report in Tanta University. Animals were allocated into different groups.

## 2.3 Induction of UC

All rats were fasted for 24h with free access to water. After light anesthesia with ether, colitis was induced by instillation of 2ml acid acetic solution (3% in normal saline) using a polyethylene tube which was introduced into the anus to a distance of 8 cm. The rats were then maintained in the head-down position for 30 second to prevent leakage of the acetic acid. Induction of UC was done according to the method described by Mousavizadeh et al. [19]. Control group received intracolonic equal volume of normal saline instead of acetic acid with the same procedure.

## 2.4 Experimental Design

Animals were randomly divided into five groups with eight rats in each group as follow;

**Group I (Control):** Rats received Transrectal injection of a single dose of 2ml of physiological saline and kept for the same periods as experimental animals.

**Group II (AA):** Rats were injected with 2ml acid acetic solution transrectal.

**Group III (Prednisolone+AA):** Rats were pre-treated with prednisolone in a dose 4mg/kg /day orally for seven days. [20] Each rat with average

weight 180mg received 0.75ml of prednisolone dissolvent before the induction of UC.

**Group IV (Carvedilol + AA):** Rats were pre-treated with carvedilol in a dose 30 mg/kg/day orally for seven days. [10] Each rat with average weight 180mg received 1ml of carvedilol dissolvent before the induction of UC.

**Group V (Celecoxib+AA):** Rats were pre-treated with celecoxib in a dose 5mg/kg/day orally for seven days [21]. Each rat with average weight 180mg received 0.5ml of celecoxib dissolvent before the induction of UC.

At end of the experiment, all animals were anaesthized with suitable amount of ether and then sacrificed at the optimum time. The distal colon (5-6 cm) was rapidly removed and gently washed from fecal content using normal saline. One part of specimen was preserved in 10% formalin for histological examination. The other part was homogenized and kept at -20°C for evaluation of biological parameters such as TNF- $\alpha$ , reduced glutathione, MDA and Nitric oxide.

## 2.5 Biochemical Assays

All biochemical measurements were performed in pharmacology department, Faculty of medicine, Tanta University.

### 2.5.1 Determination of gastric tissue malondialdehyde (MDA) content (nmol/gm. tissue)

Malondialdehyde was determined according to the colorimetric method of [22]. The principle of the assay is based on interaction between thiobarbituric acid (TBA) and MDA in acidic medium at temperature of 95°C for 30 min to form thiobarbituric acid reactive product and the absorbance of the resultant pink product can be measured at 534 nm. The absorbance of sample (A sample) was measured against blank.

### 2.5.2 Determination of Nitric Oxide (NO) content (nmol/gm. tissue)

Nitric oxide concentrations in colonic tissues were measured by the Griess reaction method [23] using a commercially available kit (R & D Systems, Minneapolis, MN). Results were expressed as nmol/gm. tissue for NO.

### 2.5.3 Determination of tissue tumor necrosis factor alpha (TNF- $\alpha$ ) content (pg. /ml)

TNF- $\alpha$  was assayed using kit obtained from Sun red Biotechnology Company, Shanghai, China,

according to the method of [24]. TNF- $\alpha$  was measured in gastric tissue homogenate. The kit uses a double-antibody sandwich ELISA to assay the level of rat TNF- $\alpha$  in samples. This assay measures the amount of antigen between two layers of antibodies (i.e. capture and detection antibody). The antigen is immobilized, usually in 96-well plates. Then, the antigen binds to a specific antibody, which is subsequently detected by a secondary, enzyme-coupled antibody. A chromogenic substrate for the enzyme yields a visible color change, indicating the presence of antigen. The chroma of color and the concentration of antigen in the sample are positively correlated.

#### 2.5.4 Determination of tissue reduced glutathione (GSH) content (mg/g.tissue)

Reduced glutathione was determined according to the colorimetric method of [25] using kits supplied by Bio diagnostic company, Egypt. The principle of the methods depends on the fact that glutathione (GSH) reduces 5, 5` dithiobis (2- nitro benzoic acid (DTNB) to produce a yellow compound. The reduced chromogen is directly proportional to GSH concentration and its absorbance can be measured at wavelength of 405 nm.

#### 2.5.5 Determination of mRNA levels of p38 MAPK

Examination of MRNA levels of p38 MAPK in rat colon tissues was done using reverse transcription-polymerase chain reaction (RT-PCR). The total RNAs in the colon tissues of rats were extracted by TRizol (Invitro-gen, Carlsbad, CA, USA) lysis assay and reversely transcribed into complementary deoxyribose nucleic acids (cDNAs) according to the instructions of the first-strand cDNA kit (TaKaRa, Otsu, Shinga, Japan). Subsequently, PCR amplification was carried out on a PCR instrument. The sequences of the primers added are shown in Table 1. Reaction system: annealing at 65°C and extension at 72°C for 30 cycles. The reaction product was subjected to gel electrophoresis, and the optical density value was analyzed under a gel instrument [26].

#### 2.6 Histopathological Examination of Colon Tissues

Haematoxylin and Eosin (H&E) stain was done for detection of the general histological structure of rat's colon [27]. Table 2 shows scoring of histopathological results.

**Table 1. Primer sequence for p38 MAPK**

P 38 MAPK	Primer sequence (5' →3')
Sense	F: AGGGCGATGTGACGTTT
Antisense	R:CTGGCAGGGTGAAGTTGG

#### 2.7 Immunohistochemical Detection of cyclooxygenase-2 (COX-2)

Four micron thick tissue was mounted onto poly L-lysine-treated Probe. Slides were deparaffinized and rehydrated. Endogenous peroxidases were degraded by incubating the sections in 0.5% hydrogen peroxide in methanol for 20 minutes. After a 15 minute wash in 0.01 M phosphate-buffered saline (PBSB), pH 7.2, the tissues were microwaved at high power for two sets of 10 minutes each in 0.1 M citrate buffer, pH 6.0. The tissues were rinsed in PBSB for 15 minutes and then incubated in 10% non-immune goat serum at room temperature for 20 minutes. A rabbit polyclonal antibody to COX-2 (PG27B, Oxford Biomedical Research, Oxford, MI) diluted 1: 100 in PBS, was applied, and the sections were incubated overnight at 4 C. After rinsing in PBSB for 15 minutes, the bisotinylated secondary antibody diluted 1: 200 in PBS was applied, and the sections were incubated at room temperature for 45 minutes. After a 15 minute rinse in PBSB, RTU Elite ABC reagent (Vectastain PK-7100, Vector) was applied and incubated at room temperature for 45 minutes. The antibody reaction products were observed with the chromagen 3, 3-diaminobenzidine tetrahydrochloride (DAB, 71-00-08, Kirkegaard and Perry Lab, Gaithersburg, MD) and counterstained briefly with Gill's hematoxylin. Negative control tissues were treated similarly except that normal no immune rabbit serum, used as a nonspecific antibody control, was substituted for the COX-2 antibody [28]. COX-2 immunolabelling was evaluated by a semi-quantitative assessment which included staining grade (percentage of positive cells) and intensity. Five 10X fields from each slide were evaluated. The grade (percentage) was evaluated by the following scoring system: 0 = negative; 1 = < 10% of cells staining positive; 2 = 10–30%; 3 = 31–60%; 4 = > 60%. Intensity was evaluated by the following scoring system: 0 = negative; 1 = weak staining; 2 = moderately intense staining; and 3 = marked intense staining. Intensity of positive control cells was considered marked staining. The final expression score was calculated multiplying the intensity with percentage and classified as weak (1–2), moderate (3–5), marked (6–8) and very marked (> 9).

**Table 2. Scoring of histopathological results**

Score	Inflammation	Goblet cell loss	Glandular hyperplasia	Muscle thickening	Ulceration
0	None	None	None	None	Absent
1	Individual cells	Less than 10%	Slight increase	slight	
2	Mild Infiltrate	10-50%	2-3 folds increase	strong	
3	Large infiltrate	More than 50%	More than 3 folds increase	excessive	Present

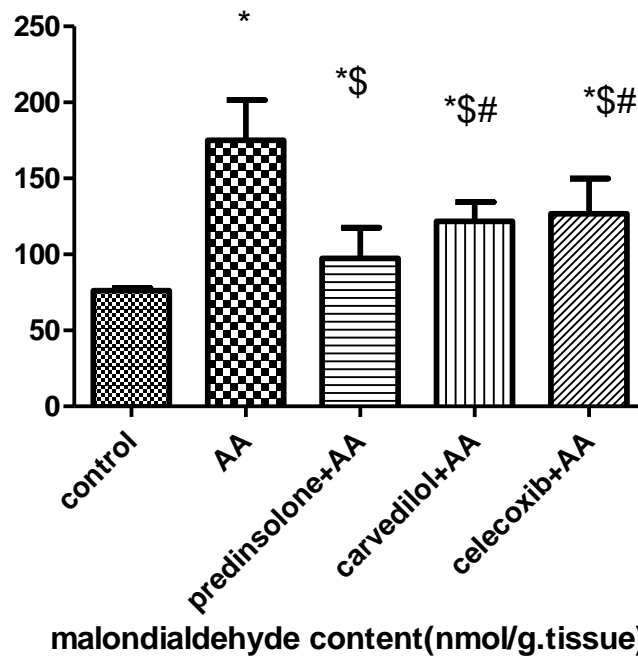
### 2.8 Statistical Analysis

All data assessed were statistically analyzed using SPSS software version 13 (SPSS Inc., Chicago, IL, USA), then compared by one way analysis of variance (ANOVA). The results were expressed as mean±standard deviation (SD). The differences were considered statistically significant if probability value  $P < 0.05$ .

### 3. RESULTS

As presented in Fig. 1, induction of ulcerative colitis in rats resulted in significant increase (129%) in MDA tissue contents compared to control group. On the other hand, pretreatment with prednisolone significantly decreased (42.6%) tissue MDA contents compared to acetic acid group. Pretreatment with carvedilol and celecoxib resulted in significant decrease in tissue MDA contents (30% and 27%, respectively) compared to acetic acid group and (25% and 30%, respectively) compared to prednisolone group. Similarly, acetic acid resulted in significant increase (119%) in NO tissue contents compared to control group. On the other hand, pretreatment with prednisolone significantly decreased (28%) tissue NO contents compared to acetic acid group. Pretreatment with carvedilol and celecoxib resulted in significant decrease in tissue NO contents (25% and 16%, respectively) compared to acetic acid group and (26% and 42%, respectively) compared to prednisolone group (Fig. 2). Fig. 3 shows that induction of colitis caused a significant elevation of tissue TNF-content (30%) compared to control group and prednisolone significantly reduced TNF-content (16%) compared to acetic acid group. Furthermore, pretreatment with carvedilol and celecoxib significantly reduced tissue TNF-content (31% and 20%, respectively) compared to acetic acid group and (27% and 47%, respectively) compared to prednisolone group. As shown in Fig. 4, induction of ulcerative colitis in rats resulted in significant decrease (49%) in

GSH tissue contents compared to control group. On the other hand, pretreatment with prednisolone significantly increased (76%) tissue GSH contents compared to acetic acid group. Pretreatment with carvedilol and celecoxib resulted in significant increase in tissue GSH contents (47% and 24%, respectively) compared to acetic acid group and (16% and 29%, respectively) compared to prednisolone group. Fig. 5a shows that induction of colitis caused a significant increase in mRNA levels of p38 MAPK (243%) compared to control group and prednisolone significantly reduced mRNA levels of p38 MAPK (58%) compared to acetic acid group. Furthermore, pretreatment with carvedilol and celecoxib significantly reduced tissue mRNA levels of p38 MAPK (51% and 38%, respectively) compared to acetic acid group and (17% and 48%, respectively) compared to prednisolone group. Histopathological examination of normal colon tissue revealed normal colonic mucosal glands with average in size and shape showing goblet cells (Fig. 6a). Induction of ulcerative colitis by acetic acid resulted in sub-mucosal infiltration of chronic inflammatory cells with hyperplasia, excessive thickening and ulceration (Fig. 6b-d). Pretreatment with prednisolone significantly reduced inflammation and infiltration of hyperplastic gland with no loss of goblet cells (Fig. 6e). On the other hand, treatment of rats with carvedilol showed mild infiltration of inflammatory cells and decreased scores of hyperplastic glands with no loss of goblet cells (Fig. 6f). Similarly, celecoxib decreased the scores of inflammatory cells and hyperplastic glands but to a lesser extent (Fig. 6g). Immunohistochemical staining for COX-2 expression in colon tissue showed strong positive staining for COX-2 in acetic acid group compared to control group (Fig. 7b). Treatment of animals with prednisolone showed weak cytoplasmic COX-2 positivity (Fig. 7c) while pretreatment with carvedilol showed moderate cytoplasmic COX-2 positivity (Fig. 7d) and pretreatment with celecoxib showed marked cytoplasmic COX-2 positivity (Fig. 7e).



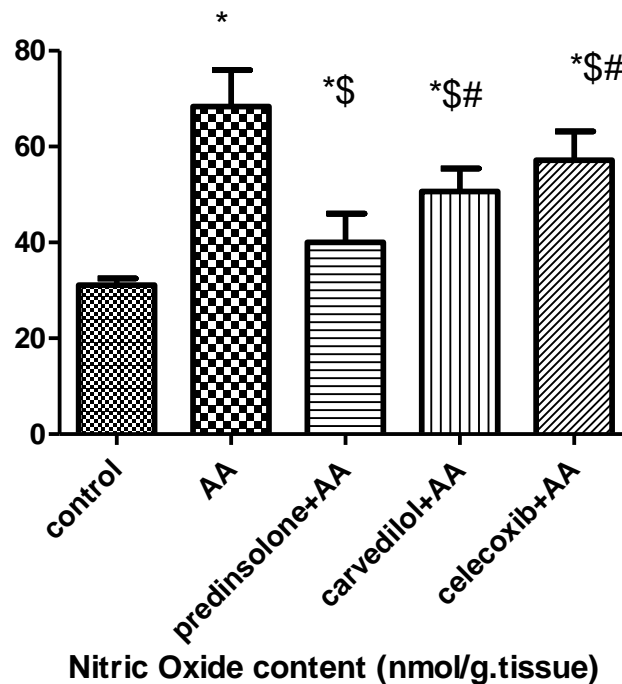
**Fig. 1. Comparison of tissue MDA content (nmol /g.tissue) in different groups**

Values are presented as mean±SD. n=8

\* Significant difference from control group at  $p < 0.05$

\$ Significant difference from AA group at  $p < 0.05$ .

# Significant difference from Prednisolone group at  $p < 0.05$



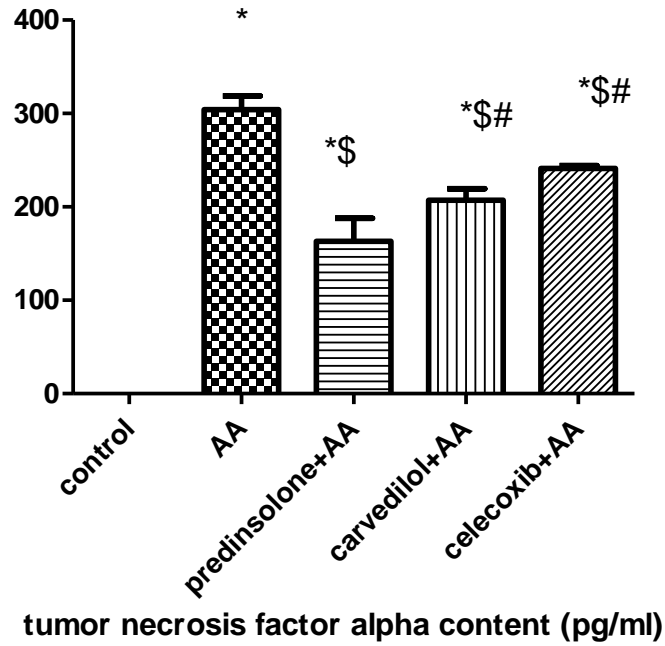
**Fig. 2. Comparison of NO content (nmol/g.tissue) in different groups**

Values are presented as mean±SD. n=8

\* Significant difference from control group at  $p < 0.05$

\$ Significant difference from AA group at  $p < 0.05$ .

# Significant difference from Prednisolone group at  $p < 0.05$



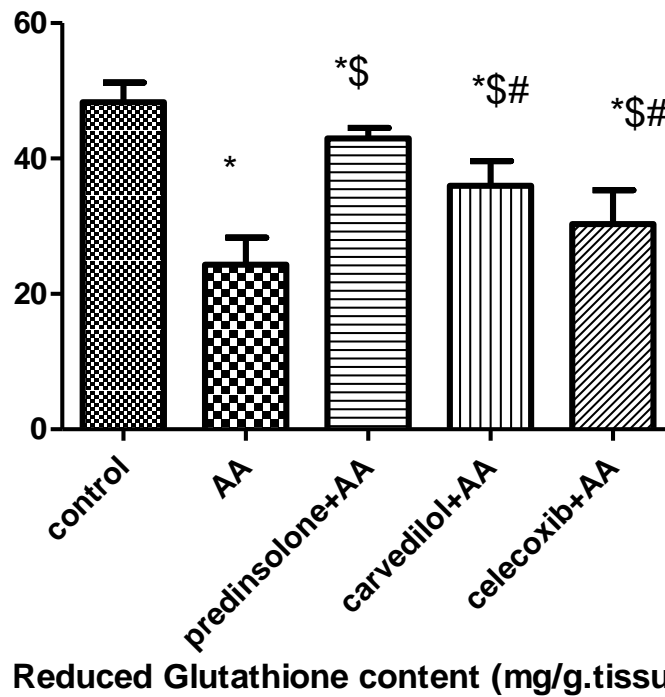
**Fig. 3. Comparison of tissue TNF-α content (pg/ml) in different studied groups**

Values are presented as mean±SD. n=8

\* Significant difference from control group at p< 0.05

§ Significant difference from AA group at p< 0.05.

# Significant difference from Prednisolone group at p< 0.05



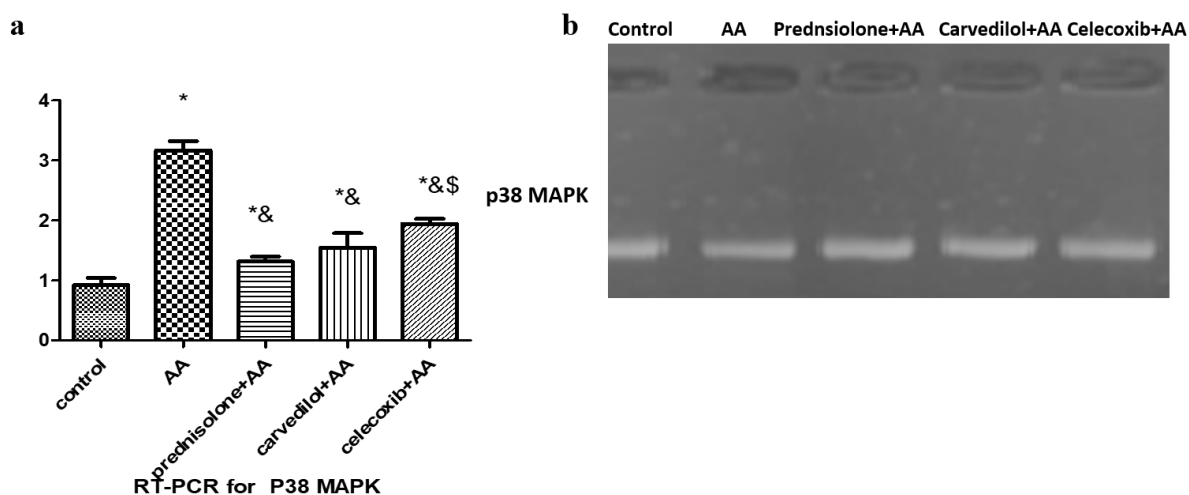
**Fig. 4. Comparison of GSH (mg/g. tissue) in different groups**

Values are presented as mean±SD. n=8

\* Significant difference from control group at p< 0.05

§ Significant difference from AA group at p< 0.05.

# Significant difference from Prednisolone group at p< 0.05



**Fig. 5. (a) Semiquantitative analysis of p38 MAPK in different groups in colonic tissue as determined by reverse transcription quantitative polymerase chain reaction. Values are presented as mean±SD. n=8 (b) PCR analysis of p38 MAPK in different groups**

*Significant difference from control group at p< 0.05*

*& Significant difference from AA*

#### 4. DISCUSSION

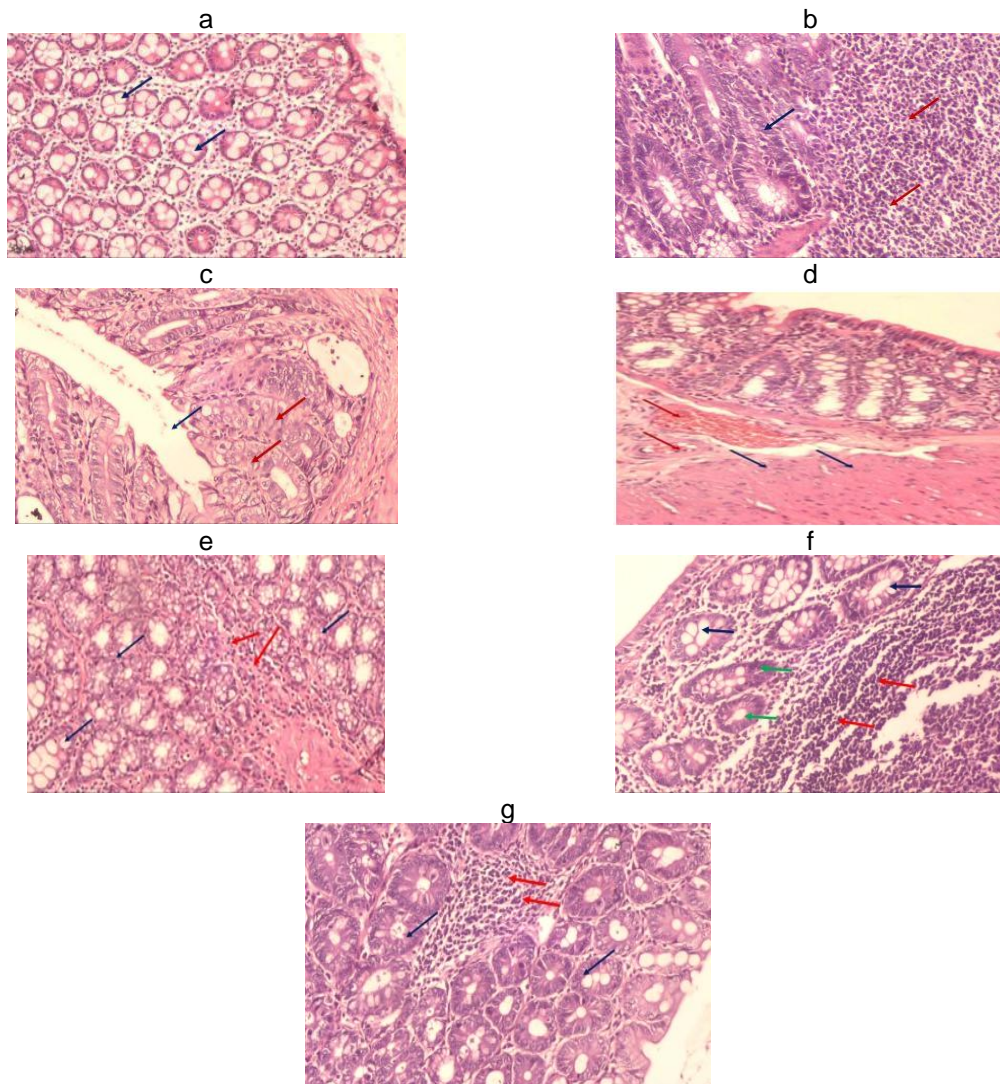
In the present study, acetic acid-induced ulcerative colitis resulted in significant elevation of oxidative stress markers (MDA and NO) together with significant reduction in antioxidant GSH content in colon tissue. Ulcerative colitis belongs to inflammatory bowel diseases that affect millions of people all over the world. The etiology of such diseases remain unknown but recent studies have suggested that excessive activation of immune system targeting gut micro biota play pivotal role [29,30]. We suggest that activation of mucosal immune system results in an inflammatory state accompanied by dysregulation of cytokine system which activate oxidative stress and release of free radicals. Gastrointestinal tract (GIT) is a major site for reactive oxygen species (ROS) generation due to presence of microbes and food ingredients. This may decrease antioxidant capacity of patient and excessive generation of oxidative stress markers enhances lipid peroxidation and depletes antioxidant defense. This suggestion is supported by the observation in the current study that ulceritis was associated with significant increase of pro-inflammatory cytokines in colon tissue. In the current study, administration of prednisolone significantly reduced MDA and NO levels with significant elevation in GSH. So, prednisolone possesses an antioxidant effect. Prednisolone used as a standard therapy to inflammatory bowel diseases to reduce inflammation and allow bowel to heal. However,

steroids are not recommended for long term treatment due to their unfavorable side effects and their inability to inhibit flare-ups. So, there is an emergent need to reduce or stop steroids or move to alternative medications [31-33]. Results of the present study revealed that carvedilol possesses antioxidant effect by more significant reduction in MDA, NO and more significant elevation in GSH tissue contents. To our knowledge, this is first study to test effectiveness of carvedilol in acetic acid-induced ulcerative colitis model. Inhibitory effects of carvedilol on lipid peroxidation are due to its antioxidant activity and its ability to suppress inducible nitric oxide synthase (iNOS) expression. Carvedilol promote nitric oxide (NO-induced) vasodilatation through endothelial nitric oxide synthase (eNOS)-mediated  $\beta_3$ -adrenoceptor activation [34]. Carvedilol act as antioxidants through inhibition of nicotinamide adenine dinucleotide phosphate (NADPH) oxidase, subsequent superoxide dismutase (SOD) reduction and prevention of eNOS uncoupling [35]. Results of current study indicated that antioxidant capacity of damaged mucosa is compromised. So, use of non-traditional therapy as antioxidants will inhibit cell damage and improve activity of antioxidant defense. Some studies have reported that blocking  $\beta$ -adrenoceptor has an anti-inflammatory effect and was associated with decreased levels of pro-inflammatory cytokines [36]. Carvedilol was first third-generation  $\beta$ -blocker which exhibits antioxidant activity. Its antioxidant property is due to its carbazole



moiety [37,38]. Carvedilol exhibited antioxidant effects by reducing superoxide production by inhibiting NADPH oxidase and preventing eNOS uncoupling. Another possible mechanism is

acting within mitochondria as reactive oxygen species (ROS) scavenger through inhibiting superoxide anion or hydrogen peroxide. In present study, pretreatment of rats with carvedilol

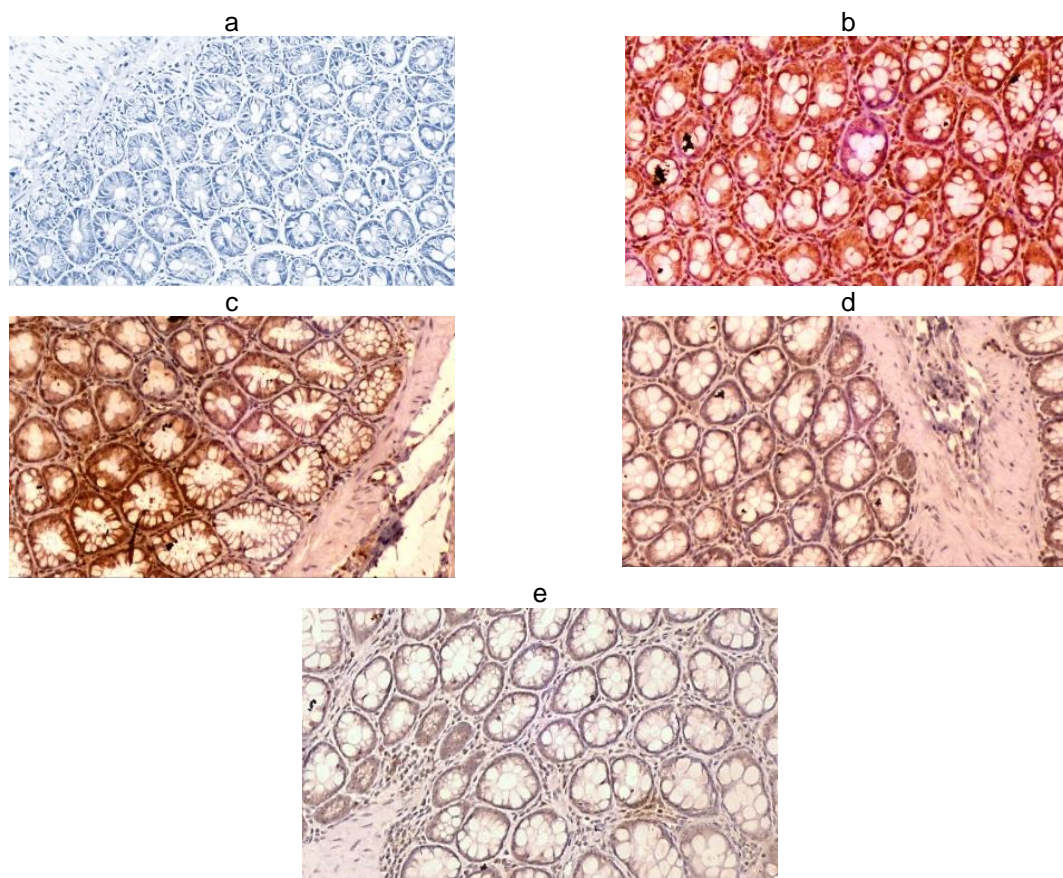


**Fig. 6. Photomicrographs of colon tissue (H&E x 100) (a) Section of colon of normal animal (negative control) showing normal colonic mucosal glands, average in size and shape showing goblet cells (blue arrows) separated by fibroblastic stroma (b) acetic acid group showing sub-mucosal large infiltrate of chronic inflammatory cells score 3 (red arrows) with hyperplasia of glands score 2 and loss of goblet cells score 3 (blue arrows) (c) Section of colon in AA showing ulceration score 3 (blue arrow) surrounded by hyperplastic glands with loss of goblet cells score 3 (red arrows) (d) Section of colon in AA group showing excessive muscle thickening score 3 (blue arrow) surrounded by congested vessels (red arrows) with overlying colonic mucosa (e) Section of colon in prednisolone in animal showing individual chronic inflammatory cells infiltrate score 1 (red arrows) with hyperplastic glands score 1 (blue arrows) with no loss of goblet cells score 0 (f) Section of colon in carvedilol group showing mild infiltrate of chronic inflammatory cells score 2 (red arrows) with hyperplastic glands score 2 (blue arrows) with no loss of goblet cells score 0 (g) Section of colon in celecoxib group showing mucosal diffuse infiltrate of chronic inflammatory cells score 3 (red arrows) with hyperplastic glands score 2 (blue arrows) showing mild loss of goblet cells score 1 (green arrows)**

significantly decreased TNF- $\alpha$  level. This is similar to previous studies which showed that a similar drug, nebivolol significantly decreased TNF- $\alpha$  in ulcerative colitis model, in human umbilical vein and in human coronary sites [39-41]. Results for celecoxib pre-treated group showed that it significantly decreased MDA, NO, TNF- $\alpha$  and significantly increased GSH levels. These results are in agreement with previous data which showed that celecoxib caused a substantial reduction of degree of colonic injury, rise in myeloperoxidase and increase in malondialdehyde level in dinitrobenzene sulfonic acid (DNBS)-induced colitis [21]. "Function of cyclooxygenase-1 and cyclooxygenase-2 in maintaining mucosal homeostasis and modulating inflammation in digestive tract remains unclear. Prostanoids increased in experimental ulcerative colitis and in inflammatory bowel disease" [42,43]. Therefore, they play a protective role in colitis and down regulate the expression of proinflammatory cytokines. It was hypothesized that inducible cyclooxygenase-2 drives pro-inflammatory actions of prostaglandins during mucosal injury. So, gastro protective effects of celecoxib arise from its ability to inhibit COX-2 and its anti-inflammatory effect while avoiding gastrointestinal (GI) toxicity.

Pathogenesis of ulcerative colitis is closely associated with elevated TNF-content in colon mucosa and can be detected in inflamed tissues. So that, anti-inflammatory effect of celecoxib suppresses inflammation and reduces colon destruction caused by cytokines. In present study, the increased TNF- $\alpha$  in colon tissue was reduced by celecoxib. "In addition, treatment with celecoxib markedly reduced cellular infiltration and inflammation of colon tissue. Neutrophils have been considered to play a crucial role in the development of GI inflammation, as they are major source of free radicals in inflamed mucosa" [44,45]. Colonic inflammation is associated with infiltration of polymorph nuclear leukocytes. So, activation of neutrophils may be a major source of ROS and NOS species. In present study, we found that mucosal damage induced by acetic acid is associated with significantly high levels of MDA. This is a good indicator of lipid peroxidation. Epithelial disruption was significantly reduced in rats pretreated with celecoxib and this was associated with decreased tissue MDA and significant resolution of histological signs of inflammation. In a previous meta-analysis, it was found that Coxibs are safe in patients with inflammatory bowel

disease (IBD) compared to NSAIDs in patients suffering from rheumatic pain resistant to standard treatment [46]. Also, it was found that celecoxib do not augment IBD symptoms [47]. We showed by immunohistochemistry that COX-2 is expressed in mucosal epithelial cells in rats received acetic acid and this expression was significantly decreased by use of celecoxib. Results in present study indicates that ulcerative colitis induced a significant increase in mRNA levels of p38 MAPK as revealed by PCR. MAPK enzyme family is involved cytokine signal transduction within epithelial cell of gut mucosa. They are activated by phosphorylation which in turn activates specific transcription factors and subsequent target genes. So, there should be therapeutic regimes directed towards cytokine signaling pathways [48]. We showed that both celecoxib and carvedilol significantly reduced mRNA levels of p38 MAPK compared to acetic acid treated group. By inhibiting p38 MAPK, celecoxib and carvedilol can effectively suppress production of cytokines (e.g. TNF- $\alpha$ ). These data indicate that both drugs may act as inhibitors of p38 kinase. Inhibition of activity of MAPK is confirmed by significant reduction of TNF- $\alpha$  release in both carvedilol and celecoxib pre-treated groups. This also sheds more light on the importance of MAPK in the pathophysiology of colitis. To our knowledge, this is the first study to explore role of celecoxib and carvedilol in regulating MAPK pathway in ulcerative colitis model. Results of the present study are in agreement with previous studies which explored the regulation of MAPK/ERK/JNK signaling pathway in ulcerative colitis. It was found that chlorogenic acid reduces dextran sulfate sodium (DSS)-induced ulcerative colitis in mice, which can significantly reduce tissue inflammation and apoptosis. This action is through MAPK/ERK/JNK signaling pathway [49]. The key roles of p38 MAPK in inflammatory bowel disease (IBD) present in both immune and non-immune cells. First, p38 MAPK up regulates expression of some genes involved in intestinal inflammation, such as genes coding for TNF- $\alpha$ , cyclooxygenase-2, collagenase-1 and collagenase-3. Meanwhile, non-immune cells, like human intestinal micro vascular endothelial cells (HIMEC), intestinal epithelium, fibroblasts and myofibroblasts, are involved in IBD are under control of direct and indirect effect of p38 MAPK [50]. In present study, pre administration of celecoxib and carvedilol decreased p38 MAPK level due to their anti-inflammatory effects. In addition, increased activation of MAPK in current study plays a major role in promoting apoptosis.



**Fig. 7. Photomicrographs for immunohistochemical expression of COX-2 in colon tissue (X100) (a) Section of colon in control group showing negative COX-2 immunoreactivity (b) Section of colon in acetic acid group showing very marked cytoplasmic COX-2 positivity (score 12) (c) Section of colon in prednisolone group showing weak cytoplasmic COX-2 positivity (score 2) (d) Section of colon in carvedilol group showing moderate cytoplasmic COX-2 positivity (score 4) (e) Section of colon in celecoxib group showing marked cytoplasmic COX-2 positivity**

This was evident by increased apoptosis in tissue samples from ulcerative colitis groups. Activation of p38 MAPK also regulates adhesion and transmigration of lymphocytes across microvasculature by up regulation of vascular cell adhesion protein 1 (VCAM-1) and intercellular adhesion molecule 1 (ICAM-1). On the other hand, inhibition of p38 MAPK leads to decreased leukocyte recruitment in inflamed bowel [51]. So, both celecoxib and carvedilol decreased inflammatory cell recruitment to colonic tissue and increased structural integrity of the mucosa. In the current study, administration of both carvedilol and celecoxib was associated with decreased intestinal damage, mitochondrial swelling, reactive oxygen species and MAPK, which indicate that both drugs can reduce mitochondrial damage by improving intestinal mitochondrial ultrastructure. Results of

experiment showed that both drugs can significantly improve tissue damage, reduce inflammatory factors and increase expression of anti-inflammatory factors, indicating that these drugs have protective effects on acetic acid - induced ulcerative colitis.

## 5. CONCLUSION

Results of present study revealed that both celecoxib and carvedilol have protective effects on acetic-acid induced ulcerative colitis and their effects are due to anti-inflammatory, antioxidant effects and their ability to suppress p38 MAPK.

## CONSENT

It's not applicable.



## ETHICAL APPROVAL

Animal Ethic committee approval has been collected and preserved by the author(s).

## COMPETING INTERESTS

Authors have declared that no competing interests exist.

## REFERENCES

1. Chen Q, Bei S, Zhang Z, Wang X, Zhu Y. Identification of diagnostic biomarks and immune cell infiltration in ulcerative colitis. *Scientific Reports*. 2023;13(1):6081.
2. Paley EL. Discovery of gut bacteria specific to Alzheimer's associated diseases is a clue to understanding disease etiology: meta-analysis of population-based data on human gut metagenomics and metabolomics. *Journal of Alzheimer's Disease*. 2019;72(1):319-55.
3. Fu Y, Kurin M, Landsman M, Fass R, Song G. Irritable Bowel Syndrome Is an Independent Risk Factor for Developing Opioid Use Disorder in Patients with Inflammatory Bowel Disease. *Journal of Personalized Medicine*. 2023;13(6):917.
4. Neto MB, Ramos GP, Loftus EV, Faubion WA, Raffals LE. Use of immune checkpoint inhibitors in patients with pre-established inflammatory bowel diseases: retrospective case series. *Clinical Gastroenterology and Hepatology*. 2021;19(6):1285-7.
5. Zheng X, Hu M, Zang X, Fan Q, Liu Y, Che Y, et al., Kynurenic acid/GPR35 axis restricts NLRP3 inflammasome activation and exacerbates colitis in mice with social stress. *Brain, Behavior, and Immunity*. 2019;79:244-55.
6. Kayali S, Gaiani F, Manfredi M et al. Inverse association between *Helicobacter pylori* and inflammatory bowel disease: myth or fact? *Acta. Bio. Medica. Atenei. Parmensis*. 2018;89(9-S):81-86.
7. Badr G, Elsayw H, Amalki MA, Alfwuaires M, El-Gerbed MS, Abdel-Moneim AM. Protective effects of myristicin against ulcerative colitis induced by acetic acid in male mice. *Food and Agricultural Immunology*. 2020;31(1):435-46.
8. Taurone S, Ralli M, Artico M, Madia VN, Scarpa S, Nottola SA, et al., Oxidative stress and visual system: A review. *EXCLI journal*. 2022;21:544-53.
9. Tarabar D, El Jurdi K, Traboulsi C, Yvellez O, Milenkovic Z, Petrovic S, et al. A prospective trial with long term follow-up of patients with severe, steroid-resistant ulcerative colitis who received induction therapy with cyclosporine and were maintained with vedolizumab. *Inflammatory Bowel Diseases*. 2022;28(10):1549-54.
10. Fatani AJ, Al-Hosaini KA, Ahmed MM et al. Carvedilol attenuates inflammatory biomarkers and oxidative stress in a rat model of ulcerative colitis. *Drug Dev Res*. 2015;76(4):204-214.
11. Packer M. Molecular, cellular, and clinical evidence that sodium-glucose cotransporter 2 inhibitors act as neurohormonal antagonists when used for the treatment of chronic heart failure. *Journal of the American Heart Association*. 2020;9(16):e016270.
12. Zununi Vahed S, Ardalan M, Khalilov R, Ahmadian E. Betanin prohibits cisplatin-induced nephrotoxicity through targeting mitochondria. *Journal of Research in Pharmacy*. 2019;23(6).
13. Wu Y, Li Z, Xiu AY, Meng DX, Wang SN, Zhang CQ. Carvedilol attenuates carbon tetrachloride-induced liver fibrosis and hepatic sinusoidal capillarization in mice. *Drug Design, Development and Therapy*. 2019:2667-76.
14. Ahmed I, Elkablawy MA, El-Agamy DS, Bazarbay AA, Ahmed N. Carvedilol safeguards against aspirin-induced gastric damage in rats. *Human & experimental toxicology*. 2020;39(9):1257-67.
15. Shin S. Safety of celecoxib versus traditional nonsteroidal anti-inflammatory drugs in older patients with arthritis. *J Pain Res*. 2018;14(11):3211-3219.
16. Arslan A, Yet B, Nemitlu E, Akdağ Çaylı Y, Eroğlu H, Öner L. Celecoxib nanoformulations with enhanced solubility, dissolution rate, and oral bioavailability: experimental approaches over *in vitro/in vivo* Evaluation. *Pharmaceutics*. 2023;(2):15(2):363.
17. Glicksman M, Jow S, Malmut L. Celecoxib for Management of Refractory Back Pain Secondary to Vertebral Osteomyelitis: A Case Report. *Journal of Medical Cases*. 2021;12(7):291.
18. Dugani A, Dakhil B and Treesh S. Protective effect of the methanolic extract of malva parviflora leaves on acetic acid-induced ulcerative colitis in rats. *Saudi*

- journal of gastroenterology: Official journal of the Saudi Gastroenterology Association 2016;22(3):226-233.
19. Mousavizadeh K, Rahimian R, Fakhfour G et al. Anti-inflammatory effects of 5-HT receptor antagonist, Tropisetron on experimental colitis in rats. *Eur J Clin Invest.* 2009;39:375-383.
  20. Sadraei H, Asghari G, Khanabadi M et al. Anti-inflammatory effect of apigenin and hydroalcoholic extract of *Dracocephalum kotschyi* on acetic acid-induced colitis in rats. *Res Pharm Sci.* 2017;12(4):322-329.
  21. Cuzzocrea S, Mazzon E, Serraino I, et al. Celecoxib, a selective cyclo-oxygenase-2 inhibitor reduces the severity of experimental colitis induced by dinitrobenzene sulfonic acid in rats. *Eur J Pharmacol.* 2001;431(1):91-102
  22. Milevic A, Simic M, Tomovic M, Rankovic M, Jakovljevic V, Bradic J. Effects of methanol extract of *Galium verum* L. On cardiac redox state in hypertensive rats after ischemia. *Brazilian Journal of Pharmaceutical Sciences.* 2022;58.
  23. Goroncharovskaya IV, Evseev AK, Klychnikova EV, Tazina EV, Bogdanova AS, Shabanov AK, et al., Electrochemical measurements of the levels of nitric oxide metabolites in the blood serum. *Journal of Clinical Practice.* 2023;14(1):6-11.
  24. Chai SK. Rational choice and culture: clashing perspectives or complementary modes of analysis? In: Ellis RJ and Thompson M (eds.) *Culture matters.* Boulder, CO: Westview Press, 2018:45-56.
  25. Hamam H, Demir H, Aydin M, Demir C. Determination of some antioxidant activities (superoxide dismutase, catalase, reduced glutathione) and oxidative stress level (malondialdehyde acid) in cirrhotic liver patients. *Middle Black Sea Journal of Health Science.* 2022;8(4):506-14.
  26. Bai XS, Bai G, Tang LD, et al. MiR-195 alleviates ulcerative colitis in rats via MAPK signaling pathway. *Eur Rev Med Pharmacol Sci.* 2020;5:2640-2646.
  27. Ahmed AA, Attia MM, Magdy AE, Abd Ellatif RA. Histological study of the effect of quercetin on experimentally induced ulcerative colitis in adult male albino rats. *Tanta Medical Journal.* 2022;50(4): 285.
  28. Giuliano A. Companion animal model in translational oncology; feline oral squamous cell carcinoma and canine oral melanoma. *Biology.* 2022;11(1):54.
  29. Ohno M, Nishida A, Sugitani Y et al. Nanoparticle curcumin ameliorates experimental colitis via modulation of gut microbiota and induction of regulatory T cells. *Plos One.* 2017;12(10):e0185999
  30. Mücahit UG, Kamiş F, Beyazit Y. Evaluation of clinical features, treatment options and complications in patients with inflammatory bowel disease. *Family Practice and Palliative Care.* 2022;7(3):64-70.
  31. Müller L, Lorentz A. Probiotics in the Treatment of inflammatory bowel diseases in adulthood: A systematic review. *Journal of Gastrointestinal & Liver Diseases.* 2022;31(1).
  32. Gionchetti P et al. Use of corticosteroids and immunosuppressive drugs in inflammatory bowel disease: Clinical practice guidelines of the Italian Group for the Study of Inflammatory Bowel Disease Italian Group for the Study of Inflammatory Bowel Disease (IG-IBD). *Digestive and Liver Disease.* 2017;49:604–617.
  33. Song K, Wu D. Shared decision-making in the management of patients with inflammatory bowel disease. *World Journal of Gastroenterology.* 2022;28(26):3092-100.
  34. MacLean J, Pasumarthi KB. Adrenergic Receptor Signaling Pathways in the Regulation of Apoptosis and Autophagy in the Heart. *Biochemistry of Apoptosis and Autophagy.* 2022:23-36.
  35. Farhoumand LS, Liu H, Tsimpaki T, Hendgen-Cotta UB, Rassaf T, Bechrakis NE, et al., Berchner-Pfannschmidt U. Blockade of  $\beta$ -Adrenergic Receptors by Nebivolol Enables Tumor Control Potential for Uveal Melanoma in 3D Tumor Spheroids and 2D Cultures. *International Journal of Molecular Sciences.* 2023;24(6):5894.
  36. Nathalie HT, Seebohm SS. Virus-host interactions of enteroviruses and parvovirus B19 in myocarditis. *Cell Physiol Biochem.* 2021;55:679-703.
  37. Ma Z, Liu X, Zhang Q, Yu Z, Gao D. Carvedilol suppresses malignant proliferation of mammary epithelial cells through inhibition of the ROS-mediated PI3K/AKT signaling pathway. *Oncology reports.* 2019;41(2):811-8.
  38. Ekestubbe L, Bass GA, Forssten MP, Sjölin G, Cao Y, Matthiessen P, et al., Pharmacological differences between beta-blockers and postoperative mortality

- following colon cancer surgery. *Scientific Reports*. 2022;12(1):5279.
39. Ali F, Khan A, Muhammad SA, Abbas SQ, Hassan SS, Bungau S. Genome-wide Meta-analysis Reveals New Gene Signatures and Potential Drug Targets of Hypertension. *ACS omega*. 2022;7(26):22754-72.
40. El-Sheikh AA, Morsy MA, Abdel-Latif RG. Modulation of eNOS /iNS by nebivolol protects against cyclosporine A-mediated nephrotoxicity through targeting inflammatory and apoptotic pathways. *Environmental Toxicology and Pharmacology*. 2019;69:26-35.
41. Nurlu Temel E, Savran M, Erzurumlu Y, Hasseyid N, Buyukbayram HI, Okuyucu G, et al., The  $\beta$ 1 Adrenergic Blocker Nebivolol Ameliorates Development of Endotoxic Acute Lung Injury. *Journal of Clinical Medicine*. 2023;12(5):1721.
42. Shah SA, Bousvaros A, Stevens AC. Immunomodulating Agents in Gastrointestinal Disease. *InImmune Modulating Agents* 2020:267-299.
43. Di Rosa C, Altomare A, Imperia E, Spiezia C, Khazrai YM, Guarino MP. The Role of Dietary Fibers in the Management of IBD Symptoms. *Nutrients*. 2022;14(22):4775.
44. Li J, Qiu H, Gong H, Tong W. Broad-spectrum reactive oxygen species scavenging and activated macrophage-targeting microparticles ameliorate inflammatory bowel disease. *Biomacromolecules*. 2021;22(7):3107-18.
45. Margaret AP, Frank NB, Gilbert M, James D. Design and biological evaluation of tissue-directed  $\alpha$ -tocopherol analogs. In *Handbook of Synthetic Antioxidants* 2019:53-94.
46. Lubrano E, Luchetti MM, Benfaremo D, Mauro D, Ciccia F, Perrotta FM. Inflammatory bowel disease manifestations in spondyloarthritis: considerations for the clinician. *Expert Review of Clinical Immunology*. 2021;17(11):1199-209.
47. Vodnizza SE, De La Fuente MP, Cancino EC. Approach to the patient with axial spondyloarthritis and suspected inflammatory bowel disease. *Rheumatic Disease Clinics*. 2020;46(2):275-86.
48. Gao J, Yu W, Zhang C, Liu H, Fan J, Wei J. The protective effect and mechanism of Aornia melanocarpa Elliot anthocyanins on IBD model mice. *Food Bioscience*. 2021;41:101075.
49. Gao W, Wang C, Yu L et al. Chlorogenic acid attenuates dextran sodium sulfate-induced ulcerative colitis in mice through MAPK/ERK/JNK pathway. *BioMed Research International* 2019; Article ID 6769789.
50. Guo X, Li X, Dong Y, Xie W, Jin T, Xu D, et al. Cod (Gadus) skin collagen peptide powder reduces inflammation, restores mucosal barrier function, and inhibits fibrosis in dextran sodium sulfate-induced colitis in mice. *Journal of Ethnopharmacology*. 2023:116728.
51. Martins AS, Campos SB, Goulart MO, Moura FA. Extraintestinal manifestations of inflammatory bowel disease, nitroxidative stress and dysbiosis: What is the link between them? *Biocell*. 2021;45(3):461.

© 2023 Abuhashish et al.; This is an Open Access article distributed under the terms of the Creative Commons Attribution License (<http://creativecommons.org/licenses/by/4.0>), which permits unrestricted use, distribution, and reproduction in any medium, provided the original work is properly cited.

*Peer-review history:*

*The peer review history for this paper can be accessed here:*  
<https://www.sdiarticle5.com/review-history/101224>