



Hematoma of the Abdominal Sheath Induced by Cough, A Rare Finding in Clinical Practice: A Case Report

Chin-Chu Wu ^a and Aming Chor-Ming Lin ^{b,c*}

^a Department of Medical Imaging, Shin Kong Wu Ho-Su Memorial Hospital, Taipei, Taiwan.

^b Emergency Department, Shin Kong Wu Ho-Su Memorial Hospital, Taipei, Taiwan.

^c School of Medicine, Fu-Jen Catholic University, New Taipei City, Taiwan.

Authors' contributions

This work was carried out in collaboration between both authors. Both authors passed four criteria for authorship contribution based on recommendations of the international committee of medical journal editors. Both authors read and approved the final manuscript.

Article Information

DOI: 10.9734/JAMMR/2024/v36i35381

Open Peer Review History:

This journal follows the Advanced Open Peer Review policy. Identity of the Reviewers, Editor(s) and additional Reviewers, peer review comments, different versions of the manuscript, comments of the editors, etc are available here: <https://www.sdiarticle5.com/review-history/112960>

Case Study

Received: 15/12/2023

Accepted: 20/02/2024

Published: 24/02/2024

ABSTRACT

We report herein a case of rectus sheath hematoma (RSH) following a cough paroxysm treated as surgical intervention. RSH is a rare clinical condition of acute abdomen and often misdiagnosed in the emergency department. A 67-year-old woman presented to the emergency department with complaint of 2-day history of abdominal pain localized in left upper region. The pain was persistent. The patient reported that her pain worsened with coughing and certain movements. Abdominal muscle forceful contraction during coughing causes direct tear of the rectus muscle or rupture of epigastric arteries leading to formation of RSH, which is the accumulation of blood within anterior rectus abdominis muscle.

Keywords: *Abdominis muscle; rectus sheath hematoma; abdominal medication; cough paroxysm.*

*Corresponding author: E-mail: amingphd@yahoo.com.tw;

1. INTRODUCTION

“RSH is a rare clinical condition of acute abdomen and often misdiagnosed in the emergency department. RSH accounts for only about 1.8% of all acute abdominal pain” [1]. It is a well-documented complication of direct abdominal trauma, physical activity, abdominal medication injection, recent surgery, anticoagulant therapy, antiplatelet therapy, pregnancy or increased intra-abdominal pressure from coughing [2-7]. We report herein a case of rectus sheath hematoma following a cough paroxysm treated as surgical intervention.

2. CASE PRESENTATION

A 67-year-old woman presented to the emergency department with complaint of 2-day history of abdominal pain localized in left upper region. The pain was persistent. The patient reported that her pain worsened with coughing and certain movements. She suffered a severe cough for 5 days. She denied using anticoagulation agents and trauma. She had no history of hypertension, diabetes mellitus, malignancy or prior surgery. On arrival, she was hemodynamically stable. Her blood pressure was 131/80 mmHg, with a heart rate of 99 beats/minute and a respiratory rate of 18

breaths/minute. She was afebrile. On physical examination, the lung auscultation revealed the coarse breath sounds with fine crackles in the both lower lungs zones. Her abdominal examination revealed normal skin color, diffuse abdominal fullness and a palpable, firm, nonmobile and tender more marked over the left upper abdominal region with no guarding or rebound tenderness. Complete blood cell count and biochemistry were all reported in normal range. The patient underwent chest-abdomen-pelvis computed tomography (CT) scan. CT showed widespread areas of patchy consolidation in both lungs (Fig. 1) and rectus sheath hematoma that was measured to be approximately 5x4.5x2.5 cm in volume (Fig. 2, arrow).

The patient was admitted and given intravenous antibiotics for pneumonia and analgesics for rectus sheath hematoma. Tranexamic acid was started intravenously. Over the next few days, she improved slowly but continued to complain of persistent left upper abdomen pain associated with fever and postprandial vomiting. She underwent a Tumescent technique for the hematoma evacuated. The patient recovered with surgical management and intravenous antibiotics. She had an uneventful postoperative recovery and was discharged 11 days later.

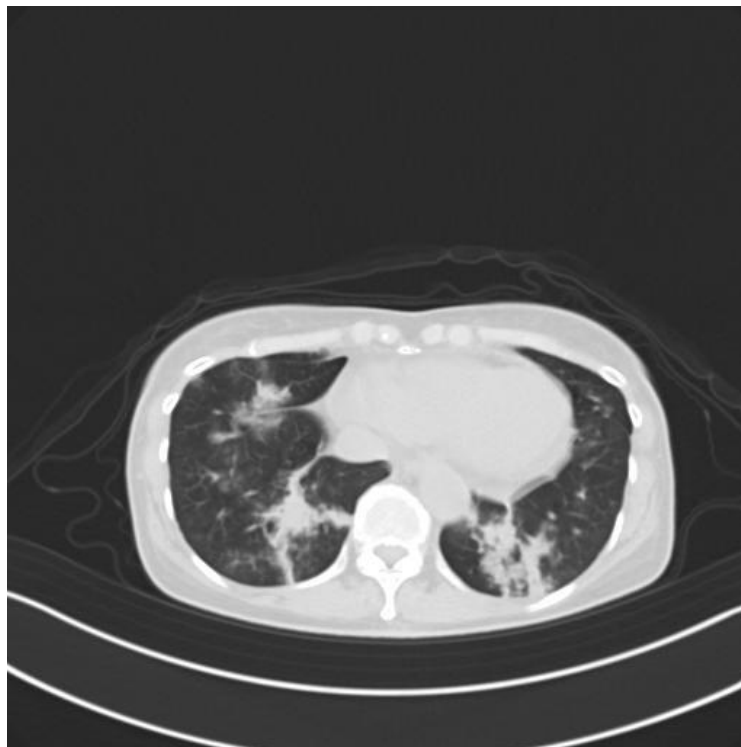


Fig. 1. Chest CT revealed widespread areas of patchy consolidation in both lungs

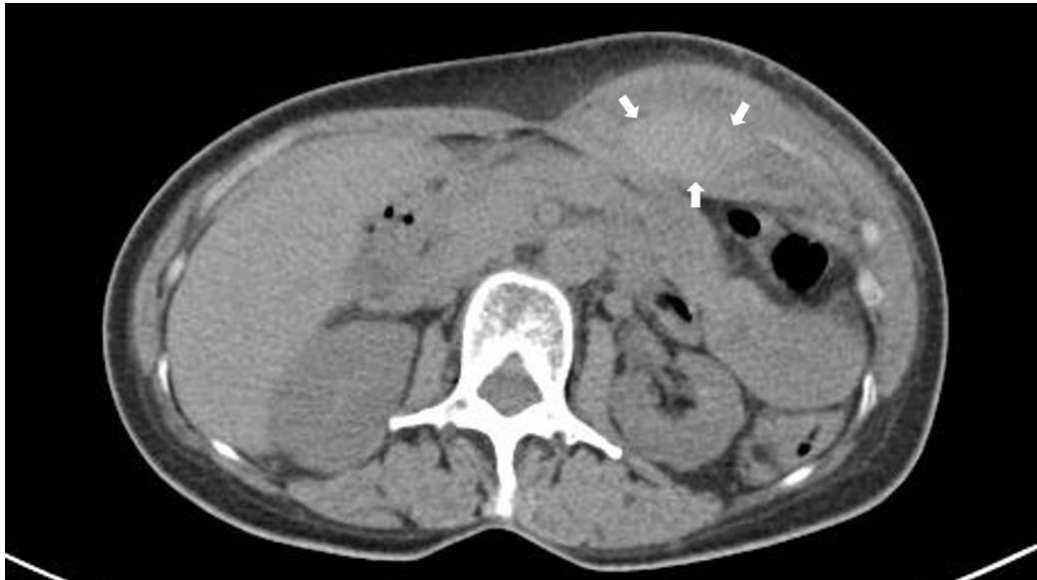

Fig. 2. Axial view of patient's abdomen computed tomography revealed a rectus hematoma

3. DISCUSSION

RSH is a relatively uncommon problem encountered in the emergency department and often clinically misdiagnosed cause of abdominal pain. The diagnosis is challenging. The typical presentation is acute abdominal pain, nausea, and fever. "RHS is the result of bleeding into the rectus sheath from damage to the epigastric arteries or from a direct tear of the rectus muscles. Delayed diagnosis of rectus sheath hematoma is still associated significant and morbidity and mortality" [5]. "The diagnosis may be suspected based upon clinical history, presentation, physical examination and radiologic findings. Trauma and anti-thrombotic medication are the most common risk factors" [8]. The other predisposing factors of RSH include vomiting, severe cough and pregnancy [9,10]. Abdominal muscle forceful contraction during coughing causes direct tear of the rectus muscle or rupture of epigastric arteries leading to formation of RSH. RSH is an accumulation of blood in the anterior rectus abdominis muscle. The initial evaluation of patients with clinical signs and symptoms of RSH should include abdomen examination. Abdominal examination reveals tenderness and swelling in the parietal wall. Ultrasound is usually the initial diagnostic test, but CT might be necessary to determine the origin and source of a rectus sheath hematoma. Secondary infection of hematoma should be considered if it is increasing in size or becoming more painful. The findings of clinical instability, persistent abdominal pain are concerning for intra-

abdominal sepsis, mandate immediate surgical intervention.

4. CONCLUSION

RHS should be keep in the mind as a patient having a severe cough presents with abdominal pain. Sudden abdominal pain together with a painful abdominal mass must alert emergency physicians about the diagnosis of abdominal hematoma. Thorough history taking, abdomen palpable mass on abdominal wall, diagnostic test of ultrasonography and CT are essential for the diagnosis of the condition.

CONSENT

Written informed consent was obtained from the patient and participant.

ETHICAL APPROVAL

As per international standards or university standards written ethical approval has been collected and preserved by the author(s).

ACKNOWLEDGMENTS

We would like to express our special thanks to Shin Kong Wu Ho-Su Memorial Hospital staff.

COMPETING INTERESTS

Authors have declared that no competing interests exist.

REFERENCES

1. Klingler PJ, Wetscher G, Glaser K, Tschmelitsch J, Schmid T, Hinder RA. The use of ultrasound to differentiate rectus sheath hematoma from other acute abdominal disorders. *Surg Endosc.* 1999; 13(11):1129-34.
2. Chagal KH, Saleem S, Ghous G: Rectus sheath haematoma: A rare masquerader for abdominal pain. *BMJ Case Rep.* 2017;2017-219976.
3. Elango K, Murthi S, Devasahayam J, et al. Spontaneous rectus sheath haematoma due to cough on apixaban. *BMJ Case Rep.* 2018;2018-225136.
4. Gunasekaran K, Winans ARM, Murthi S, Ahmad MR, Kaatz S. Rectus sheath hematoma associated with apixaban. *Clin Pract.* 2017;7(3):957. DOI: 10.4081/cp.2017.957 PMID: 28808519; PMCID: PMC5541236
5. Wong CL, So CHY. Spontaneous rectus sheath hematoma associated with apixaban in an elderly gentleman with chronic obstructive airway disease- A case report. *Thrombosis J.* 2022;20: 59. Available: <https://doi.org/10.1186/s12959-022-00420-z>
6. Mendes D, Penedones A, Martins M, Cavadas S, Alves C, Batel-Marques F. Rectus sheath hematoma in patients receiving subcutaneous enoxaparin: A case series of five patients. *Clin Case Rep.* 2020;8:3431-3438. Available: <https://doi.org/10.1002/ccr3.3427>
7. Chaves C, Reigota C, Vilão F. Rare Cause of Cough-induced abdominal pain. *Cureus.* 2023;15(7):e42530. DOI: 10.7759/cureus.42530 PMID: 37637526; PMCID: PMC10458406
8. Koyuncu A, Vardar YM. Rectus sheath hematoma as a revisited and rare cause of abdominal pain? *Ann Ital Chir.* 2022;93: 410-414. PMID: 36155938
9. R Humphrey, SJ Carlan, L Greenbaum: Rectus sheath hematoma in pregnancy. *Clin Ultrasound.* 2001;29:306-311.
10. Noel W, Donahue BB. Cough causing abdominal pain? A rapid POCUS diagnosis of rectus sheath hematoma. *POCUS J.* 2023;8(2):121-123. DOI: 10.24908/pocus.v8i2.16500 PMID: 38099162; PMCID: PMC10721295

© Copyright (2024): Author(s). The licensee is the journal publisher. This is an Open Access article distributed under the terms of the Creative Commons Attribution License (<http://creativecommons.org/licenses/by/4.0>), which permits unrestricted use, distribution, and reproduction in any medium, provided the original work is properly cited.

Peer-review history:

The peer review history for this paper can be accessed here:
<https://www.sdiarticle5.com/review-history/112960>