

Ureteral Hematoma Complicating Anti-Vitamin K Treatment

Lachhab Houssame^{1*}, El Adaoui Abdelmajid², Mohammed Ettaouil¹,
Moudlige Hamza¹, Waffar Chouaib¹, Moataz Amine¹, Dakir Mohammed¹,
Debbagh Adil¹ and Aboutaieb Rachid¹

¹Department of Urology, Chu Ibn Rochd Casablanca, Morocco.
²Department of Cardiology, Chu Ibn Rochd Casablanca, Morocco.

Authors' contributions

This work was carried out in collaboration among all authors. All authors read and approved the final manuscript.

Article Information

Editor(s):

(1) Dr. Punit Bansal, RG Stone and Superspeciality Hospital, India.
(2) Dr. Muhammad Ujudud Musa, Federal Medical Centre, Katsina, Nigeria.

Reviewers:

(1) Mairi Pucci, University of Verona, Italy.
(2) Kalaimani Elango, University of Nevada Las Vegas School of Medicine, USA.
Complete Peer review History: <http://www.sdiarticle4.com/review-history/66698>

Case Study

Received 25 January 2021
Accepted 30 March 2021
Published 11 April 2021

ABSTRACT

Sub-mucosal hemorrhage of the ureteral wall has only been reported in exceptional cases. We report the case of a 78-year-old male presented with macroscopic hematuria and right lumbar pains with an overdose of anticoagulant treatment. An abdominal CT Scan with Contrast was performed which led to the diagnosis of submucosal hematoma of the wall of the ureter and the right pelvis. Clinical improvement was rapidly favorable after adaptation of the anti-coagulant treatment.

Keywords: Hematuria; anticoagulant treatment; ureteral wall; lumbar pain.

ABBREVIATIONS

AVK : Antivitamin K
INR : International normalized ratio

PR : Prothrombin ratio
CBEU: Cytobacteriological examination of urine
CRP : c-reactive protein
CT : Computed tomography

*Corresponding author: Email: lachhabhoussame@gmail.com;

1. INTRODUCTION

Macroscopic hematuria, a frequent complication during treatment with anti-vitamin K, most often related to an underlying pathology [1], sometimes linked to a manifestation of the hemorrhagic effect of the treatment. In this context sub-mucosal hemorrhage of the ureteral wall has only been reported in exceptional cases [2-4]. A case of ureteral hematoma complicating anti-vitamin K treatment is reported.

2. CASE PRESENTATION

A 78-year-old patient with a double mechanical mitro-aortic valve replacement for 10 years, undergoing long-term antivitamin K treatment, admitted to urology department for low to medium hematuria. He presented right lumbar pains radiating towards the external genitals, suggestive of nephretic colic. On clinical examination, he had a blood pressure of 120 / 70 mmHg, a pulse rate of 82 beats / minute, with

sensitivity of the right lumbar fossa without palpable mass. Biological examinations showed overdose of AVK with an INR dosed at 9.1 and a PR at 8%. The CBEU was sterile, there was no anaemia, no thrombocytopenia, or hyperleukocytosis. Renal function and CRP were normal. Emergency pelvi-abdominal ultrasound showed a nonspecific right pyelic hypoechoic image. An abdominal CT Scan with Contrast was performed which revealed a clear spontaneously hyperdense, circumferential, regular thickening in the wall of the right ureter and pelvis (Fig. 1), not enhanced after injection, without obstructive syndrome. At the excretory time, there was no delay in excretion on the right side compared to the left side. The very evocative aspect of the CT scan and the clinicobiological context led to the diagnosis of submucosal haematoma of the wall of the ureter and the right pelvis secondary to anticoagulant treatment. The clinical course was rapidly favorable after three days of adaptation of the anti-coagulant treatment with marked radiological regression on day 21 (Fig. 2).

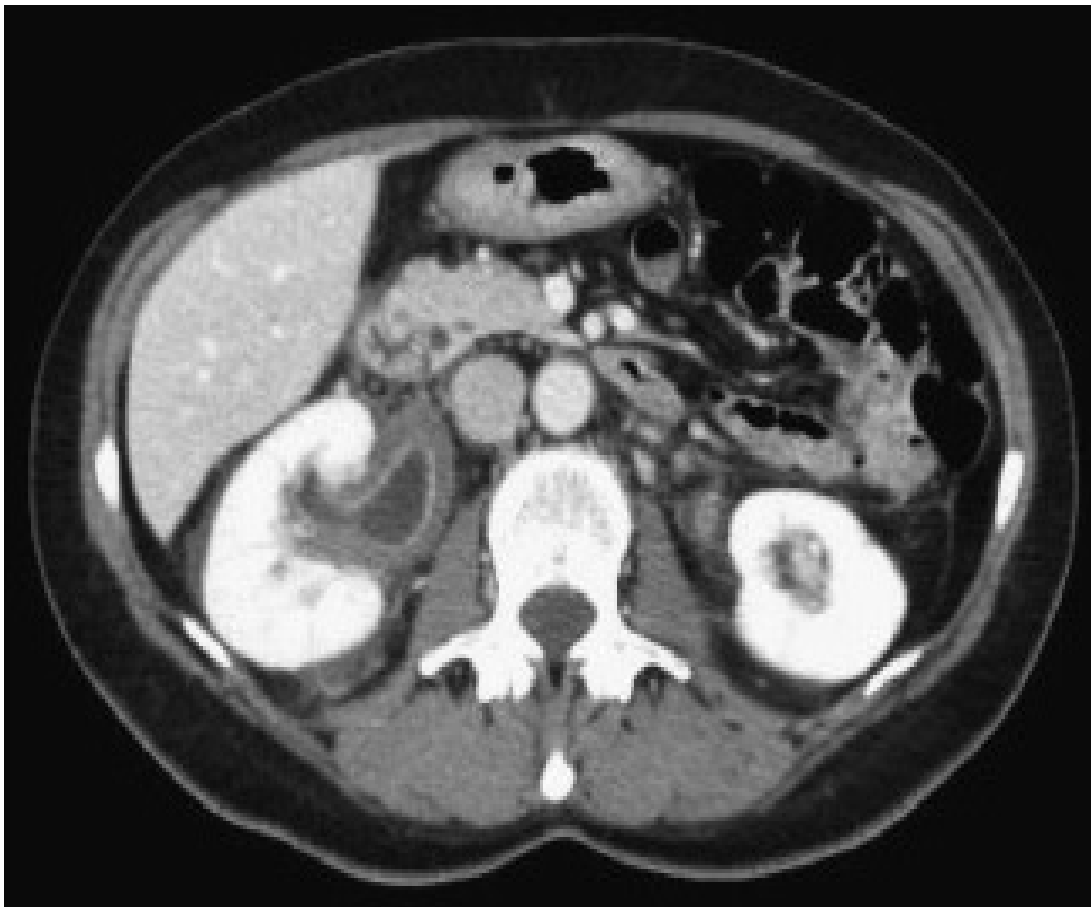


Fig. 1. Parietal hematoma of the right pyelo-ureteral junction

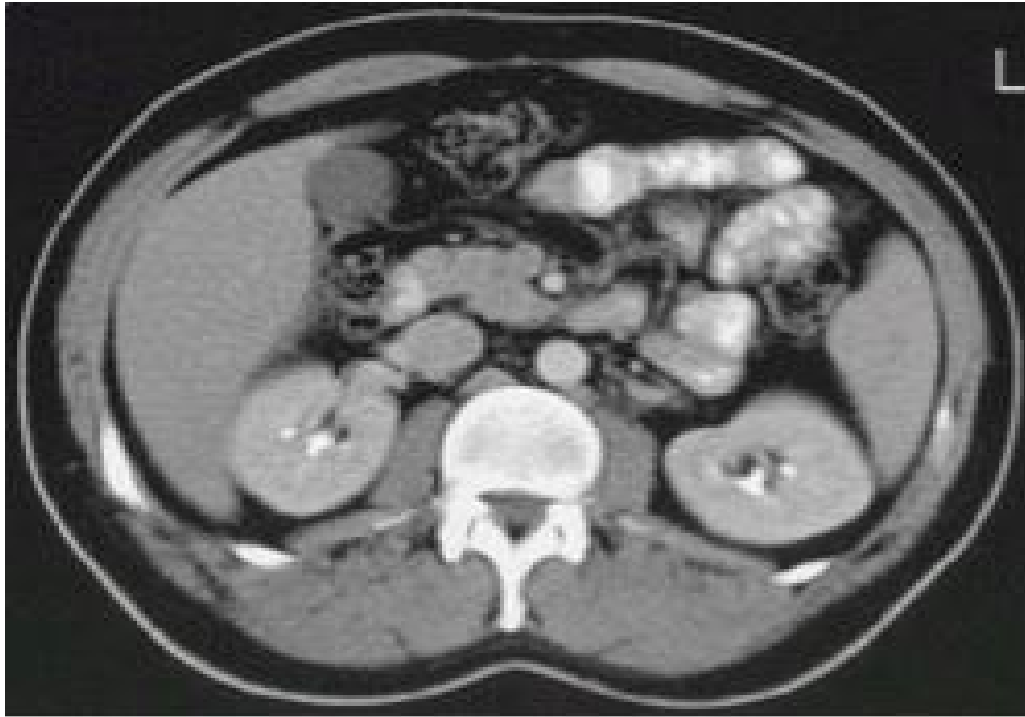


Fig. 2. Control scanner after 21 days

3. DISCUSSION

Submucosal hematoma of the ureter is an unrecognized complication of anticoagulants. To our knowledge, less than ten cases have been described in the literature but probably underestimated [2]. These hematomas are symptomatic in the majority of cases with lower back or abdominal pain associated with macroscopic hematuria. They can also occur in the absence of biological overdose. In imaging, the scanner with and without injection of contrast product is the most efficient technique for demonstrating a pyelic or ureteral parietal hematoma. It should be performed in the presence of any hematuria in a patient on oral anticoagulant therapy, looking for an organic cause which is present in more than three quarters of cases. Signs observed are parietal thickening, uni or bilateral, regular or not, of the pylon and the proximal ureter, associated with infiltration of perirenal, peri-ureteral fat and perirenal fascia [4]. Depending on the degree of obstruction, a dilation of the pyelocaliceal cavities, or even an excretory delay, can be demonstrated [2]. A clinical and iconographic evolution, favorable in three to four weeks, after correction of hemostasis disorders, is a strong argument in favor of the diagnosis [4]. The

pathophysiology is not known. By analogy with segmental hematoma of the intestine, we may assume that hematic infiltration occurs in the connective chorion and muscularis, then gradually spreads due to ureteral peristalsis [4-6].

4. CONCLUSION

The parietal hematoma of the ureter is an exceptionally reported, but probably underestimated, complication of anticoagulants. Along with other abdominal bleeding complications better known of these treatments, it deserves to be mentioned in any patient on anticoagulants presenting with hematuria and unexplained low back pain or abdominal pain syndrome, even in the absence of clear biological overdose.

CONSENT

All authors declare that written informed consent was obtained from the patient for publication of this case report and accompanying images.

ETHICAL APPROVAL

It is not applicable.

COMPETING INTERESTS

Authors have declared that no competing interests exist.

REFERENCES

1. Van Savage JG, Fried FA. Anticoagulant associated hematuria: A prospective study. J Urol. 1995;153(5):1594-6.
2. Kolko A, Kiselman R, Russ G, Bacques O, Kleinknecht D. Acute renal failure due to bilateral ureteral hematomas complicating anticoagulant therapy. Nephron. 1993;65: 165-6.
3. Velut JG, Bagneres D, Portier F, Bagatini S, Demoux AL. Hématome de l'uretère sur un traitement par anticoagulant : Rev Med Interne. 2000;21:903-10. French.
4. Belliol E, Richez P, Barea D, Raillat A, Tomasini P, Agostini S, et al. Hématomes urétéraux compliquant un traitement anticoagulant. J Radiol. 1998;79:49-51.
5. Monib S, Ritchie A, Thabet E. Idiopathic Retroperitoneal hematoma. J Surg Tech Case Rep. 2011;3(1):49-51.
6. Wang F, Wang F. The diagnosis and treatment of traumatic retroperitoneal hematoma. Pak J Med Sci. 2013;29(2): 573-6.

© 2021 Houssame et al.; This is an Open Access article distributed under the terms of the Creative Commons Attribution License (<http://creativecommons.org/licenses/by/4.0>), which permits unrestricted use, distribution, and reproduction in any medium, provided the original work is properly cited.

Peer-review history:

*The peer review history for this paper can be accessed here:
<http://www.sdiarticle4.com/review-history/66698>*