

Significant Bilateral Calcification over a Neglected Ureteral Stent: About a Case Managed Endoscopically

Nedjim A. Saleh^{1*}, Ghannam Youssef¹, Abdi El Mostapha¹,
Nachid Abdellah¹, Ait Mahanna Hamza¹, Moataz Amine¹,
Dakir Mohamed¹, Debbagh Adil¹ and Aboutaieb Rachid¹

¹Urology Department, CHU Ibn Rochd and Faculty of Medicine and Pharmacy, Casablanca, Morocco.

Authors' contributions

This work was a collaborative effort between all authors. Author NAS contributed to all phases of the article: from conception to publication. Authors NAS, GY, AEM contributed to the writing. Authors NA and AMH managed the layout and translation. Authors AM, DM, DA, and AR managed the proofreading and editing. All authors read and approved the final manuscript.

Article Information

Editor(s):

(1) Dr.Ahmet Tahra, Istanbul Medeniyet University, Turkey.

Reviewers:

(1) Dmytro Shevchuk, Zhytomyr State University, Ukraine.

(2) Pradnya Nilesh Jagtap, Savitribai Phule Pune University, India.

(3) Ghaith Qsous, St. Vincent's University Hospital, Ireland.

Complete Peer review History: <http://www.sdiarticle4.com/review-history/68121>

Case Study

Received 25 February 2021

Accepted 02 May 2021

Published 25 May 2021

ABSTRACT

Ureteral stents are integral parts of many procedures in endo-urology. Neglected stents can be associated with significant complications like serious encrustations, stone formation, recurrent urinary tract infections and hematuria. One of the known complications that poses a huge challenge to the urologist to manage is Calcification. The main risk factors for calcification of this stent are low education, time of use, sepsis, pyelonephritis, chronic kidney disease, recurrent or residual kidney stones, congenital and metabolic abnormalities, and malignant ureteral obstruction due to hyperuricosuria and chemotherapy. When removal by cystoscopy is not possible due to calcification, another procedure is required. We are reporting a case of significant bilateral double J-stent calcification in a 33-year-old patient who had kept bilateral double J stents placed for lithiasis for 3 years. Bilateral low back pain associated with hematuria was the main presenting complaints. biologically the renal function was normal. The CT scan revealed calcified bilateral

*Corresponding author: Email: nedjimsaleh@gmail.com;

double J probes along their entire length. The management was endoscopic in two sessions consisting of laser fragmentation of the calcifications and removal of the fragmented ureteral stent. Post-operative follow-up was simple.

Keywords: Urolithiasis; double J ureteral stent; complication; endo-urology.

1. INTRODUCTION

Ureteral stents are integral parts of many procedures in endo-urology [1]. Many factors can lead to forgetfulness or neglecting of indwelling ureteral stent, and this can lead to complications resulting in many morbidities and mortalities. These complications can be incrustations, large stone formation, recurrent urinary tract infections and hematuria [2]. The management of severely calcified stents can be very challenging for the urologist. Management may involve extracorporeal shock wave lithotripsy, endo- urological surgery or open surgery, or a combination of the above techniques [3]. The authors report a case of significant bilateral double j ureteral stents calcification within 3 years with successful endoscopic management.

2. CASE REPORT

A 33 years old man, without any known comorbidity, in whom a surgical cure of right renal staghorn calculus was performed 3 years ago with the insertion of a double J ureteral stent

(one for the surgical cure of right renal staghorn calculus and the other was inserted to prepare for a left ureteroscopic lithotripsy).

The patient remained out of sight. 3 years later, he came with bilateral low back pain without fever associated with hematuria. The clinical examination revealed a patient in good general condition, hemodynamically stable. Temperature was 37.1 C. Bilateral lumbar pain on palpation. An unprepared urinary tree x-ray and the uroscan showed calcified bilateral double J stents along their entire length (Fig. 1). Urine analysis was sterile. The diagnosis of calcification of the bilateral double J ureteral stent was made. Management was by endoscopic approach in two sessions. The first step consisted of laser fragmentation of the distal loops (in the bladder) and right side double- J stenting (Figs. 2). The second step consisted of fragmentation of the left sided lithiasis. The postoperative follow-up was simple. After grooming (Fig. 3), lithiasis remains at the renal level, an endoscopic management is planned.

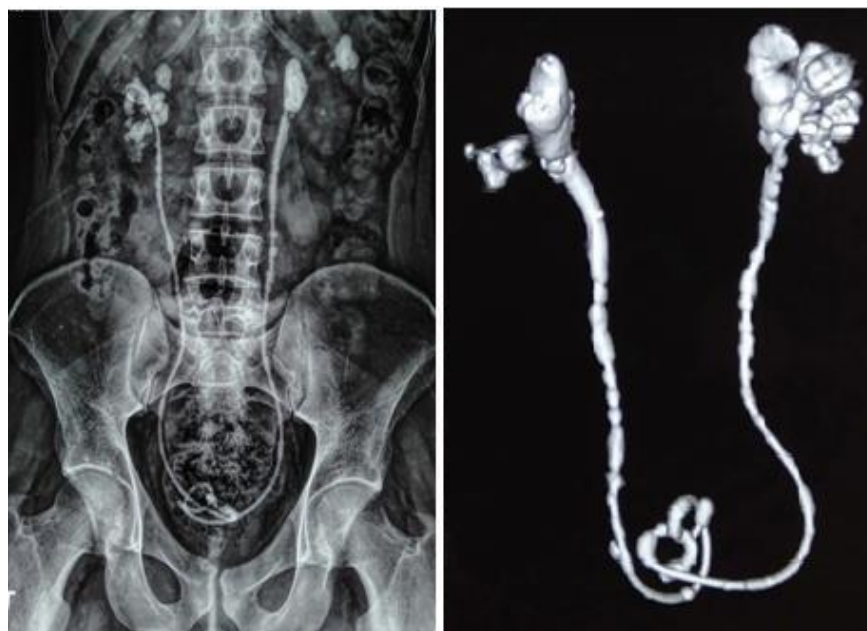

Fig. 1. Calcified double J ureteral stent

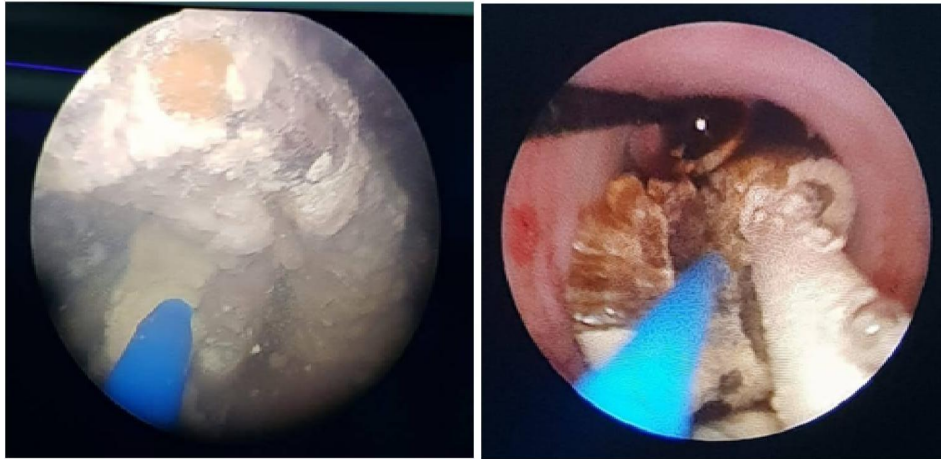


Fig. 2. Fragmentation at the vesical and ureteral area

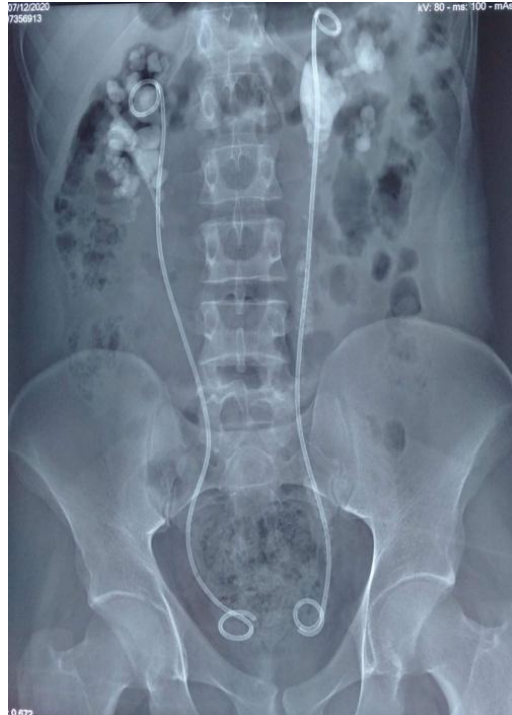

Fig. 3. Insertion of double J bilateral stent after fragmentation

3. DISCUSSION

Double-J stents are widely used in urological practice for a variety of reasons. The removal of these stents can sometimes be forgotten [4]. If forgotten or neglected, can be associated with complications like serious encrustations, formation of large stones, recurrent urinary tract infections and hematuria [2]. Calcification of the double-J stent is a common complication with

a high rate of patient morbidity, requiring additional surgery and a consequent increase in financial expenses [5]. We are reporting a 33-year-old case of bilateral double J stent complicated by extensive calcification.

The main risk factors for the calcification of these stent are low education, time of use, sepsis, pyelonephritis, chronic kidney disease, recurrent or residual kidney stones,

congenital and metabolic abnormalities, and malignant ureteral obstruction due to chemotherapy with hyperuricosuria [6]. Four of these factors were noted in our patient (low education, time of use, recurrent or residual kidney stones, metabolic abnormalities).

Damiano et al. observed [2] flank pain in 25.3% of cases, irritative signs of lower tract in 18.8%, hematuria in 18.1%, fever in 12.3% of cases and stent migration in 9.5% of cases. The manifestations are diverse and lead to a variable morbi-mortality. In our case, the patient complained of low back pain and hematuria. The hematuria could be explained by bladder irritation by the distal loop of the calcified stent. No fever or urinary tract infection was noted.

When removal by cystoscopy is not possible due to calcification, another procedure is necessary [7]. The management of complicated ureteral stents requires a combination of medical, endourological and/or open surgical techniques. Complications related to JJ stents are mainly managed by endoscopic procedures with a high success rate. Open or laparoscopic surgery is indicated only if endoscopic techniques failed. In case of a non-functioning kidney, a nephrectomy may be indicated [8]. Kandemir et al reported a case of severe calcification whose management was multimodal (using several techniques) [9]. This testifies to the lack of a standard protocol and each case may be managed differently depending on the level of equipment and experience of each urologist. In our current case, endoscopy (cysto-ureteroscopy) combined with laser allowed a complete fragmentation of the calcifications. The removal was easy after fragmentation.

4. CONCLUSION

The urologist must communicate clearly with the patient about the presence of the stents and their risks in case of negligence or forgetfulness to avoid complications. Beyond morbidities, neglected double J-stents pose a management challenge for the urologist and a financial problem for the patient.

CONSENT

As per international standard or university standard, parents written consent has been collected and preserved by the author(s).

ETHICAL APPROVAL

As per international standard or university standard written ethical approval has been collected and preserved by the author(s).

COMPETING INTERESTS

Authors have declared that no competing interests exist.

REFERENCES

1. Monga M, Klein E, Castaneda-Zuniga WR, Thomas R. The forgotten indwelling ureteral stent: A urological dilemma. *The Journal of Urology*. 1995;153(6):1817-1819.
2. Damiano R, Oliva A, Esposito C, De Sio M, Autorino R, D'Armiento M. Early and late complications of double pigtail ureteral stent. *Urologia Internationalis*. 2002;69(2): 136-140.
3. Pais Jr VM, Chew B, Shaw O, Hyams ES, Matlaga B, Venkatesh R, et al. Percutaneous nephrolithotomy for removal of encrusted ureteral stents: A multicenter study. *Journal of Endourology*.2014;28(10):1188-1191.
4. Polat H, Yücel MÖ, Utangaç MM, Benlioğlu C, Gök A, Çift A, et al. Management of forgotten ureteral stents: Relationship between indwelling time and required treatment approaches. *Balkan Medical Journal*. 2017;34(4):301.
5. Polotto PP, Fantin JPP, Padilha TL, Arruda JG, Arruda PF, Gatti M, et al. Computerized system for online control of ureteral catheters hosted on google drive: An alert tool. *International Journal of Sciences*. 2017; 3(09):79-81.
6. Singh I, Gupta NP, Hemal AK, Aron M, Seth A, Dogra, PN. Severely encrusted polyurethane ureteral stents: Management and analysis of potential risk factors. *Urology*. 2001;58(4): 526-531.
7. Vanderbrink BA, Rastinehad AR, Ost MC, Smith AD. Encrusted urinary stents: Evaluation and endourologic management. *Journal of Endourology*. 2008;22(5):905- 912.
8. Ray RP, Mahapatra RS, Mondal PP, Pal DK. Long-term complications of JJ

- stent and its management: A 5 ureteral double-J stent forgotten for 11
years review. Urology Annals. 2015; years through multimodal endourological
7(1):41. methods. Urology Annals.
9. Kandemir A, Sönmez MG. Treatment of 2019;11(3):310.
fragmented and severely encrusted

© 2021 Saleh et al.; This is an Open Access article distributed under the terms of the Creative Commons Attribution License (<http://creativecommons.org/licenses/by/4.0>), which permits unrestricted use, distribution, and reproduction in any medium, provided the original work is properly cited.

Peer-review history:
The peer review history for this paper can be accessed here:
<http://www.sdiarticle4.com/review-history/68121>