



# Ultrasound PECS 2 Versus Dexmedetomidine Infusion for Pain Management after Radical Mastectomy

Mohamed Ahmed Shoman<sup>a++\*</sup>,  
Mohamed Ahmed Lofty Ibrahim<sup>b#</sup>,  
Ashraf Al-Sayed Al-Zeftawy<sup>b†</sup> and Atteia Gad Ibrahim<sup>b‡</sup>

<sup>a</sup> El-Mahalla General Hospital, El-Gharbeya, Egypt.

<sup>b</sup> Anesthesiology, Surgical Intensive Care and Pain Medicine Department, Faculty of Medicine,  
Tanta University, Tanta, Egypt.

## Authors' contributions

This work was carried out in collaboration among all authors. All authors read and approved the final manuscript.

## Article Information

DOI: 10.9734/JAMMR/2022/v34i244925

## Open Peer Review History:

This journal follows the Advanced Open Peer Review policy. Identity of the Reviewers, Editor(s) and additional Reviewers, peer review comments, different versions of the manuscript, comments of the editors, etc are available here: <https://www.sdiarticle5.com/review-history/95351>

Original Research Article

Received: 26/10/2022

Accepted: 28/12/2022

Published: 29/12/2022

## ABSTRACT

**Background:** Pectoralis-Serratus interfascial plane block is a peripheral block of the thoracic wall that presents analgesia of its anterolateral portion. Dexmedetomidine, a specific  $\alpha$ -2 adrenoceptor agonist, has sedative, anxiolytic, and analgesic properties. The aim of this work was to assess the analgesic safety and efficacy of Pectoralis-Serratus interfascial plane block in contrast with dexmedetomidine infusion for unilateral radical mastectomy.

<sup>++</sup>Anesthesiologist Resident;

<sup>#</sup>Lecturer;

<sup>†</sup>Professor;

<sup>‡</sup>Assistant Professor;

\*Corresponding author: E-mail: mohashoman1989@gmail.com;

**Methods:** This prospective randomized study was carried out on 60 adult patients with American Society of Anaesthesiologists (ASA) physical status I/II scheduled for elective unilateral radical mastectomy. The cases were classified randomly into two equal groups: group I: received ultrasound guided pectoralis serratus interfascial plane block and group II: received dexmedetomidine infusion. All patients were subjected to routine laboratory investigations (coagulation profile, CBC, liver and renal function tests) and visual analogue scale (VAS).

**Results:** Total amount of fentanyl increments, Ramsey sedation score and total analgesic (morphine) consumption in the 1st 24 hours postoperative were significantly decreased in group I contrasted to group II ( $P < 0.001$ ). Time of the first rescue analgesia was significantly increased in group I than group II ( $P < 0.001$ ). Bradycardia was considerably decreased in group I than group II ( $P = 0.026$ ). VAS at rest and at exercise were significantly decreased at 1, 2, 4 and 6 hours in group I than group II ( $P < 0.05$ ).

**Conclusions:** PECS-II blocks are superior to dexmedetomidine infusion provide adequate post-operative analgesia (lower VAS and total analgesic consumption with increased 1st rescue analgesia) with hemodynamic stability. and less complications.

*Keywords: Ultrasound PECS 2; dexmedetomidine infusion; pain management; radical mastectomy.*

## 1. INTRODUCTION

Breast surgery is surprisingly frequent and linked to a higher rate of acute and chronic discomfort. Patients are often middle-aged women [1].

Satisfactory post-operative analgesia prevents unnecessary patient discomfort. It may play a role in decreasing morbidity; postoperative hospital stays and thus the cost. Inadequate postoperative analgesia has harmful physiologic and psychological consequences that increase morbidity and mortality which subsequently delay recovery and the return to daily activity [2].

Numerous localised anaesthetic treatments, such as local anaesthetic wound infiltration [3], intercostal nerve block [4], para vertebral block (PVB) [5], and thoracic epidural analgesia [2] have been presented in the managing of acute post mastectomy pain, with the intention of reducing the adverse effects of general anaesthesia. In 25–60% of patients, chronic pain may develop as a result of these procedures, which produce severe acute discomfort [6].

Pectoralis-Serratus interfascial plane block is a peripheral thoracic wall block that offers analgesia to its anterior-lateral section. It was first described as an alternate to thoracic epidural and PVB in patients having minor breast surgery due to its theoretically superior side-effect profile [7]. Later, then, A modified Pecs or "Pecs II" block has been developed for major breast surgery including the axilla. A selective  $\alpha$ -2 adrenoceptor agonist, dexmedetomidine possesses analgesic, sedative, and anxiolytic effects. Numerous research has examined its

impact in the perioperative phase in terms of its analgesic-sparing and sedative properties [8].

The objective of this work was to assess the analgesic effectiveness and safety of Pectoralis-Serratus interfascial plane block compared to dexmedetomidine infusion for unilateral radical mastectomy.

## 2. MATERIALS AND METHODS

This prospective, randomised trial included 60 adult patients aged 18 to 60 years with ASA physical status I/II planned for elective unilateral radical mastectomy. This study was performed in Tanta University Hospitals from December 2019 to November 2020.

Exclusion criteria were Refusal by the patient, known allergy to anaesthetic medications, pregnancy, bleeding disturbances, history of seizures or any neurological deficit, anatomical disorders, severe cardiovascular, respiratory, renal, hepatic disorders, a stressful airway and low lung compliance, alcohol abuse or history of drug use and chronic pain or regular use of analgesics.

The participants were randomly classified using closed sealed envelopes into two equal groups: group I: exposed to ultrasound guided pectoralis serratus interfascial plane block and group II: subjected to dexmedetomidine infusion.

All patients were subjected to preoperative (Medical and surgical histories, clinical examination, routine laboratory investigations (coagulation profile, CBC, liver and renal function tests) and visual analogue scale (VAS).

## 2.1 Intraoperative

At arrival to the operation room, a 20-gauge cannula was injected on the other side of the operation. Three-lead electrocardiography, pulse oximetry, non-invasive blood pressure and capnography were utilized to screen all cases.

Propofol 2 mg/kg and fentanyl 1 g/kg were used to establish general anaesthesia, followed by cisatracurium 0.15 mg/kg to enable endotracheal intubation. Group I: received pectoral-serratus interfacial block.

PECS block was done using portable ultrasound Philips device, with a linear probe after sterilization of the infraclavicular and axillary sections with chlorhexidine. The cases were lying in the supine with the ipsilateral upper limb abducted. The PECS II block is intended to achieve the lateral border of the pectoralis minor muscle (Pmm) between the 2<sup>nd</sup>, 3<sup>rd</sup>, and 4<sup>th</sup> rib. The probe was positioned below the clavicle lateral third; after finding the axillary artery and vein, the ribs were counted; from the 1<sup>st</sup> rib beneath the axillary artery, the probe was pushed distally and laterally until it reached the lateral boundary of the Pmm; another muscle covering the 2<sup>nd</sup>, 3<sup>rd</sup>, and 4<sup>th</sup> ribs is the serratus anterior muscle, with this point being the axilla entrance. After applying 3 mL of lidocaine 1% to the skin at the puncture site, the needle was put in the fascial plane between the pectoralis minor muscle and serratus anterior muscle over the 4<sup>th</sup> rib, and 30 mL of bupivacaine 0.25% was administered in 5 mL increments.

Group II: received dexmedetomidine (Precedex<sup>®</sup>, Abbot Laboratories Inc., Abbot Park, IL, USA) intravenous infusion which began with a dosage of 1 g/kg in 20 ml saline for 10 minutes prior to the incision of the skin, and then remained as an infusion of 0.2g/kg/h until the operation ended.

Anaesthesia was preserved with isoflurane in oxygen 50% to keep bispectral index between 40-60 and cisatracurium 0.03 mg/kg on demand.

MAP and heart rate were kept within 20% of preoperative baseline levels by administering 0.5 µg/kg bolus doses of fentanyl intravenously (IV) whenever MAP or heart rate rose by more than 20% from baseline, increment of cisatracurium 1mg was given. Patients were mechanically ventilated, and the parameters were adjusted to keep EtCO<sub>2</sub> between 35-45 mmHg.

After the operation was ended (closing of the skin incision), the anaesthetic procedure was

stopped. After restoring spontaneous breathing, muscle relaxants were reversed with 0.04–0.08 mg/kg of neostigmine and atropine (0.02 mg/kg). The suction and endotracheal extubating were done.

Postoperative: the cases were transported to the postanesthetic care unit (PACU) for a 2-hour observation period then were transferred to the ward. All patients received diclofenac sodium 75 mg intramuscularly every 12 hours as a fixed analgesic regimen. VAS was measured directly post-operative and at 1, 2, 4, 6, 12 and 24 hours. Morphine 3 mg IV was given when VAS at rest is 4 or more followed by 1 mg bolus with lockout interval 20 minutes.

The first end point was time of the first rescue analgesia and total analgesic consumption in the first 24 hours. The second end point was the development of chronic pain.

## 2.2 Sample Size Calculation

Using the WHO and Centres for Disease Control and Prevention (CDC)-designed Epi-Info 2002 software statistical tool, the sample size was determined. The sample size was determined based on the hypothesis that 27 cases per group were required to detect a 35% decrease in 24-hour morphine intake at a 5% significance level with 80% power. To eliminate bias caused by patient dropout, 10% was added to the patient number, resulting in the recruitment of 30 patients each group.

## 2.3 Statistical Analysis

SPSS v25 (IBM, Chicago, IL, USA) was used for data organisation, tabulation, presentation, and analysis. Using the Shapiro-Wilks test and histograms, the (non-)parametric normality of the data was determined. As the mean and standard deviation, quantitative parametric variables (such as age) were shown (SD). The unpaired student's t-test was used to compare two groups, whereas the paired T test was used to compare data within a single group. Quantitative non-parametric variables (e.g., VAS) were provided as median and range, compared between the two groups using the Mann Whitney (U) test, and compared within the same group using the Wilcoxon test. Qualitative variables (such as sex) were represented as frequency and percentage and analysed using the Chi-square test or Fisher's exact test, as appropriate. A two-tailed P value of 0.05 was considered statistically significant.

### 3. RESULTS

Patients' characteristics as age, BMI, ASA, surgery period and anaesthetic duration were insignificantly different between both groups Table 1.

Heart rate and MAP were considerably increased at T2, T3, T4, T5, T6, T7, T8, T9, TX and TY in group I compared to group II ( $P < 0.001$ ) and was insignificantly different in both groups at T0 and T1 Fig. 1.

Mean end tidal isoflurane concentration was insignificantly different between both groups. Total amount of fentanyl increments, Ramsey sedation score and total consumption of analgesic (morphine) in the 1st 24h postoperative were significantly reduced in group I compared to group II ( $P < 0.001$ ). Time of the first rescue analgesia was considerably increased in group I than group II ( $P < 0.001$ ) Fig. 2.

Chronic pain with movement and at rest after 6 months (throbbing, aching, tender, troublesome, burning and stabbing or bricking) was insignificantly different between both groups. Bradycardia was significantly decreased in group I contrasted to group II ( $P = 0.026$ ) while hypotension and PONV were inconsiderably varied between both groups Table 2.

VAS at rest and at exercise were significantly decreased at 1, 2, 4 and 6 hours in group I in comparison to group II ( $P < 0.05$ ) and was insignificantly different between both groups at 12, 18 and 24 hours Table 3.

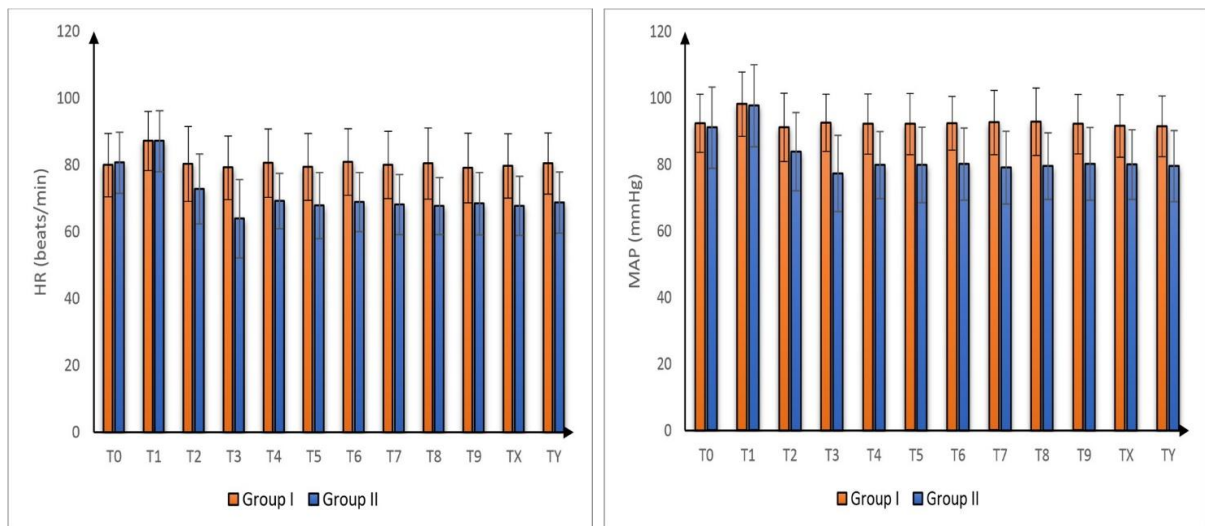
### 4. DISCUSSION

Intraoperative administration of dexmedetomidine that is a specific alpha-2 adrenergic agonist for general anaesthesia that enhance the analgesic efficacy of PCA morphine and minimise morphine intake and associated side effects [9].

**Table 1. Patients' characteristics in both studied groups**

	Group I (n = 30)	Group II (n = 30)	P value
Age (years)	45.6 ± 6.49	46.6 ± 5.96	0.537
BMI (Kg/m <sup>2</sup> )	32.9 ± 3.78	31.7 ± 4.17	0.243
ASA	ASA I	19 (54.3%)	0.598
	ASA II	11 (31.4%)	
Duration of Surgery (min)	124.8 ± 16.05	128.7 ± 18.38	0.393
Duration of anesthesia (min)	138.3 ± 15.83	144.2 ± 19.03	0.202

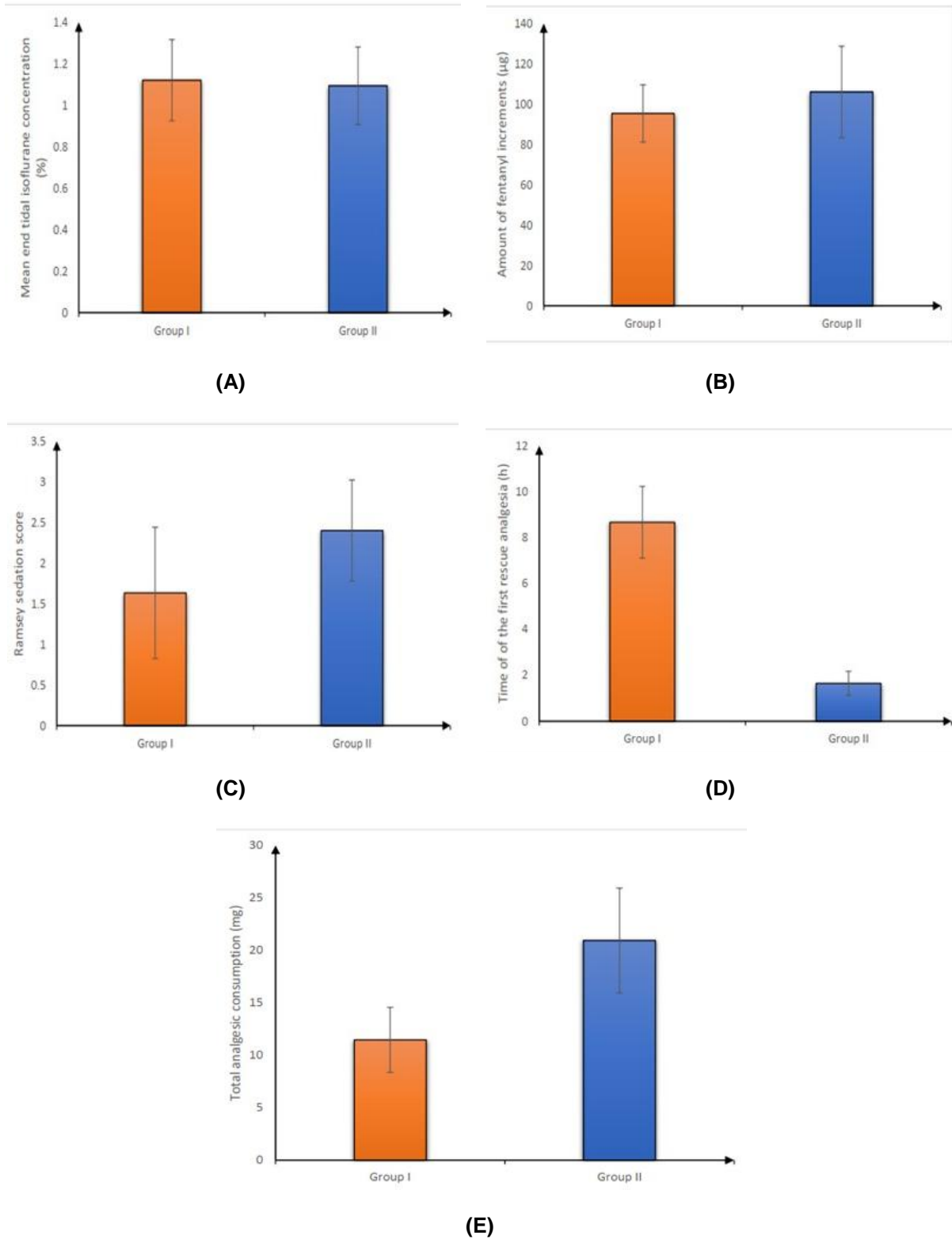
Data are presented as mean ± SD or frequency (%). BMI: Body Mass Index



(A)

(B)

**Fig. 1. (A) Heart rate and (B) MAP in both groups**



**Fig. 2. (A) mean end tidal isoflurane concentration, (B) amount of fentanyl increments, (C) Ramsey sedation score, (D) time of the first rescue analgesia and (E) total analgesic consumption in both groups**

**Table 2. Chronic pain with movement, at rest after 6 months and adverse effects in both studied groups**

	Group I (n = 30)	Group II (n = 30)	P value
<b>Throbbing</b>	2	2	1
<b>Aching</b>	3	6	0.472
<b>Tender</b>	5	9	0.222
<b>Troublesome</b>	4	4	1
<b>Burning</b>	5	6	0.739
<b>Stabbing or bricking</b>	8	9	0.775
<b>Chronic pain at rest after 6 months</b>			
<b>Throbbing</b>	1 (3.3%)	1 (3.3%)	1
<b>Aching</b>	2 (6.7%)	4 (13.3%)	0.671
<b>Tender</b>	5 (16.7%)	7 (23.3%)	0.519
<b>Troublesome</b>	2 (6.7%)	2 (6.7%)	1
<b>Burning</b>	3 (10%)	4 (13.3%)	1
<b>Stabbing or bricking</b>	6 (20%)	8 (26.7%)	0.542
<b>Adverse effects</b>			
<b>Bradycardia</b>	1 (3%)	8 (27%)	0.026*
<b>Hypotension</b>	1 (3%)	5 (17%)	0.195
<b>PONV</b>	14 (47%)	11 (37%)	0.432

Data are represented as frequency (%) \*Significant as P value <0.05, PONV: Post-operative nausea vomiting

**Table 3. VAS at rest and at exercise in both studied groups**

		1h	2h	4h	6h	12h	18h	24h
<b>Group I (n = 30)</b>	<b>Median</b>	1.5	1.5	1.5	2.0	3.5	4.0	4.0
	<b>IQR</b>	1-2	1-2	0.25-2	1-3	3-4.75	3-5	3-6
<b>Group II (n = 30)</b>	<b>Median</b>	2.0	2.5	3.0	4.0	5.0	4.0	4.0
	<b>IQR</b>	2-3	1-3	2-4	3-5	2.25-5.75	3-5	3-5
<b>P value</b>		0.019*	0.011*	<0.001*	<0.001*	0.146	0.342	0.750
<b>At exercise</b>								
<b>Group I (n = 30)</b>	<b>Median</b>	2.0	2.5	2.0	2.5	4.0	4.0	5.0
	<b>IQR</b>	1-3	2-3	1-3	2-4	3-5	4-5	3-6
<b>Group II (n = 30)</b>	<b>Median</b>	4.0	3.0	3.5	5.0	5.0	5.0	5.0
	<b>IQR</b>	3-4.75	2-5	3-5	4-6	3.25-6	4-6	4-6
<b>P value</b>		<0.001*	0.025*	<0.001*	<0.001*	0.047*	0.095	0.739

\*Significant as P value <0.05, VAS: Visual analogues skill

Regarding to heart rate, MAP and hemodynamic changes was a significant increase was recorded at T2, T3, T4, T5, T6, T7, T8, T9, TX and TY in both groups (P <0.001) and was insignificantly varied between both groups at T0 and T1.

In agreement to our results, Alzeftawy et al. [10] 76 female patients receiving radical mastectomy were analyzed. Patients were categorized randomly into two groups: group I got intraoperative dexmedetomidine infusion, while group II, the control group, received normal saline infusion. They discovered a substantial drop in MAP and pulse rate in group I begin one minute after skin incision.

Regarding to mean end tidal isoflurane concentration were insignificantly different between both groups.

In agreement to our results, Jain et al. [11] evaluated 86 cases undergoing breast cancer surgery who were allocated randomly into two groups, group D receiving dexmedetomidine (2 g/ml) and group C receiving saline. They discovered that intraoperative isoflurane use was considerably decreased in Group D than in Group C.

Regarding to VAS at rest and exercise were significantly decreased at 1, 2, 4 and 6 hours in group I than group II (P = 0.019, 0.011, <0.001 and <0.001 respectively) and was insignificantly different between both groups at 12, 18 and 24 hours.

In agreement to our results, Grasso et al. [12] involved patients arranged for unilateral modified radical mastectomy Pecs group: general

anesthesia with ultrasound-guided modified pectoral nerve blocks type I and II, incorporating serratus and parasternal infiltration based on surgical needs; and control group: General anesthesia alone. They demonstrated significant reductions in pain scores 24 h after surgery.

In contrast to our results, Sitilci et al. [13] evaluated 40 patients scheduled for mastoidectomy operation. Patients were categorized into two groups as group Dexmedetomidine and group Placebo. They demonstrated that mean VAS was decreased in Dexmedetomidine group than control group.

In our study, time of first rescue analgesia was increased, and total postoperative analgesic consumption was considerably diminished in group I as contrasted to group II.

In agreement to our results, Kulhari et al. [14] The effectiveness and safety of ultrasound-guided PecS II block vs thoracic PVB for postoperative analgesia after modified radical mastectomy were compared. They revealed that the analgesic period was considerably prolonged in patients undergoing the PECS II block compared to the TPVB, that the 24 h morphine consumption was also decreased in the PECS II block group, and that postoperative pain scores were decreased in the PECS II group compared to the TVPB group in the initial 2 h after surgery. They found that the PECS II block offered effective postoperative analgesia without side effects in patients having modified radical mastectomy.

In contrary to our results Jain et al. [11] found that the consumption of analgesics postoperatively was significantly lower in dexmedetomidine group.

Regarding to post-operative complications, bradycardia was significantly decreased in group I than group II ( $P = 0.026$ ) while hypotension and PONV were insignificantly different between both groups.

In accordance with our results Tripathy et al. [15] who evaluate 58 ASA I-III adult patients were referred for MRM. Patients were induced with propofol and kept on spontaneous breathing with isoflurane (0.8-1.0 MAC) using i-gel after randomization. PECS or PV blocks were delivered using ultrasound guidance (30 cc of 0.1% lignocaine + 0.25% bupivacaine + 1 g/kg dexmedetomidine). Researchers discovered that

PECS inhibit extended analgesia and eliminate the need for opiate analgesics intra- and post-operatively.

In contrast to our results, Grasso et al. [12] demonstrated that significant reductions in post-operative nausea and vomiting were detected in the Pecs group in comparison to controls.

Regarding to chronic pain at rest and with movement after 6 months (throbbing, aching, tender, troublesome, burning and stabbing or bricking) were insignificantly different between both groups.

In accordance with our results, Alzeftawy et al. [10] found that pain scores at 6 months were comparable in dexmedetomidine and control groups.

In contrary to our results Jain et al. [11] discovered that dexmedetomidine infusions pre and postoperatively had a significant impact in reducing postoperative pain and enhancing quality of life for patients having breast cancer surgery.

The current study recommends using ultrasound-guided PECS-II blocks is superior to intravenous (IV) dexmedetomidine in patients undergoing MRM. Additional studies with a large number of patients are recommended for generalization of these findings. Also, further research is required to assess adding bupivacaine in different concentrations by ultrasound-guided PECS II.

## 5. CONCLUSION

PECS-II blocks are superior to dexmedetomidine infusion provide adequate post-operative analgesia (lower VAS and total analgesic consumption with increased 1st rescue analgesia) with hemodynamic stability and less complications.

## CONSENT AND ETHICAL APPROVAL

Informed written consent was acquired from the cases. The study was approved from the Ethical Committee Tanta University (approval code: 33380/9/19).

## COMPETING INTERESTS

Authors have declared that no competing interests exist.

## REFERENCES

1. Andersen KG, Kehlet H. Persistent pain after breast cancer treatment: A critical review of risk factors and strategies for prevention. *J Pain*. 2011; 12:725-46.
2. Abdel-Mo`men MA, Elkhateeb SEM, Abdel-Ra`oof HS, Mohamed MAE. Comparative study between ultrasound guided Pectoral nerves block and thoracic epidural as analgesia in breast surgeries. *Egypt J Hosp Med*. 2018;72: 5304-12.
3. Fassoulaki A, Sarantopoulos C, Melemeni A, Hogan Q. Regional block and mexiletine: The effect on pain after cancer breast surgery. *Reg Anesth Pain Med*. 2001;26:223-8.
4. Kairaluoma PM, Bachmann MS, Rosenberg PH, Pere PJ. Preincisional paravertebral block reduces the prevalence of chronic pain after breast surgery. *Anesth Analg*. 2006;103:703-8.
5. Gadsden J, Warlick A. Regional anesthesia for the trauma patient: Improving patient outcomes. *Local Reg Anesth*. 2015;8:45-55.
6. Belzarena SD. Comparative study between thoracic epidural block and general anesthesia for oncologic mastectomy. *Rev Bras Anesthesiol*. 2008;58:561-8.
7. Blanco R. The 'pecc block': a novel technique for providing analgesia after breast surgery. *Anaesthesia*. 2011;66:847-8.
8. Gurbet A, Basagan-Mogol E, Turker G, Ugun F, Kaya FN, Ozcan B. Intraoperative infusion of dexmedetomidine reduces perioperative analgesic requirements. *Can J Anaesth*. 2006;53:646-52.
9. Zhao JN, Kong M, Qi B, Ge DJ. Comparison of the morphine-sparing effect of intraoperative dexmedetomidine with and without loading dose following general anesthesia in multiple-fracture patients: A prospective, randomized, controlled clinical trial. *Medicine (Baltimore)*. 2016;95:e4576.
10. Alzeftawy AE, Elsheikh NA. Evaluation of the efficacy of dexmedetomidine infusion on the quality of balanced anesthesia and postmastectomy pain. *Res Opin Anesth Intensive Care*. 2015;2:73-8.
11. Jain G, Bansal P, Ahmad B, Singh DK, Yadav G. Effect of the perioperative infusion of dexmedetomidine on chronic pain after breast surgery. *Indian J Palliat Care*. 2012;18:45-51.
12. Grasso A, Orsaria P, Costa F, D'Avino V, Caredda E, Hazboun A, et al. Ultrasound-guided interfascial plane blocks for non-anesthesiologists in breast cancer surgery: Functional outcomes and benefits. *Anticancer Res*. 2020;40:2231-8.
13. Sitalci AT, Ozyuvacı E, Alkan Z, Demirgan S, Yiğit O. The effect of perioperative infused dexmedetomidine on postoperative analgesic consumption in mastoidectomy operations. *Agri*. 2010;22:109-16.
14. Kulhari S, Bharti N, Bala I, Arora S, Singh G. Efficacy of pectoral nerve block versus thoracic paravertebral block for postoperative analgesia after radical mastectomy: A randomized controlled trial†. *BJA*. 2016;117:382-6.
15. Tripathy S, Mandal I, Rao PB, Panda A, Mishra T, Kar M. Opioid-free anesthesia for breast cancer surgery: A comparison of ultrasound guided paravertebral and pectoral nerve blocks. A randomized controlled trial. *J Anaesthesiol Clin Pharmacol*. 2019;35:475-80.

© 2022 Shoman et al.; This is an Open Access article distributed under the terms of the Creative Commons Attribution License (<http://creativecommons.org/licenses/by/4.0>), which permits unrestricted use, distribution, and reproduction in any medium, provided the original work is properly cited.

Peer-review history:

The peer review history for this paper can be accessed here:

<https://www.sdiarticle5.com/review-history/95351>