



Nimesulide Inhibits MAPK/COX-2 Pathway, and Prevents Oxidative Stress, Inflammation, and Apoptosis in Testes of Cisplatin-Challenged Rats

Amr A. Fouad^{1*}, Hanaa M. Khalaf², Usama I. Akl³ and Manal I. Abdelghany⁴

¹Department of Pharmacology, Faculty of Medicine, Al-Baha University, Al-Baha, Saudi Arabia.

²Department of Pharmacology, Faculty of Medicine, Minia University, El-Minia, Egypt.

³Department of Surgery, Faculty of Medicine, Al-Baha University, Al-Baha, Saudi Arabia.

⁴Department of Pathology, Faculty of Medicine, Minia University, El-Minia, Egypt.

Authors' contributions

This work was carried out in collaboration among all authors. Author AF designed the study, performed the statistical analysis, wrote the protocol and wrote the first draft of the manuscript. Authors HK and UA managed the analyses of the study. Author MA managed the literature searches. All authors read and approved the final manuscript.

Article Information

DOI: 10.9734/JPRI/2020/v32i2230769

Editor(s):

(1) Dr. Jongwha Chang, University of Texas, USA.

Reviewers:

(1) Debarshi Kar Mahapatra, Dadasaheb Balpande College of Pharmacy, India.

(2) T. S. Padmanabha, Adichunchanagiri University, India.

(3) Smita More, Savitribai Phule Pune University, India.

(4) Mayank Bansal, Jaipur College of Pharmacy, Rajasthan University of Health Sciences, India.

Complete Peer review History: <http://www.sdiarticle4.com/review-history/60705>

Original Research Article

Received 28 June 2020
Accepted 04 September 2020
Published 12 September 2020

ABSTRACT

The potential testicular protective effect of nimesulide (NSE) was studied in cisplatin (CSP)-challenged rats. NSE therapy (10 mg/kg/day, p.o.) was applied for 15 days, and a single dose of CSP (7 mg/kg, i.p.) was administered on the 10th day. CSP significantly decreased the levels of serum testosterone, testicular reduced glutathione, and superoxide dismutase. CSP also significantly increased testicular malondialdehyde, nitric oxide, tumor necrosis factor- α , interleukin-1 β , cyclooxygenase-2 (COX-2), prostaglandin E₂, nuclear factor-kB p65, Bax, and caspase-3. NSE significantly ameliorated all the biochemical changes observed in CSP-challenged rats. Moreover, NSE significantly reduced the histopathological injury, and the expressions of phosphorylated c-Jun N-terminal kinase (p-JNK) and p38 mitogen-activated protein kinases (MAPKs) in testes of rats

*Corresponding author: E-mail: afouad@bu.edu.sa, amrfouad65@yahoo.com;

received CSP. It was concluded that NSE significantly blocked the CSP-induced acute testicular injury in rats through inhibition of MAPK/COX-2 signaling pathway, and by combating oxidative stress, inflammation, and apoptosis.

Keywords: Nimesulide; cisplatin; MAPK; COX-2; testes.

1. INTRODUCTION

The nitrogen mustard, cisplatin (CSP), is a DNA alkylating cytotoxic compound widely used as an anticancer chemotherapeutic agent for the treatment of various solid and hematological malignancies [1]. Injury and dysfunction of male gonads, suppression of spermatogenesis, and male infertility are well-known adverse impacts of CSP therapy. Oxidative stress, increased generation of reactive oxygen species (ROS), depletion of endogenous antioxidants, and lipid peroxidation of cellular biomembranes are incriminated in the pathogenesis of CSP-induced testicular injury [2]. In addition, CSP-induced oxidative stress causes phosphorylation and activation of c-Jun N-terminal kinase (JNK) and p38 mitogen-activated protein kinases (MAPKs) [3]. Subsequently, the phosphorylated MAPKs activate other proteins, which upon nuclear translocation act as transcriptional factors for many inflammatory and apoptotic biomarkers. Moreover, phosphorylated JNK and p38 MAPKs induce the nuclear factor- κ B (NF- κ B) and cyclooxygenase-2 (COX-2) pathways resulting in increased production of pro-inflammatory mediators, as tumor necrosis factor- α (TNF- α) and interleukin-1 β (IL-1 β), and inflammatory prostaglandins, as prostaglandin E₂ (PGE₂) [4,5]. Eventually, activation of the apoptotic pathways ensues testicular cell death and male infertility [6].

Nimesulide (NSE) is a nonsteroidal anti-inflammatory drug with selective inhibitory action on COX-2. It is approved for the treatment of acute pains, osteoarthritis, and primary dysmenorrhea [7]. It was reported in the literature that NSE provided significant antioxidant, anti-inflammatory, and anti-apoptotic effects in different models [8-11]. Additionally, a recent study showed that NSE significantly protected the testes of rats against ischemia/reperfusion injury resulting from torsion/detorsion [12]. Therefore, NSE potentially can protect against the CSP-induced testicular injury and dysfunction. The present study was done to investigate the possible gonadal conservative effect of NSE in male rats challenged with CSP, and to reveal the possible mechanisms underlying this effect.

2. MATERIALS AND METHODS

2.1 Drugs and Chemicals

NSE and CSP were purchased from Sigma-Aldrich, USA. NSE was prepared in 0.5% carboxymethylcellulose (CMC), and CSP was dissolved in physiological saline. The doses of NSE and CSP used in the current investigation were chosen based on previous studies [10,13].

2.2 Animals and Treatments

Twenty-six male Sprague-Dawley rats, weighing 250 ± 10 g, were obtained from the National Research Centre, Giza, Egypt. They were housed at standard conditions (24°C, 45% humidity, and 12 h light/dark cycle), supplied with ordinary chew and tap water *ad libitum*, and were acclimatized for 7 days. The international guidelines for care and use of laboratory animals were fulfilled.

The rats were assigned randomly into 4 groups as follows:

- Group I ($n = 6$) was the control and received CMC, p.o., daily for 15 days, and a single i.p. injection of physiological saline on the 10th day.
- Group II ($n = 7$) received CMC, p.o., for 15 days, and a single i.p. injection of CSP (7 mg/kg) on the 10th day.
- Group III ($n = 7$) received NSE (10 mg/kg/day, p.o.) for 15 days, and a single i.p. injection of CSP (7 mg/kg) on the 10th day.
- Group IV ($n = 6$) received only NSE (10 mg/kg/day, p.o.) for 15 days, and a single i.p. injection of physiological saline on the 10th day.

2.3 Sampling and Biochemical Investigations

At the end of experiments, rats were euthanized by urethane (1 g/kg, i.p.). Samples of blood were compiled via a cardiac prick, left to clot for 60 min, and then centrifuged at 4000 rpm for 10 min to obtain clear sera. An ELISA kit was utilized to

measure serum testosterone (R&D Systems, USA).

In addition, the testes were dissected out, and the right testes were homogenized in cold potassium phosphate buffer (0.05 M, pH 7.4). The homogenates were centrifuged at 4000 rpm for 10 min at 4°C, and the supernatant was used for biochemical measurements. Colorimetric kits were used for the determination of malondialdehyde (MDA), nitric oxide (NO), reduced glutathione (GSH), and superoxide dismutase (SOD) (Biodiagnostic, Egypt), and caspase-3 (R&D Systems, USA) in the testicular homogenates. Further, ELISA kits were employed to quantify TNF- α , IL-1 β , COX-2 (Elabscience Biotechnology Inc., USA), PGE₂ (R&D Systems, USA), NF- κ B p65 (Novus Biologicals, USA), and Bax (LifeSpan BioSciences, USA) in testicular homogenates.

2.4 Histopathology Investigations

Left testes were fixed in Bouin's solution, alcohol dehydrated, and paraffin-embedded. Five- μ m sections thickness were sliced, and stained with hematoxylin and eosin (H&E). Slides were inspected under a light microscope by a pathologist unaware of slide discrimination.

A testicular injury score using a scale from 0 to 3 to assess seminiferous epithelial injury, tubular necrosis, interstitial edema, and hemorrhages was implemented [14]. Spermatogenesis was assessed by a scale from 1 to 10 (1 = no spermatogenesis, and 10 = normal spermatogenesis) [15].

2.5 Immunohistochemistry Investigations

Sections were deparaffinized, rehydrated, and H₂O₂ in methanol (3%) was utilized to impede endogenous peroxidase. Sections were pre-treated in citrate buffer (pH 6.0, 10 mM) in a microwave, and incubated with rabbit polyclonal antibodies targeting rat phosphorylated c-Jun N-terminal kinase (p-JNK) and p38 MAPKs (ThermoScientific, USA, dilution: 1:200). Sections were incubated with biotinylated goat anti-polyvalent, streptavidin peroxidase, and eventually with the chromogen, DAB. Hematoxylin counterstaining was accomplished, and immunostaining was identified by a light microscope utilizing a digital imaging software program (cellSens, Olympus Corporation, USA) to measure the immunostained area (μ m²) in 5 non-overlapping microscopic domains. The mean

\pm S.E.M. of each group was figured. To obtain negative control, an identical process was employed, however, the primary antibody was exchanged by normal rabbit serum.

2.6 Statistics

Results are shown as mean \pm S.E.M. Data analysis was carried out by one-way ANOVA test pursued by *post hoc* comparisons by Tukey test. GraphPad Prism Software Program (version 6.01) was employed, and the significant level was at $P < 0.05$.

3. RESULTS

3.1 Biochemistry Outcomes

CSP at a single dose of 7 mg/kg, i.p., significantly reduced serum testosterone level ($P < 0.05$) in comparison with the corresponding control value. On the other hand, NSE treatment caused a significant increment of serum testosterone ($P < 0.05$) in rats challenged with CSP (Fig. 1A). CSP also significantly increased MDA, NO, TNF- α , and IL-1 β ($P < 0.05$), and significantly decreased GSH and SOD ($P < 0.05$) in the testes as compared to the corresponding values of the control (Figs. 1B-1D). Contrarily, NSE significantly reduced testicular MDA, NO, TNF- α , and IL-1 β ($P < 0.05$), and significantly elevated testicular GSH and SOD ($P < 0.05$) in rats exposed to CSP insult (Figs. 1B-1D). Moreover, CSP caused significant increments of testicular COX-2, PGE₂, NF- κ B p65, Bax, and caspase-3 ($P < 0.05$) as compared to the corresponding control values (Figs. 1E and 1F). Again, NSE caused significant decrements of COX-2, PGE₂, NF- κ B p65, Bax, and caspase-3 ($P < 0.05$) in the testes of rats challenged with CSP (Figs. 1E and 1F).

3.2 Histopathology Outcomes

CSP insult caused marked distortion of testicular histology, necrosis of seminiferous tubules with desquamation and cytoplasmic vacuolization of the lining epithelium, impairment of spermatogenesis, edema of the interstitium, inflammatory cell infiltration, vascular dilatation and congestion, and hemorrhages (Fig. 2). On the contrary, NSE preserved the normal testicular architecture and prevented CSP-induced injury. Additionally, NSE significantly reduced testicular injury score ($P < 0.05$), and significantly increased spermatogenesis score ($P < 0.05$) in rats received CSP (Fig. 2).

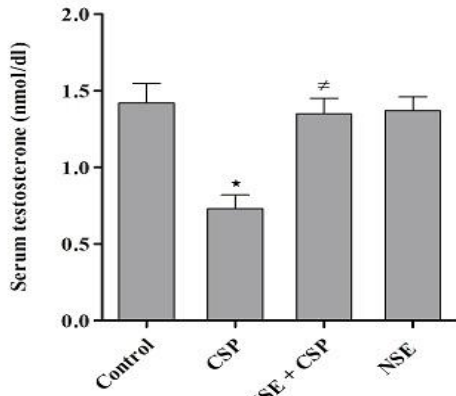


Figure 1A

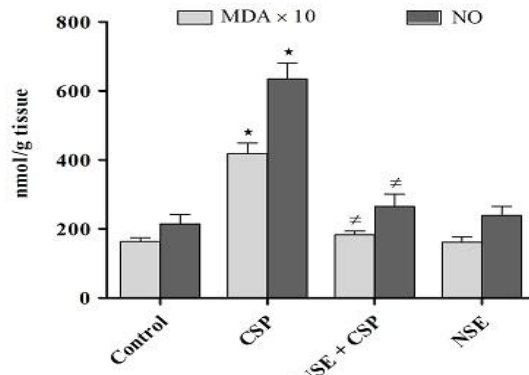


Figure 1B

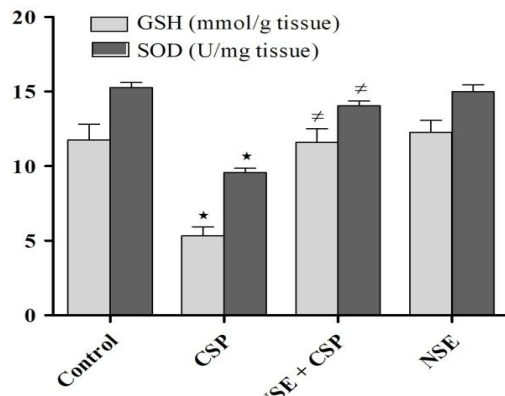


Figure 1C

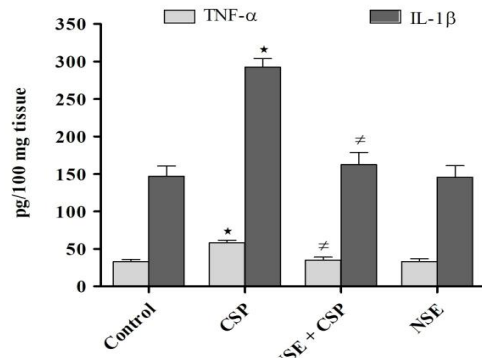


Figure 1D

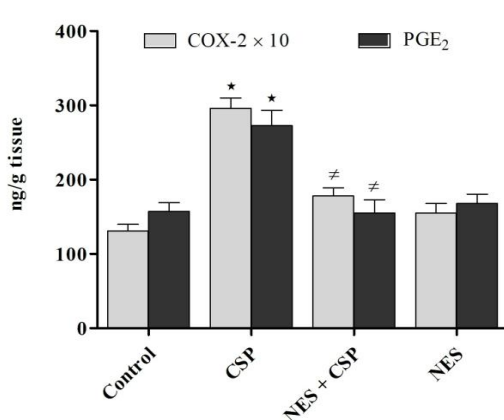


Figure 1E

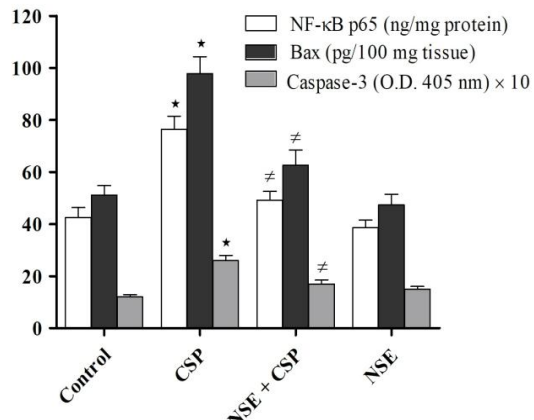


Figure 1F

Fig. 1. Outcomes of nimesulide (NSE) treatment on: (A) serum testosterone; (B) testicular malondialdehyde (MDA) and nitric oxide (NO); (C) testicular reduced glutathione (GSH) and superoxide dismutase (SOD); (D) testicular tumor necrosis factor-α (TNF-α) and interleukin-1β (IL-1β); (E) cyclooxygenase-2 (COX-2) and prostaglandin E₂ (PGE₂); (F) nuclear factor-κB p65 (NF-κB p65), Bax and caspase-3 in cisplatin (CSP)-challenged rats. **P* < 0.05 vs. control, ≠*P* < 0.05 vs. CSP

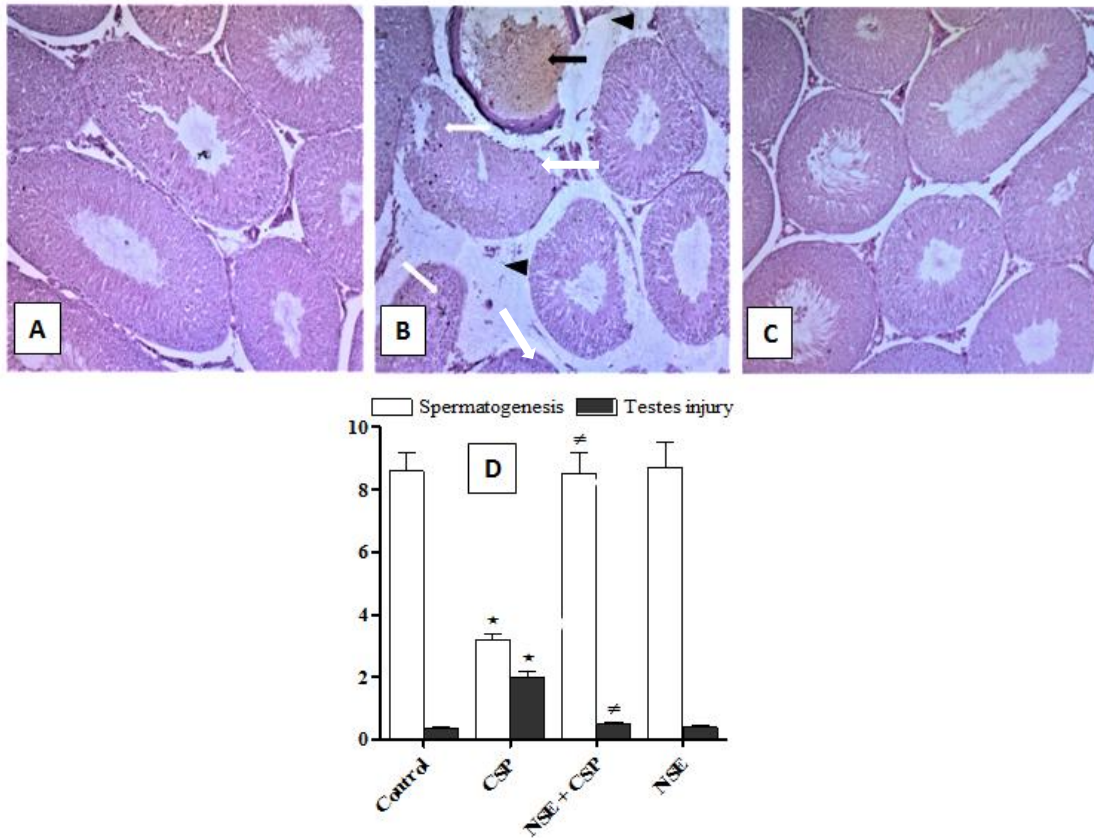


Fig. 2. H&E (200 \times) of rat testes from: (A) control rats displaying normal histology with normal spermatogenesis; (B) cisplatin (CSP) group showing marked distortion of the normal architecture, necrosis, vacuolization, and desquamation of epithelial lining of seminiferous tubules (white arrows), edema of interstetium (black heads), vascular dilatation and congestion (black arrow), and impairment of spermatogenesis. (C) nimesulide (NSE) + CSP demonstrating that normal testicular histology was preserved, and spermatogenesis was maintained; (D) Testicular injury and Johnsen spermatogenesis scores. * $P < 0.05$ vs. control, # $P < 0.05$ vs. CSP

3.3 Immunohistochemistry Outcomes

Significant rises of p-JNK and p38 MAPKs expressions ($P < 0.05$) were observed in the testicular tissue of CSP-challenged rats in comparison with the control rats (Figs. 3 and 4). Again, NSE-treated rats showed significant decrements of testicular p-JNK and p38 MAPKs expressions ($P < 0.05$) as compared to CSP-challenged rats non-treated with NSE (Figs. 3 and 4).

No immunostaining was obtained when the primary antibodies were substituted by normal rabbit serum signifying their specificity (non-included figures).

4. DISCUSSION

Previous studies showed that CSP-induced male gonadal injury and dysfunction emerged via oxidative stress, increased ROS generation, exhaustion of endogenous antioxidants, and enhanced production of MDA, the final outcome of lipid peroxidation of cellular biomembranes [13,16]. Nitrosative stress and increased generation of reactive nitrogen species (RNS), as NO and peroxynitrite radical, were also shown to be involved in the development and progression of CSP-induced testicular toxicity [17]. Moreover, augmented inflammatory responses, boosted production of inflammatory cytokines, induction of COX-2, and increased manufacturing of

inflammatory prostaglandins were incriminated in the pathogenesis of the negative impact of CSP on male gonads [18,19]. This is consistent with the current investigation, in which CSP administration significantly increased the biomarkers of oxidative/nitrosative stress and inflammation, and significantly decreased endogenous antioxidant capacity in rat testes. Besides, it was reported that CSP insult activated the mitochondrial apoptotic pathway with increased production of the pro-apoptotic protein, Bax [20]. The resultant increase of mitochondrial membrane permeability enhances the leakage of cytochrome C from the mitochondria into the cytoplasm. Subsequently, caspase family of proteases is activated, and finally active

caspase-3 executes apoptotic cell death [6,19]. Similarly, the present work showed that CSP administration caused significant increments of Bax and caspase-3 in rat testes.

The selective COX-2 inhibitor, NSE, exerted antioxidant, antinitrosative, anti-inflammatory, and anti-apoptotic properties in different models of tissue injuries, including the testes. Similar to the current study, prior investigations revealed that NSE reduced the production of oxidative/nitrosative stress biomarkers and inflammatory cytokines, preserved the endogenous antioxidants, and prevented the elevations of apoptotic biomarkers [8-12].

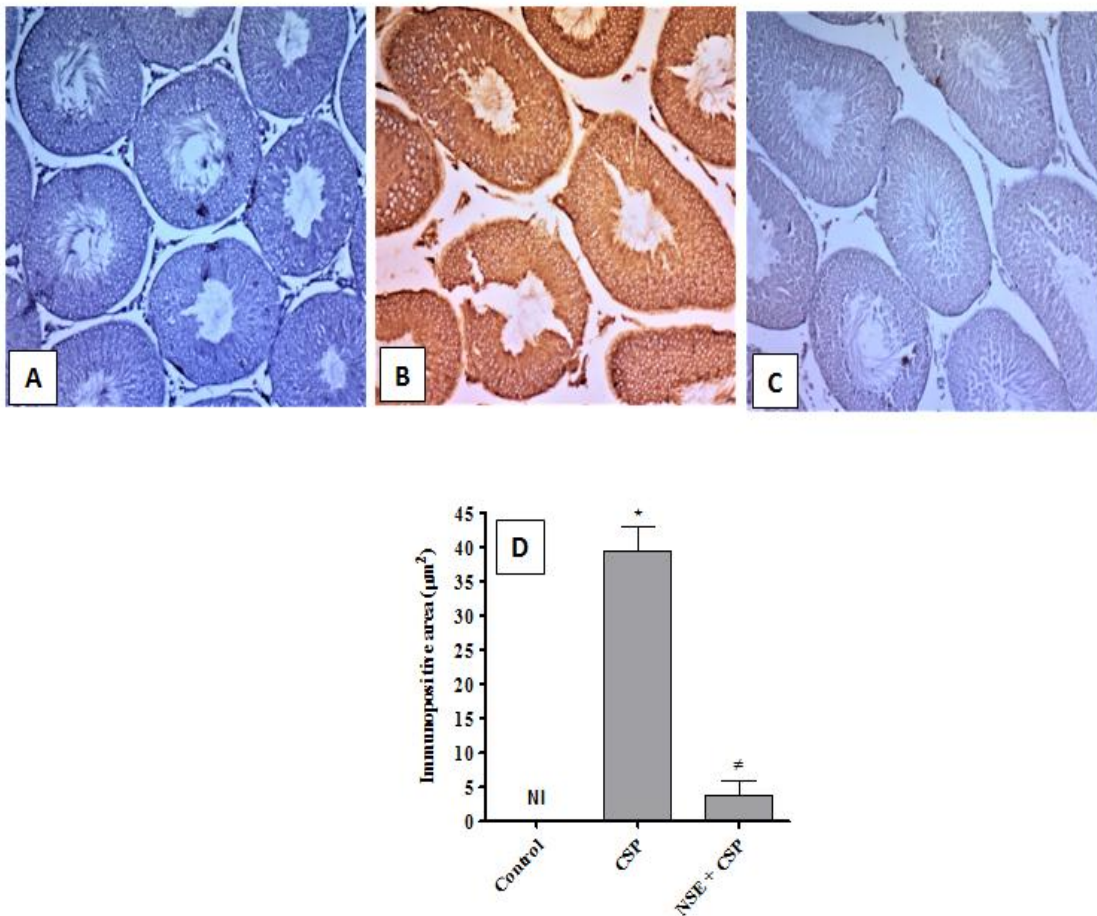


Fig. 3. Immunohistochemistry (200×) of phosphorylated c-Jun N-terminal kinase (p-JNK) in rat testes from (A) control showing no immunostaining (NI); (B) cisplatin (CSP) group showing a significant increment of p-JNK immunoreactivity in brown color; (C) nimesulide (NSE) + CSP showing a significant decrement of p-JNK expression; (D) immunopositive area (µm²). *P < 0.05 vs. control, #P < 0.05 vs. CSP

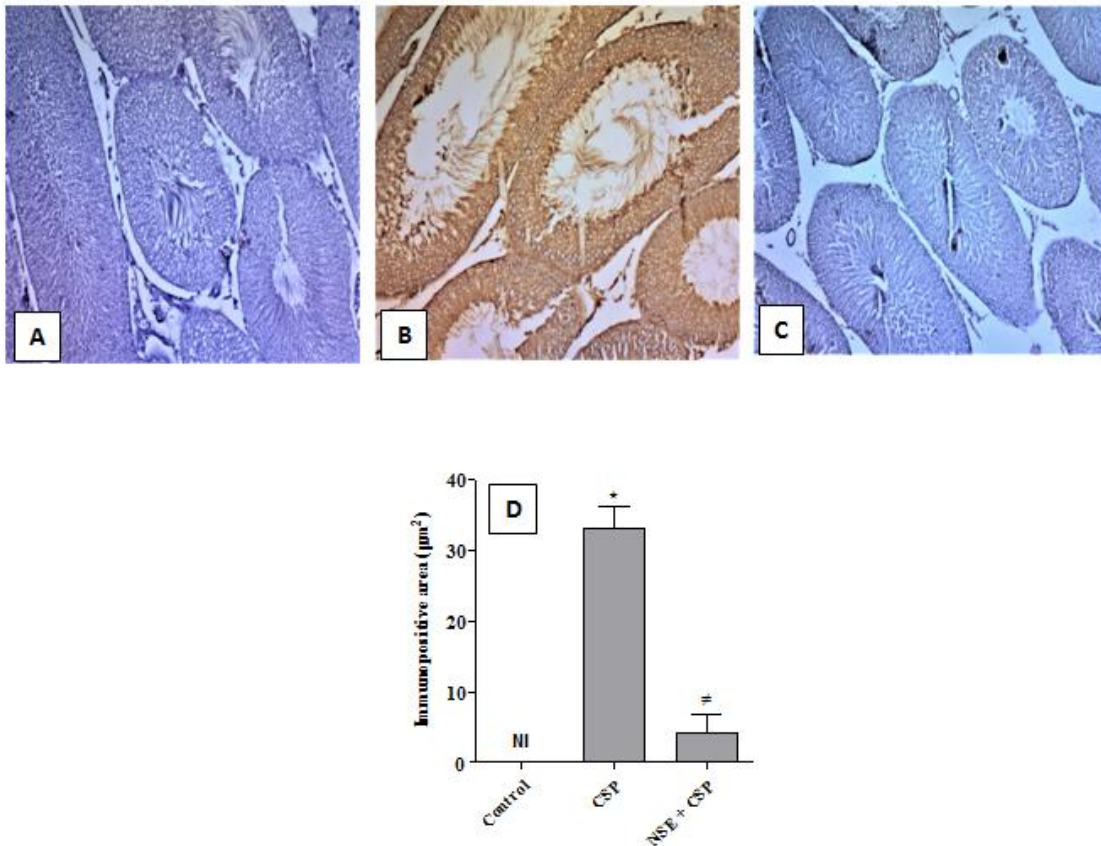


Fig. 4. Immunohistochemistry (200×) of p38 MAPK in rat testes from (A) control showing no immunostaining (NI); (B) cisplatin (CSP) group showing a significant increment of p38 MAPK immunoreactivity in brown color; (C) nimesulide (NSE) + CSP showing a significant decrement of p38 MAPK expression; (D) immunopositive area (µm²). **P* < 0.05 vs. control, #*P* < 0.05 vs. CSP

In addition, prior investigations demonstrated that oxidative stress induced by CSP up-regulated JNK and p38 MAPKs signaling pathways. Phosphorylation and activation of MAPKs resulted in phosphorylation of other target proteins which upon nuclear translocation activate gene transcription of many inflammatory biomarkers, as COX-2, TNF-α, and IL-1β, and apoptotic factors [21,22]. Furthermore, the up-regulated JNK and p38 MAPKs increase the release of NF-κB p65 unit in the cytoplasm, which translocates to the nucleus and acts as a transcriptional factor for inflammatory mediators [4,5]. Moreover, CSP-induced activation of MAPKs leads to upregulation of COX-2 and increased the generation of inflammatory prostaglandins [23,24]. This is in agreement with the current investigation in which CSP caused significant increments of p-JNK and p38 MAPKs, COX-2, PGE₂, NF-κB p65, TNF-α, IL-1β, Bax,

and caspase-3 in rat testes. Additionally, past studies, similar to the present one, revealed that NSE significantly down-regulated p-JNK and p38 MAPKs signaling pathways, and decreased COX-2, PGE₂, NF-κB p65, inflammatory cytokines, and apoptotic biomarkers [10,12,25]. Besides, the current study revealed that NSE significantly maintained the normal testicular histology, and serum testosterone indicating that NSE preserved the structure and function of the testes in rats challenged with CSP.

Several previous studies showed that natural compounds attenuated CSP testicular toxicity [26-28]. Some studies revealed that natural compounds provided more protective effect than synthetic compounds [26]. However, more investigations are required to compare the protective effect of NSE with natural substances in the rat model of CSP testicular toxicity.

5. CONCLUSION

It can be concluded from the present results that NSE afforded significant gonadal protective effect in male rats exposed to CSP toxicity. This is most probably mediated via down-regulation of p-JNK and p38 MAPKs pathways, and by defeating oxidative/nitrosative stress, inflammation, and apoptosis. Further studies are required to investigate the dose-dependent effect of NSE on larger number of CSP-challenged rats. NSE may be a feasible candidate to prevent testicular injury and dysfunctions in patients treated with CSP.

CONSENT

It is not applicable.

ETHICAL APPROVAL

The Research Ethics Committee, Faculty of Medicine, Minia University approved by the study protocol (approval number: 226-42019).

COMPETING INTERESTS

Authors have declared that no competing interests exist.

REFERENCES

1. Qi L, Luo Q, Zhang Y, Jia F, Zhao Y, Wang F. Advances in toxicological research of the anticancer drug cisplatin. *Chem Res Toxicol.* 2019;32:1469-86.
2. Ekinci Akdemir FN, Yildirim S, Kandemir FM, Aksu EH, Guler MC, Kiziltunc Ozmen H, et al. The antiapoptotic and antioxidant effects of eugenol against cisplatin-induced testicular damage in the experimental model. *Andrologia.* 2019;51:13353.
3. Kaushik S, Tomar A, Puthanmadhom Narayanan S, Nag TC, Arya DS, Bhatia J. Pitavastatin attenuates cisplatin-induced renal injury by targeting MAPK and apoptotic pathways. *J Pharm Pharmacol.* 2019;71:1072-81.
4. Ma ZN, Liu Z, Wang Z, Ren S, Tang S, Wang YP, et al. Supplementation of American ginseng berry extract mitigated cisplatin-evoked nephrotoxicity by suppressing ROS-mediated activation of MAPK and NF- κ B signaling pathways. *Food Chem Toxicol.* 2017;110:62-73.
5. Kim IH, Kwon MJ, Jung JH, Nam TJ. Protein extracted from *Porphyra yezoensis* prevents cisplatin-induced nephrotoxicity by downregulating the MAPK and NF- κ B pathways. *Int J Mol Med.* 2018;41:511-20.
6. Azab SS, Kamel I, Ismail NN, El Din Hosni H, El Fatah MA. The defensive role of taurine against gonadotoxicity and testicular apoptosis effects induced by cisplatin in rats. *J Infect Chemother.* 2020;26(1):51-57.
7. Kress HG, Baltov A, Basiński A, Berghea F, Castellsague J, Codreanu C, et al. Acute pain: a multifaceted challenge - the role of nimesulide. *Curr Med Res Opin.* 2016;32:23-36.
8. Arslan A, Ozcicek A, Suleyman B, Coban TA, Cimen FK, Nalkiran HS, et al. Effects of nimesulide on the small intestine mucositis induced by methotrexate in rats. *Exp Anim.* 2016;65:329-36.
9. Temp FR, Marafiga JR, Milanese LH, Duarte T, Rambo LM, et al. Cyclooxygenase-2 inhibitors differentially attenuate pentylenetetrazol-induced seizures and increase of pro- and anti-inflammatory cytokine levels in the cerebral cortex and hippocampus of mice. *Eur J Pharmacol.* 2017;810:15-25.
10. Mittal R, Kumar A, Singh DP, Bishnoi M, Nag TC. Ameliorative potential of rutin in combination with nimesulide in STZ model of diabetic neuropathy: targeting Nrf2/HO-1/NF- κ B and COX signalling pathway. *Inflammopharmacology.* 2018;26:755-68.
11. Afzal M, Bhardwaj DP, Khan R, Kazmi I, Saleem S, Al-Abbasi FA, et al. Antineoplastic influence of nimesulide in chemically induced hepatocellular carcinoma by inhibition of DNA synthesis. *Inflammopharmacology.* 2019;27:89-98.
12. Polat EC, Bozkurt AS, Keskin Cimen F, Gulaboglu M, Altuner D. The investigation of the protective effects of nimesulide on experimental testicular ischemia-reperfusion injury in rats. *Rev Int Androl.* 2020;18(2):55-62.
13. Köroğlu KM, Çevik Ö, Şener G, Ercan F. Apocynin alleviates cisplatin-induced testicular cytotoxicity by regulating oxidative stress and apoptosis in rats. *Andrologia.* 2019;51:13227.
14. Erpek S, Bilgin MD, Dikicioglu E, Karul A. The effects of low frequency electric field in rat testis. *Rev Med Vet (Toulouse).* 2007;158:206-11.

15. Johnsen SG. Testicular biopsy score count - a method for registration of spermatogenesis in human testes: normal values and results in 335 hypogonadal males. *Horm Res Paediatr.* 1970;1:2-25.
16. Fouad AA, Refaie MMM, Abdelghany MI. Naringenin palliates cisplatin and doxorubicin gonadal toxicity in male rats. *Toxicol Mech Methods.* 2019;29:67-73.
17. Tian M, Liu F, Liu H, Zhang Q, Li L, Hou X, et al. Grape seed procyanidins extract attenuates Cisplatin-induced oxidative stress and testosterone synthase inhibition in rat testes. *Syst Biol Reprod Med.* 2018;64:246-59.
18. Amin A, Abraham C, Hamza AA, Abdalla ZA, Al-Shamsi SB, Harethi SS, et al. A standardized extract of Ginkgo biloba neutralizes cisplatin-mediated reproductive toxicity in rats. *J Biomed Biotechnol.* 2012;2012:362049.
19. Sherif IO, Sabry D, Abdel-Aziz A, Sarhan OM. The role of mesenchymal stem cells in chemotherapy-induced gonadotoxicity. *Stem Cell Res Ther.* 2018;9:196.
20. Michel HE, Menze ET. Tetramethylpyrazine guards against cisplatin-induced nephrotoxicity in rats through inhibiting HMGB1/TLR4/NF- κ B and activating Nrf2 and PPAR- γ signaling pathways. *Eur J Pharmacol.* 2019;857:172422.
21. Chen X, Wei W, Li Y, Huang J, Ci X. Hesperetin relieves cisplatin-induced acute kidney injury by mitigating oxidative stress, inflammation and apoptosis. *Chem Biol Interact.* 2019;308:269-78.
22. Kandeil MA, Mahmoud MO, Abdel-Razik AH, Gomaa SB. Thymoquinone and geraniol alleviate cisplatin-induced neurotoxicity in rats through downregulating the p38 MAPK/STAT-1 pathway and oxidative stress. *Life Sci.* 2019;228:145-51.
23. Yamaguchi K, Ishikawa T, Kondo Y, Fujisawa M. Cisplatin regulates Sertoli cell expression of transferrin and interleukins. *Mol Cell Endocrinol.* 2008;283:68-75.
24. Mohamed HE, Badawy MMM. Modulatory effect of zingerone against cisplatin or γ -irradiation induced hepatotoxicity by molecular targeting regulation. *Appl Radiat Isot.* 2019;154:108891.
25. Niranjan R, Rajasekar N, Nath C, Shukla R. The effect of guggulipid and nimesulide on MPTP-induced mediators of neuroinflammation in rat astrocytoma cells, C6. *Chem Biol Interact.* 2012;200:73-83.
26. Fekry E, Rahman AA, Awany MM, Makary S. Protective effect of mirtazapine versus ginger against cisplatin-induced testicular damage in adult male albino rats. *Ultrastruct Pathol.* 2019;43(1):66-79.
27. Jahan S, Munawar A, Razak S, Anam S, Ain QU, Ullah H, Afsar T, Abulmeaty M, Almajwal A. Ameliorative effects of rutin against cisplatin-induced reproductive toxicity in male rats. *BMC Urol.* 2018;18(1):107.
28. Aksu EH, Kandemir FM, Altun S, Küçükler S, Çomaklı S, Ömür AD. Ameliorative Effect of Carvacrol on Cisplatin-Induced Reproductive Damage in Male Rats. *J Biochem Mol Toxicol.* 2016;30(10):513-520.

© 2020 Fouad et al.; This is an Open Access article distributed under the terms of the Creative Commons Attribution License (<http://creativecommons.org/licenses/by/4.0>), which permits unrestricted use, distribution, and reproduction in any medium, provided the original work is properly cited.

Peer-review history:

The peer review history for this paper can be accessed here:
<http://www.sdiarticle4.com/review-history/60705>