

Penile Metastasis from Prostate Cancer: A Rare Case

Benatta Mahmoud^{1*} and Mohamed Allouche²

¹Urology Department, Oran Ahmed Ben Bella, CHU Oran, Algeria.

²EPH Mohammadia Mascara, Algeria.

Authors' contributions

This work was carried out in collaboration between both authors. Both authors read and approved the final manuscript.

Article Information

Editor(s):

(1) Dr. Punit Bansal, RG Stone and Superspeciality Hospital, India.

Reviewers:

(1) Yorkum Leyira Kenneth, University Of Port Harcourt, Nigeria.

(2) Mukesh Chandra Arya, Sardar Patel Medical College, India.

Complete Peer review History: <https://www.sdiarticle4.com/review-history/74025>

Case Study

Received 01 September 2021

Accepted 04 October 2021

Published 18 November 2021

ABSTRACT

The penis is a rare site of prostate cancer metastasis, the incidence of this metastatic site is less than 0.3%.

We present the case of a 67-year-old man who was consulted after the appearance of a painless red nodule on the penile glans that bled on touch. Digital-rectal examination revealed a nodular and hard prostate, and the PSA level was above 100 ng/ml.

Prostate biopsy confirmed adenocarcinoma Gleason 4+4, and histological examination of the piece resection biopsy of the penile lesion confirmed that it was adenocarcinoma.

MRI of the pelvis showed involvement of the corpus cavernosum and pubic bone by the adenocarcinoma

Bone scintigraphy showed secondary localization to the fourth lumbar vertebra and ischio-pubic branch. The multidisciplinary concerting committee decided on first-line hormonal therapy and chemotherapy.

The patient refused chemotherapy and took only hormonal therapy. We examined him 16 months later. The PSA level was 12 ng/ml, and the penile lesion had completely disappeared.

Keywords: Penis; cancer; metastasis.

1. INTRODUCTION

Due to the high incidence of bone and lung dissemination, penile localization of prostate cancer is exceptional.

It is a debilitating condition at presentation with a worse prognosis the mean survival time is 9 months and the longest reported survival time of 60 months [1].

Therefore conservative management is generally advocated, with emphasis on improvement of quality of life. Therapeutic modalities used include chemotherapy, hormonotherapy, surgery, and radiotherapy [2,3,4].

We report a case of penile metastasis in a 67-year-old man. The metastasis had appeared as a nodule on the glans. Clinical and histological examination revealed the prostatic origin of the tumour.

2. CASE REPORT

CM, 67 years old, a married father of 03 children with a history of arterial hypertension under treatment, came to our department because of the appearance of a painful nodular lesion 02 cm in diameter on the glans penis (Fig. 1).

Clinical examination revealed a patient with an intact general condition. Digital rectal examination revealed a hard prostate and PSA level was above 100 ng/ml.

A prostate biopsy revealed that it was adenocarcinoma of the prostate.

A prostate biopsy revealed that it was adenocarcinoma of the prostate, Gleason 4+ 4.

We performed a biopsy resection of the penile node under local anaesthesia.

Anatomic pathological examination confirmed the lesion as an adenocarcinoma.

Pelvic MRI (Fig 02) showed a heterogeneous prostate tumour process with invaded capsule by contiguity. The penile lesion involved cavernous and spongy corpora and appeared as a necrotic nodule of 25 16-mm axis involving the ischio-pubic branchial area and adjacent muscle infiltration.

Bone scintigraphy showed metastatic localization to the fourth lumbar vertebra and left ischium.

Multidisciplinary consultation opted for first-line hormonal treatment in conjunction with chemotherapy.

The patient complied with hormone therapy but declined chemotherapy. We reviewed him 16 months after starting hormone therapy.

He was in good general health. The PSA level was 12 ng - ML and a normal appearance of the penis (Fig. 3).

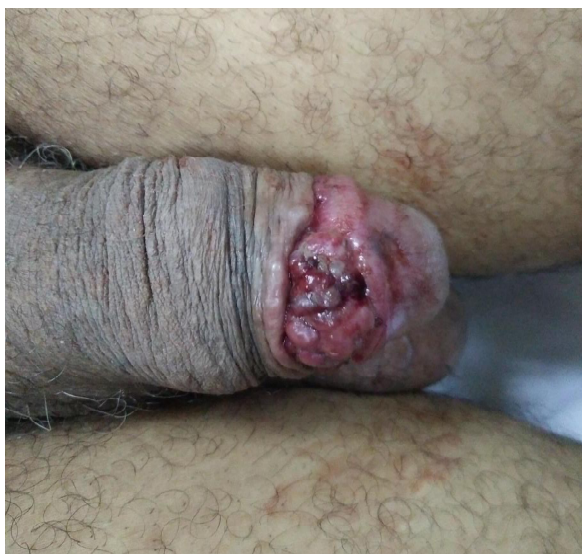

Fig. 1. Penile nodular lesion

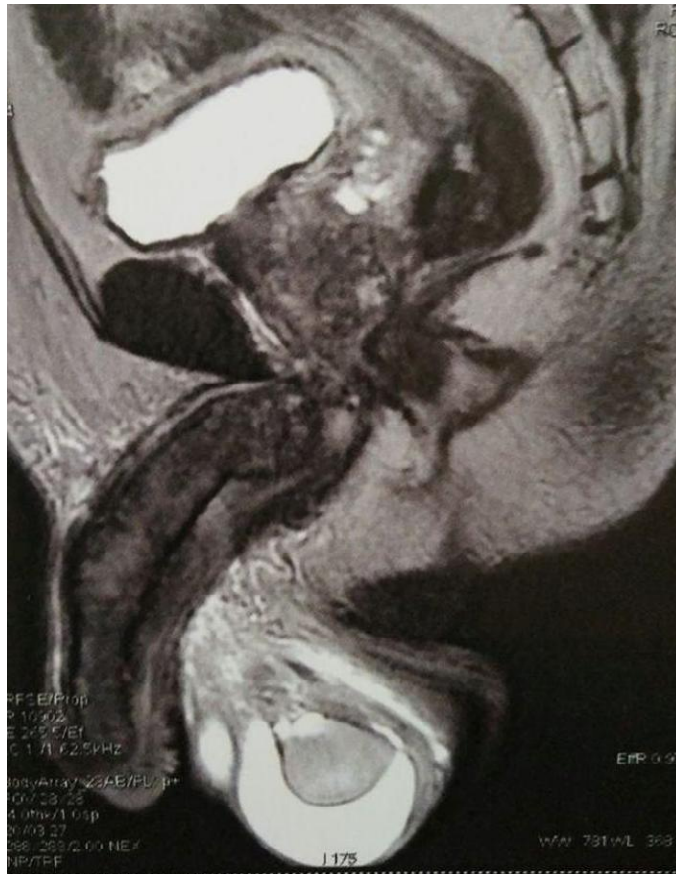

Fig. 2. Pelvic MRI showing involvement of cavernosae corporea and spongiosus




Fig. 3. Penile appearance 16 months after hormone therapy

3. DISCUSSION

Penile metastases are an exception according to the literature [5], the incidence of this metastatic site is less than 0.3%, only 17 cases were described in the literature between 2015 and 2021 [6].

To the best of our knowledge, only 29 cases of penile metastases of prostate cancer have been described in the English literature.

The clinical presentation is manifested by one or more painful nodules [5,7], sometimes accompanied by priapism, voiding dysfunction, painful erection and erectile dysfunction.

Our patient complained of a painful 2 cm nodule at the level of the glans penis without urinary symptoms in a 67-year-old patient.

The route of spread of cancer cells from the prostate to the penis is the subject of much debate.

Several mechanisms are possible:

Spread via the arterial route: this is where neoplasm emboli from lung metastases enter the bloodstream.

Spread via the venous route: there is an anastomosis that communicates with the venous plexus of the prostate and the dorsal vein of the penis [8].

A sudden increase in pressure in the chest or abdomen, such as with exertion or a coughing fit, may temporarily reverse the direction of venous flow and drive off an embolus of malignant cells toward the penis.

Lymphatic extension is possible towards the inguinal lymph nodes, which accompany the dorsal vein of the penis and communicate with those of the prostate and the lower third of the bladder.

However, the presence in the patient we report observing on pelvic MRI of contiguous invasion of the base of the corpus cavernosum and the spongy body prompted us to consider direct extension through the ischiatic cavities rectally, as the most likely penile metastases are not isolated. Usually occur at a late stage of the disease, other lesions, bone, lung, ganglion accompany them.

The most common symptomatology are penile pain, ulceration, painful or painless palpable penile nodules, priapism, urinary retention, dysuria, and hematuria [9] wong [10]-zhang.

Treatment modalities depend on the symptomatology and the general condition of the patient, metastases and their impact.

obstructive voiding disorders are managed with Suprapubic catheterisation, or transurethral resection of the prostate [4].

hematuria can require transfusion, clotting or even endoscopic or surgical hemostasis subtotal penectomy for severe penile pain with perineal urethrostomy may be necessary [3].

hormonotherapy hormonal therapy, or , in the form of an anti-androgen, 4 weeks and a gonadorelin analogue subcutaneously every 3 months“ [4] bilateral orchidectomy hormonal treatment combined with radiotherapy [2] another Palliative treatment for pain palliative radiation therapy is to be considered [2].

The treatment options include local excision of the tumor, radiation therapy, bilateral orchiectomy, additional hormonal and chemotherapy, and partial or total amputation of the penis.

Our patient underwent only surgical excision of the penile nodule and hormone therapy.

We treated the case as metastatic prostate cancer [5].

We reserve surgery to relieve severe pain, resolve an ulcer problem, and treat priapism.

Radical surgical treatment has a place when there is a single metastatic lesion.

Treatment is often palliative; the goal is to improve the patient's quality of life.

Prognosis is worse and life expectancy is low, 71% of patients die six months after diagnosis according to the literature.

the longest survival duration reported was 5 years, in a patient with the primary tumor responded well to the hormonal treatment combined with radiotherapy until serum PSA levels started to increase again [1]. However patients with malignant priapism showed

significantly worse prognosis than patients with penile metastasis without priapism [2].

The case of our patient showed a favorable outcome with hormonal therapy alone.

4. CONCLUSION

Secondary localization in the penis in prostate cancer is very rare and often part of a multimetastatic disease whose survival is short. Metastatic prostate cancer requires multidisciplinary management. The goal is to improve the quality of life.

CONSENT

As per international standard or university standard, patients' written consent has been collected and preserved by the authors.

ETHICAL APPROVAL

As per international standard or university standard written ethical approval has been collected and preserved by the authors.

COMPETING INTERESTS

Authors have declared that no competing interests exist.

REFERENCES

1. Nana Fujita, MD, Ryo Kurokawa, MD, Risa Kaneshima, Munetaka Machida, Go Kawai, Tomoki Wada, Masamichi Takahashi, Moto Nakaya, Naoya Sakamoto, Shinichi Cho, Osamu Abe, Yujiro Matsuoka, Patient with penile metastasis from prostate cancer and survival over 5 years: A case report with longitudinal evaluation using computed tomography and magnetic resonance imaging. *Radiology Case Reports*. 2021;16:1255–1258.
2. Cocci A, Hakenberg OW, Cai T, Nesi G, Livi L, Detti B, et al. Prognosis of men with penile metastasis and malignant priapism: a systematic review. *Oncotarget* 2018;9:2923–30. DOI: 10.18632/oncotarget.23366.
3. Joe Philip, Joseph Mathew. Penile metastasis of prostatic adenocarcinoma: Report of two cases and review of literature. *World Journal of Surgical Oncology*, 2003;1:16. Available: <http://www.wjso.com/content/1/1/16>
4. Gregory J. Nason¹, Michael K. O'reilly¹, Ronan M. Long¹, Helen Ingoldsby², Ciara Barrett² & Kiaran J. O'malley¹. A presentation of glandular penile metastases from prostate adenocarcinoma. *Scandinavian Journal of Urology and Nephrology*. 2012;46:306–309.
5. Kristian krpina, dean markić, josip španjol, maksimvalenčićand željkofučkar Penile metastases of prostate cancer, *Acta Clin Croat*. 2011;50(3):431-3.
6. Junjie Fan, Hua Liang, Xing Zhang, Xingfa Chen, Xiaoyi Duan, Lei Li, Dalin He, and Kaijie Wu ' Case Report: F-PSMA PET/CT May Improve the Clinical Management of Penile Metastases From Prostate Cancer; *Front Oncol*. 2021;11:683343.
7. McCrea LW, Karafin L. Carcinoma of the prostate: metastases, therapy and survival; a statistical analysis of five hundred cases. *J Int Coll Surg*. 1958;29:723-8.
8. Vinayakrohan, Abhinandanhanji, Jayeshpatel, Jigneshgoswami, Rajentankshali. Penile metastases from prostate cancer. *Urolog*. 2009;6:217-9.
9. Wong HL, Shi H, Koh LT. Solitary metastasis to the penis from prostate adenocarcinoma—a case report. *J Radiol Case Rep* 2019;13:20–8. DOI: 10.3941/jrcr.v13i12.3846
10. Zhang K, Da J, Yao HJ, Zheng DC, Cai ZK, Jiang YQ, et al. Metastatic tumors of the penis: a report of 8 cases and review of the literature. *Medicine* 2015;94:e132. DOI: 10.1097/MD.000000000000132

Peer-review history:
The peer review history for this paper can be accessed here:
<https://www.sdiarticle4.com/review-history/74025>