



Infectious Crystalline Keratopathy Caused by Diphtheroids Treated with Intrastromal Antibiotics in a Post-corneal Transplant Patient

Archimedes Lee D. Agahan^{1*} and Raymond Nelson C. Regalado¹

¹Department of Ophthalmology and Visual Sciences Sentro Oftalmologico Jose Rizal, Philippine General Hospital, University of the Philippines Manila, Taft Avenue, Manila, Philippines.

Authors' contributions

This work was carried out in collaboration between both authors. Author ALDA designed and supervised the study and wrote the first draft of the manuscript. Author RNCR managed the literature searches and editing of manuscript. Both authors read and approved the final manuscript.

Article Information

DOI: 10.9734/OR/2016/22864

Editor(s):

(1) Li Wang, Department of Ophthalmology, Cullen Eye Institute, Baylor College of Medicine, USA.

Reviewers:

(1) Sagili Chandarsekhara Reddy, University of Malaysia, Malaysia.

(2) Adeoti C. O, Ladoke Akintola University of technology, Nigeria.

(3) Agnes Fust, Semmelweis University, Hungary.

Complete Peer review History: <http://sciencedomain.org/review-history/12613>

Case Study

Received 2nd November 2015
Accepted 25th November 2015
Published 9th December 2015

ABSTRACT

Purpose: To present a case of infectious crystalline keratopathy caused by Diphtheroids in a post-corneal transplant patient.

Design: Prospective, interventional case report.

Case Report: This is a case of a 44 year-old male seen at a tertiary hospital in Manila, Philippines. He underwent penetrating keratoplasty of the right eye 5 years prior to present consult for a corneal scar secondary to trauma sustained in childhood. Three years after the initial surgery, patient suffered another blunt trauma incident, causing graft dehiscence, and eventually necessitating graft re-suturing. In the interim, he experienced recurrent eye redness, to which he self-medicated with topical corticosteroids. Non-resolution of symptoms prompted the present consult.

Methodology/Results: The patient consulted 9 months after the second surgery. Initial examination revealed an intact corneal epithelium, with white branching needle-like infiltrates

*Corresponding author: E-mail: adagahan@up.edu.ph, docagahan@yahoo.com;

located from the anterior to midstroma of the corneal graft. Culture of the corneal scraping was done, which revealed growth of Diphtheroids. Moxifloxacin was injected intrastromally. Topical corticosteroid was discontinued and topical Moxifloxacin was started. After 1 month of therapy, the infiltrates were eradicated and a vascularized scar developed on the graft.

Conclusion: Diphtheroids can be a causative organism of infectious crystalline keratopathy, with a clinical presentation similar to those caused by Gram positive cocci. Intrastromal antibiotic injection and discontinuation of topical corticosteroids are essential in the treatment of this condition.

Keywords: Infectious crystalline keratopathy; diphtheroids.

1. INTRODUCTION

Infectious crystalline keratopathy (ICK) is an infection of the corneal stroma usually appearing in post-surgical eyes. It appears as a progressive branching-pattern corneal opacity, usually caused by alpha-hemolytic Streptococci, Corynebacteria, and other gram negative bacteria [1,2]. These microorganisms form a biofilm, which acts as a matrix for proliferation and possibly a protective barrier against antibiotics [3,4]. Although a rare causative agent, Diphtheroids have also been known to form biofilms, and together with their ability to penetrate even an intact cornea, may possibly cause ICK [3,4]. This paper aims to report a case of ICK in a post-corneal transplant patient caused by Diphtheroids seen at a tertiary hospital in Manila, Philippines.

2. CASE REPORT

A 44 year-old male farmer sustained a blunt trauma to the right eye with a knife when he was 7 years old. He was brought to a local ophthalmologist and was prescribed with unrecalled antibiotic drops. No surgery was done. Five years ago (32 years after the initial incident), the patient underwent penetrating keratoplasty at a private hospital in Manila for a corneal scar as a sequelae of the said trauma. Postoperatively, he was given Prednisolone Acetate, Moxifloxacin, and Sodium chloride drops and was eventually lost to follow-up.

Two years ago, he sustained another blunt trauma to the right eye with a metal chain, which led to graft dehiscence. He then underwent re-suturing of the graft at the same hospital where the first surgery was done. In the interim, he experienced on and off redness for which he self-medicated with Prednisolone Acetate drops 4x daily.

He was seen at the External Disease and Cornea Clinic of a tertiary hospital in Manila 9

months after the second surgery, due to complaints of progressive blurring of vision, eye redness, and the appearance of a whitish opacity at the center of the corneal graft.

2. METHODOLOGY

On initial consultation, the visual acuity of the right eye was hand movement with good light projection. The intraocular pressure was 10 mmHg. Slit lamp examination revealed an intact corneal epithelium with multiple white, branching needle-like deposits located in the anterior to midstroma surrounded by clear cornea temporally and hazy cornea nasally. The conjunctiva was slightly hyperemic, 5 loose sutures were noted at the temporal graft-host interface with some stromal vessels approaching the sutures (Fig. 1). The anterior segment showed a formed anterior chamber with clear lens and no hypopyon. The posterior segment had an attached retina seen through the clear temporal corneal graft. The assessment at the clinic was infectious crystalline keratopathy (ICK) of the right eye.

3. RESULTS

Deep scraping of the deposits using a 27G cystotome was done. The loose sutures were removed and sent for culture and sensitivity examination. The right eye was injected intrastromally with 0.1 ml Moxifloxacin. Prednisolone acetate was immediately discontinued. The patient was discharged on hourly Moxifloxacin and Atropine sulfate thrice daily. Gram and giemsa stain of the corneal scraping showed no organisms; however on Brain Heart Infusion (BHI) broth sub-cultured on blood agar plate, there was moderate growth of pleomorphic gram positive bacilli. Culture of the removed sutures was negative for growth of organisms.

Three days post-injection (Fig. 2), there was blurring of the details of the stromal crystalline

deposits with increased conjunctival hyperemia. After 1 month (Fig. 3), the corneal graft was almost fully scarred. At this point, Prednisolone acetate was started thrice daily and Moxifloxacin was reduced to 4x daily. The plan for the right

eye was to do a penetrating keratoplasty but the patient did not consent for the procedure. At 4 months, the corneal graft was fully scarred (Fig. 4).

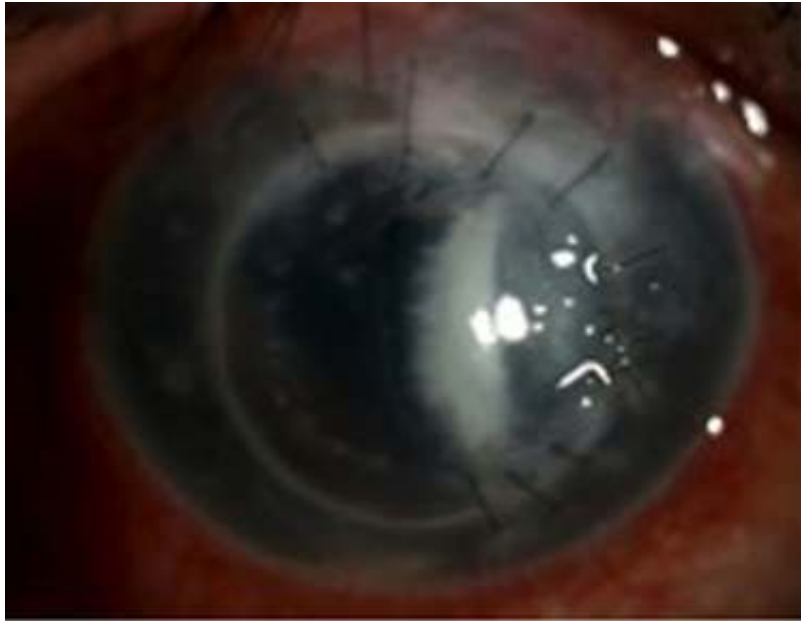

Fig. 1. Slit lamp photo on consultation reveals a hazy graft with an intact corneal epithelium with multiple white, branching needle-like deposits located in the anterior to midstroma surrounded by clear cornea temporally and hazy cornea nasally. The conjunctiva was slightly hyperemic with 5 loose sutures and some stromal vessels approaching the sutures at the temporal graft-host interface

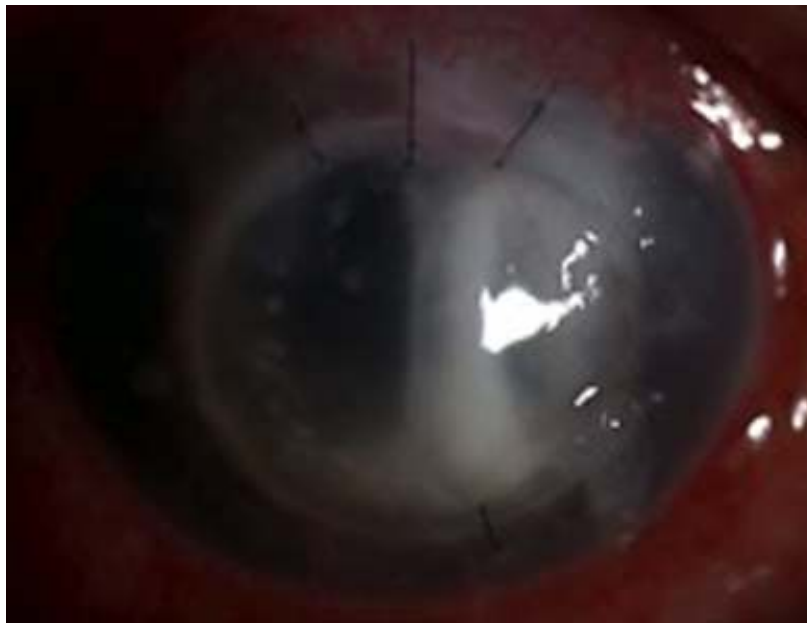


Fig. 2. Slit lamp photo at 3 days post-injection of Moxifloxacin

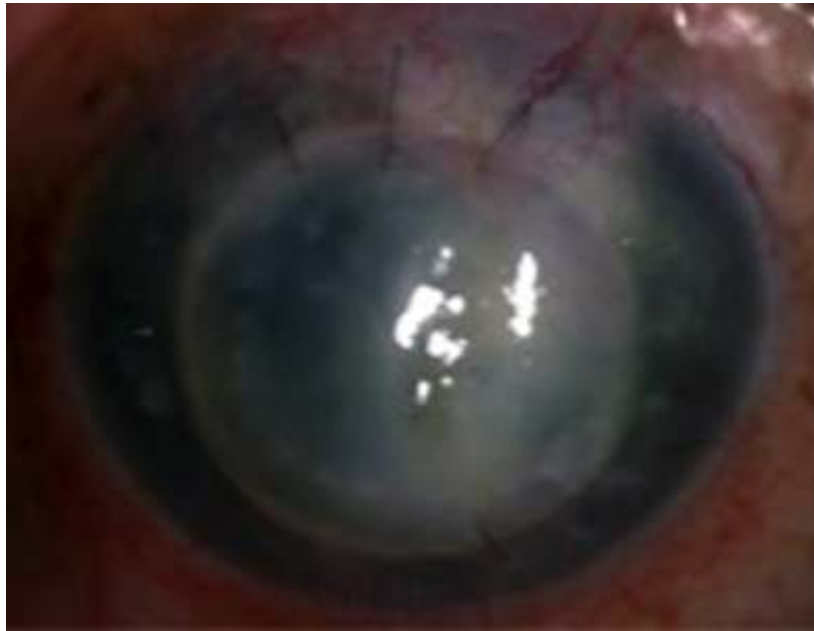

Fig. 3. Slit lamp photo at 1 month illustrates increase scarring in the graft

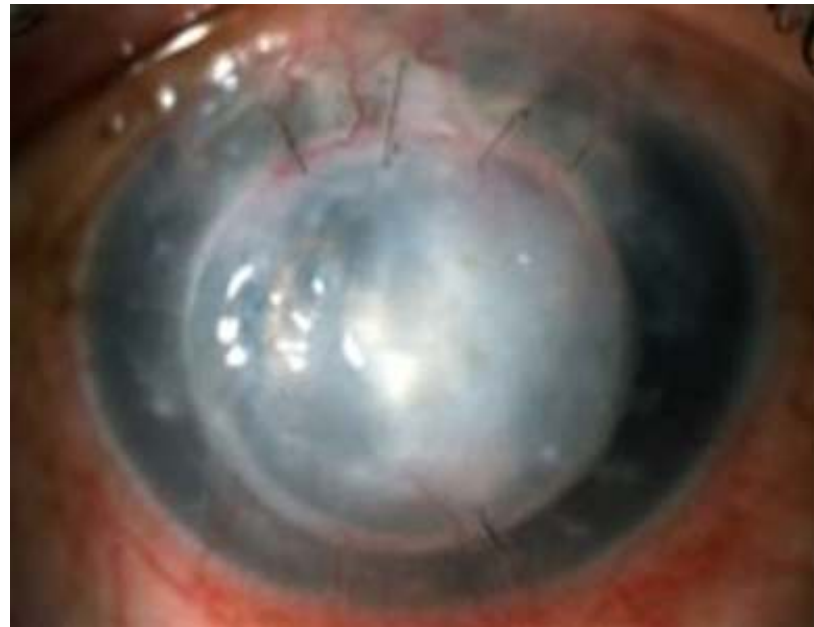

Fig. 4. Slit lamp photo at 4 months shows scarring of the entire graft

4. DISCUSSION

Infectious Crystalline Keratopathy is a rare infection characterized by intrastromal branching needle-like crystalline opacities, paucity of inflammatory reaction, and poor response to antimicrobial therapy [1]. Although it is usually found in a corneal graft after long-term use of topical

corticosteroids, ICK has also been found after refractive surgery, phacoemulsification, and in immunocompromised corneas (Herpes Simplex Virus, Acanthamoeba, topical anesthetic abuse) [2].

The intrastromal crystalline appearance is caused by the multiplication of organisms which spread between lamellae unhindered by an

immunosuppressed, avascular cornea [5]. The paucity of inflammatory reaction may be attributed to the prolonged steroid use and the formation of biofilm.

A biofilm has been defined as a functional consortium of microorganisms organized within an extensive exopolymer matrix and has been implicated in the pathogenesis of ICK. This bacterial extracellular matrix interferes with host immune responses and protects the organisms from antibiotics, possibly by binding large numbers of antibiotic molecules and by reducing the metabolic activity of the pathogens [6].

Alpha-hemolytic streptococci are the most common organisms implicated. Other identified organisms are *Corynebacterium*, *Staphylococci*, *Haemophilus*, Gram negative bacteria, and fungi [2]. Diphtheroids are generally aerobic non-spore formers and appear microscopically as pleomorphic gram positive rods. *Corynebacterium* and *Propionibacterium* are the most common diphtheroids isolated from the conjunctiva, eyelid, and compromised cornea and *C. diphtheriae* are among the organisms that can penetrate an intact cornea. The ability of some *Corynebacterium* strains to form bacterial biofilms has been reported [3,4].

In the 1980's, ICK was treated with subconjunctival and systemic antibiotics but results were variable. Intrastromal antibiotic injection for the treatment of ICK is relatively new and there are only few reports regarding this subject [7]. They have concluded that this treatment modality is effective in treating ICK. Some reports have also shown that Nd: YAG laser corneal disruption of the bacterial biofilm reduced the resistance to antimicrobial therapy [8]. Although these interventions may eradicate the infecting organism, vascularization and scar formation, which may be due to lipid deposition and wound healing, can affect the final visual acuity and require keratoplasty.

ETHICAL APPROVAL

All authors hereby declare that all experiments have been examined and approved by the

appropriate ethics committee and have therefore been performed in accordance with the ethical standards laid down in the 1964 Declaration of Helsinki.

COMPETING INTERESTS

Authors have declared that no competing interests exist.

REFERENCES

1. Sutton GL, Miller RC, Robinson LP. Infectious crystalline keratopathy. Australian and New Zealand J Ophthalmol. 1990;18(2):151-153.
2. Kintner JC, Grossniklaus HE, Lass JH, et al. Infectious crystalline keratopathy associated with topical anesthetic abuse. Cornea. 1990;9(1):77-80.
3. Suzuki T, Iihara H, Uno T, et al. Suture-related keratitis caused by *Corynebacterium macginleyi*. Journal of Clinical Microbiology. 2007;45(11):3833-3836.
4. Kwaszewska AK, Brewczyńska A, Szewczyk EM. Hydrophobicity and biofilm formation of lipophilic skin *Corynebacteria*. Polish Journal of Microbiology. 2006;55(3): 189-193.
5. Butler TK, Dua HS, Edwards R, et al. *In vitro* model of infectious crystalline keratopathy: Tissue architecture determines pattern of microbial spread. Invest Ophthalmol Vis Sci. 2001;42:1243-1246.
6. Georgiou T, Qureshi SH, Chakrabarty A, et al. Biofilm formation and coccal organisms in infectious crystalline keratopathy. Eye. 2002;16:89-92.
7. Khan IJ, Hamada S, Rauz S. Infectious crystalline keratopathy treated with intrastromal antibiotics. Cornea. 2010; 29(10):1186-1188.
8. Daneshvar H, et al. Nd: YAG laser corneal disruption as adjuvant treatment for infectious crystalline keratopathy. Am J Ophthalmol. 2000;129:800-801.

Peer-review history:

The peer review history for this paper can be accessed here:
<http://sciencedomain.org/review-history/12613>