



Borrelia Infection Appears as Chronic Lymphocytic Leukemia: Therapy with *Amanita phalloides* and *Terebinthina laricina*

Isolde Riede^{1*}

¹*Im Amann 7D-88662 Uberlingen, Independent Cancer Research, Uberlingen, Germany.*

Author's contribution

The sole author designed, analyzed and interpreted and prepared the manuscript.

Article Information

DOI: 10.9734/BJMMR/2015/16449

Editor(s):

- (1) Alex Xiucheng Fan, Department of Biochemistry and Molecular Biology, University of Florida, USA.
(2) Salomone Di Saverio, Emergency Surgery Unit, Department of General and Transplant Surgery, S. Orsola Malpighi University Hospital, Bologna, Italy.

Reviewers:

- (1) Golam Hafiz, Bangabandhu Sheikh Mujib Medical University, Shahbag, Dhaka, Bangladesh.
(2) Kiri H. Jaryum, Department of Biochemistry, University of Jos, Nigeria.
Complete Peer review History: <http://www.sciencedomain.org/review-history.php?iid=947&id=12&aid=8421>

Case Study

Received 2nd February 2015

Accepted 3rd March 2015

Published 12th March 2015

ABSTRACT

Background: To date, Chronic Lymphocytic Leukemia (CLL) has been viewed as a malignant disease with tumor growth of cells. This hypothesis should be reviewed.

Methods: A patient diagnosed with CLL is treated with *Amanita phalloides*, containing amanitin, inhibiting specifically tumor cell activity without affecting normal cells. Despite initial leukocyte cell count decrease, further therapy fails after eight months. He suffers from severe symptoms of inflammation, not specific for CLL. Additional Borrelia infection is diagnosed and *Terebinthina laricina* is applied.

Results: Herxheimer reaction occurs some weeks later, accompanied by continuous leukocyte cell count drop to normal range within four months, even after stopping Amanita therapy. All symptoms of borreliosis and CLL vanished.

Conclusion: CLL might be induced by a Borrelia-infection. This should be considered in diagnostic and therapeutic regimen.

Keywords: *Amanita phalloides*; *Terebinthina laricina*; CLL; lyme disease; *Borrelia infection*.

*Corresponding author: Email: riede@tumor-therapie.info;

1. INTRODUCTION

In a genetic experiment with tumor forming *Drosophila melanogaster*, four classes of genes involved in tumor formation could be distinguished:

- Proliferative genes break the cell cycle control by allowing replication immediately after mitosis. They influence the somatic pairing of chromosomes [1]. One single proliferative mutation is sufficient for tumor formation. These mutations lead to intrinsic chemotherapy resistance, and to replication partially with the repair system.
- Mutations in oncogenes and tumor-suppressor genes are secondary events and add by destabilization of the differentiation pattern of the cells.
- In a search for ubiquitous events, the central possible targets for therapeutic intervention, switch genes were identified: They interact with tumor forming mutations in trans. Functionally, switch genes all code for ribose nucleic acid polymerase II (RNAP) transcription factors. They are overexpressed in human tumor cells [2].

Therefore, the event that leads to tumor cell growth should lead to saturated activity of RNAP, a biochemical bottleneck of tumor growth. In somatic cells of adults, RNAP is expected to be less active. Partial inhibition of this enzyme consequently causes inhibition of tumor cell activity, without effects on somatic cells. The drug in the extract of *Amanita phalloides*, amanitin, blocks RNAP in all cells. Inhibition of about 50% of this molecule has no effect on normal body cells. Immune cells usually recognize and lyse tumor cells. If tumor cell activity is reduced with *Amanita phalloides* the immune system is able to digest the tumor cell, which stabilizes the disease. Amanita treatment already showed good results in a number of tumor cases. In addition, several B-CLL are treated successfully so far (example in [3]).

The incidence of Lyme borreliosis is increasing in many countries. It is caused by spirochaetes of the *Borrelia burgdorferi* species, which are transmitted by ticks. Borrelia appear as spirilla, they move throughout the host and can reach every tissue, causing severe manifestations that can involve a patient's skin, nervous system, joints, and heart. Often glia cells are involved in inflammation and manifestation of the disease [4,5]. This leads to affections of the nerve tract,

signal transduction is deranged, feedback systems are interrupted. Wherever this occurs, various symptoms appear. Cell death of glia and neural cells lead to paralysis, pain, arthritis and damage of inner organs [6]. Damage of nerve tracts that supply the heart cause various symptoms including heart rhythms disorders [7]. Frequently dorsalgia occurs, originating from mechanical instability due to paralysis of muscles tracts. The worst pain is often in the early morning, analgesic drugs rarely help. Pain attacks can be accompanied by night sweat. So far, lymphadenopathy due to Borrelia infection is described [8]. As well mantle cell carcinoma statistically seems to be correlated with Borrelia infection, but not non Hodgkin lymphoma [9]. Chronic lymphocytic leukemia (CLL) was not associated with Borrelia infection so far.

Laboratory evidence of infection, mainly serology, is essential for diagnosis, except in the case of typical erythema migrans. Titrated are anti-Borrelia Immunoglobulin M (IgM) and anti-Borrelia IgG. IgM antibodies occur two weeks after infection and should be replaced by immunoglobulin G (IgG) antibodies about four weeks after infection. Usually the fresh infection, i.e. IgM antibodies are not discovered, only the later appearing IgG antibodies. Unfortunately the existing test systems are not very sensitive and specific, meaning that about 40% of Borrelia infections remain undetected, and about 20% are wrong positives [10].

Extract of the resin of *Larix decidua*, *Terebinthina laricina* is used against rheumatic disorders, burning and dragging pain, kidney problems with turbid urine or proteinuria. Old documents describe medical applications by earache, rheumatism, neuralgia, toothache or infections of the skin. Internal application is described for gonorrhoea, with possible side effects like kidney inflammation, diarrhoea and occurrence of allergies.

Borrelia infection appears with symptoms described in these old documents, and identical with the leading symptoms for homeopathic use. Successful treatment of neuroborreliosis with *Terebinthina laricina* is possible [11]. The mode of action of Terebinthina is not yet understood. A slow antibiotic effect affecting the motility of the bacteria is in discussion. Applied to Borrelia in culture, in the appropriate dilution used in therapy, the motility of the bacteria is slower after three days, after nine days less bacteria than in the control are visible, and they show a slightly different morphology.

Successful treatment of spirochetes like *Borrelia* or *Treponema* infection leads to a Herxheimer reaction [12]. Thereby symptoms like fever occur, combined with an increase of general constitutional disturbances. Today this is seen as the result of a release of endotoxins from dying bacteria. *Terebinthina laricina* can lead to a Herxheimer reaction at the end of some weeks of therapy. This can be combined with micturition problems, and a slight decrease of the ability of clearance by the kidney. Micturition problems vanish within days, the kidney recovers within weeks. *Borrelia* disappear completely by this process, induced defects might be reversible within months.

CLL is the most frequently occurring leukemia in the Western hemisphere, with an incidence of 4 in 100,000. Until 20 years ago, the basic medical approach to this disease was expectative and palliative. Chemotherapy with alkylating agents or purine analogs occurs. This was followed by hematopoietic progenitor support, monoclonal antibodies, and further immunotherapies. More sophisticated techniques since then allow characterization of some of the underlying molecular genetic aberrations. With the help of these developments, patients with CLL are managed according to their individual risk with a watch-and-wait strategy, until cell count is above 200,000 leukocytes per μl blood [13].

So far, the origin of this type of leukemia was understood to be the result of tumor growth within the hematopoietic system. The clinical pictures are characterized by a highly variable course. This variability appears to arise from complex molecular alterations identified in malignant cells from patient subsets. So far, no markers could be identified, nor gene alterations defined that correlate with CLL.

Here, a case report is presented, that suggests that CLL could be induced by *Borrelia*.

2. CASE PRESENTATION

Therapy occurs with *Amanita phalloides* (zert. Riede) D2 dilution and *Terebinthina laricina* D1 from herbamed, CH. The patient was born in 1967 and works as judicial officer. His family has a history of cancer incidence. His uncle was diagnosed with leukemia six years ago, and died five years ago. His great grandmother died from gastrointestinal carcinoma. Recently, his father was diagnosed to suffer from CLL.

CLL was first diagnosed in March 2012, appearing progredient. Immune cytochemistry revealed B-lymphatic population (63%) with expression of CD19, CD20, CD22, CD11c, CD79b and FMC7 and no expression of CD23, CD10 and TdT. Kappa light chain restriction was found. This expression profile, and the infiltration of the bone marrow by a B-cell population correlates with a clonal population of B-cells: An eight mm long bone marrow was analysed with Giemsa staining, Fe-, PAS- and silverstain. In addition here CD3, CD10, CD20, CD23, Ki67, CD79A and TDT were tested. Microscopy revealed alteration of the bone structure, with hyper-cellular regions, infiltration (95%) with small lymphoid cells that carry slightly irregular nuclei and less cytoplasm. These show CD20 and CD79A but not CD10, CD23 and TDT expression. With the proliferation marker Ki67 they show a fraction of 5% proliferative cells. This cytological result correlates with an infiltration of the bone marrow as chronic lymphatic leukemia, induced by mature B-cells. Fluorescence in situ hybridization for detection of IGH-CCND1 rearrangement, 6q21 or 6q23 deletion, ATM deletion, trisomie 12, 13q14 deletion, TP53 deletion in 100 nuclei revealed no abnormality in these gene regions. Registration into a German Cancer Register occurred in March 2012. Chemotherapy and Antibody therapy were recommended. The patient decided to wait.

Amanita therapy starts in July 2012 (Fig. 1 arrow A) at a cell count of 58,000 leukocytes per μl blood. This leukocyte level is yet too low for conventional treatment, like R-CHOP. The patient decides to undertake a therapy attempt with *Amanita*. Body weight is 77 kg, he loses weight during the therapy through diets. Initially no additional disease was diagnosed. He shows initially no severe symptoms of leukemia, no lymph node swelling, no frequent infections. The spleen is slightly enlarged. The erythrocyte cell count is at $4.5 \times 10^6/\mu\text{l}$ blood at low level within the normal range. No other tumor specific therapy is applied. Adjuvant uptake of additional essential fatty acids - to enhance fluidity of cell membranes and to provide raw material for prostaglandins, i.e. immune cell hormones [14]- iron (orally) and zinc (cutaneous) is applied. Noxes, i.e. long flights or radiation are avoided as far as possible. The standard dosage of 4×10 drops of *Amanita phalloides* D2 per day is applied. This dosage correlates with the uptake of 100 ml within two months. This dosage, 100 ml, correlates with the inhibition of 50% of all

RNAP molecules in all cells. The intake per linguale ensures a free way of the drug through the oral mucosa to the metabolically most active cells. For monitoring of the therapy, the regular measurement of following parameter is arranged:

1. Cell count of leukocytes for monitoring of cell growth or cellular lysis or migration activity.
2. Differential blood count for monitoring anemia appearance.
3. Liver enzymes gamma-glutamyl transferase (GGT), glutamate-oxalacetate-transaminase (GOT), glutamate-pyruvate-transaminase (GPT), which occur in serum upon lysis or damage of liver cells, for monitoring possible intoxication of the liver with amanitin (Table 1).
4. Lactate- dehydrogenase (LDH) in serum. This enzyme is present in all cells, the occurrence in serum shows lysis of cells. LDH levels increase in all events resulting in cell degradation, i.e. myocardial or kidney infarction, embolism, autoimmunity, anemia, infectious diseases, or lysis of tumor cells.

And other clinical chemistry parameters according necessity.

The initial exponential growth of leukocytes reveals a period of 40 days for duplication (Fig. 1. initial part of graph). Amanita therapy starts in July 2012. Kappa light chains are diagnosed to be high. After begin of the Amanita therapy (Fig. 1 time 0, arrow A) leukocyte count still raises exponentially for two weeks, but then drops as expected. The spleen size before the therapy was 200x85 mm. It shrinks to 170 x 78 mm in September 2012. For eight months, the therapy seems to stabilize the disease sufficiently. In September 2012, the patient suffers from abdominal pain. A reduction of the dose to 1 x 5 drops per day occurs, and the pain disappears.

After some days, the standard dose of 4 x 10 drops per day is applied again. LDH levels (Fig. 1 dots) vary. In the beginning of the Amanita therapy they increase as expected: the immune system usually reacts and digests tumor cells.

Ten months after beginning the Amanita therapy, abdominal swollen lymph nodes appear. One year after begin of the therapy, the patient suffers from abdominal pain, edema in the legs and cramps. He suffers a freak accident in cold water with paralysis and swollen legs. These symptoms do not correlate with CLL nor are known side effects of the Amanita therapy. In addition LDH levels increase. Usually, under Amanita therapy LDH levels rise in conjunction with loss of tumor cells. This is not the case here, LDH increases and B-cell levels increase as well. Here cellular destruction is accompanied with B-cell growth. Severe inflammation symptoms occur, C-reactive protein (CRP) is high and anti-Borrelia IgM and IgG are positive. This leads to diagnosis of a fresh Borrelia infection. Anti-Borrelia IgG level is at 2.9 RE/ml and anti-Borrelia IgM is above 200 RE/ml. Corresponding leukocyte level is at 156,300 cells/µl. Immediately, in addition to *Amanita phalloides* D2 4 x 10 drops per day, *Terebinthina laricina* D1 2 x 10 drops per day are applied (Fig. 1. arrow B). Two weeks after begin of Terebinthina therapy, leukocyte level drops to 92,000 cells/µl.

The patient continues to suffer cramps at night with abdominal pain. During a subsequent vacation in the mountains in Südtirol, he suffers a fresh tick bite with the onset of erythema migrans. He treats the tick bite locally with some drops of Terebinthina (Fig. 1. arrow C). A month later, leukocyte count is back to 155,700 cells/µl. The patient remarks that his "inner fire" disappeared. Leukocyte levels now continuously decrease. In November 2013 he suffers a Herxheimer reaction with micturition problems. The Terebinthina treatment is

Table 1. Clinical chemistry monitoring

	Jul 2013	Nov 2013	Jan 2014	Jun 2014	Jan 2015
GOT [<34;U/l]	12	14	<8	11	19
GPT [7-40;U/l]	17	8	10	18	16
GGT (<73;U/l]	21	15	13	16	23
Lipase [12-53;U/l]	56	44	45	86	51
Creatinine [0.7-1.3;mg/dl]	1.16	3.45	1.63	1.76	1.42

Given are selected parameters [normal range; unit]. Liver enzymes GOT, GPT and GGT remain within the normal range. Creatinine is above normal range in this patient before treatment. During Herxheimer reaction (Nov2013) it increases showing affection of the kidney, with fast recovery. High lipase shows involvement of pancreas

completed (Fig. 1 arrow D). Creatinine level increases to 3,45 mg/dl (Table 1) showing involvement of the kidney. The patient drinks more than three liters of juices and tea per day, and the creatinine value decreases. Borrelia specific symptoms fade, lymph nodes ebb away, spleen size becomes normal, anxiety vanishes.

Amanita is further applied, leukocyte level decreases faster than before the Herxheimer reaction. At a cell count of 17,000/ μ L Amanita uptake is stopped as well in January 2014 (Fig. 1. arrow E). Since March 2014 Leukocyte level remain stable in a normal range.

CRP levels, indicating inflammations raised from 8.8 mg/l in December 2012 to 33.2 in September 2013. Maximum level is 35.1 in December 2013, during the therapy with Terebinthina. After the Herxheimer reaction it drops to 18.7 and continuously decreases since then (Fig. 1).

Thrombocytes decrease during the Amanita therapy within the normal range continuously, and increase again after the end of therapy. Liver enzymes remain in the normal range, meaning that no liver damage occurs through the therapies.

Anti-Borrelia IgG/IgM, initially in July 2013 at 2.9/>200 RE/ml reached 2.5/>200 RE/ml in September 2013 (before the Herxheimer reaction during Terebinthina therapy), and 3.2/>200 RE/ml in January 2014 (end of therapies). The expected shift from IgM to IgG does not occur.

Follow up with further monitoring will occur. So far, leukocyte levels still decrease and are actually at around 3,600 cells/ μ L blood. Initial duplication period of leukocytes is 40 days. Today, more than a year after remission of the leukemia, about nine cycles of duplication of tumor cells were possible. As no increase but decrease of leukocyte level is visible, a minimal residual disease is not expected.

3. DISCUSSION

To date, CLL is viewed as neoplasia with a tumor specific mutation that leads to malignant growth of cells. Here, the therapy of a patient with CLL and additional Borrelia infection with both *Amanita phalloides* and *Terebinthina laricina* leads to healing of both, the leukemia and the borreliosis. Usually, Amanita therapy can stabilize CLL, so far no remission was observed.

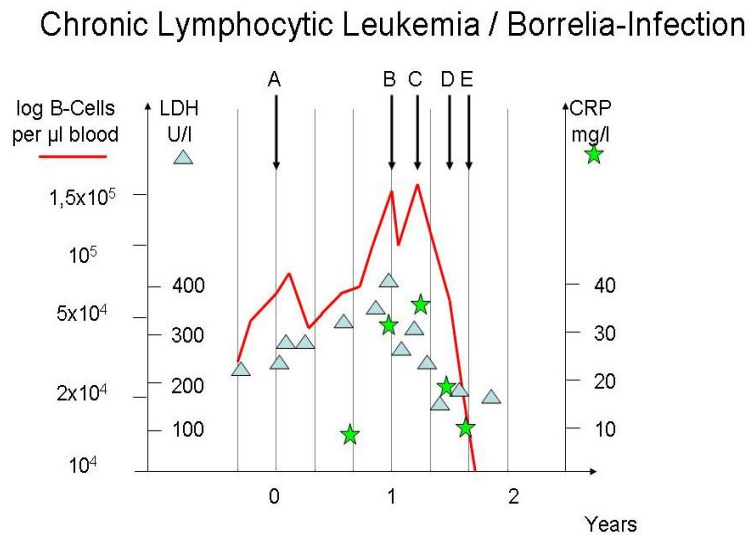


Fig. 1. Amanita phalloides and Terebinthina laricina treatment
 Leukocyte level is indicated as red line, LDH levels as triangles, CRP levels as stars.
 A. Therapy start with Amanita phalloides D2 4 x 10 drops per day.
 B. Additional therapy with Terebinthina laricina D1 2 x 10 drops per day.
 C. Tick bite in South Tyrol.
 D. Herxheimer Reaction end of Terebinthina laricina therapy.
 E. End of Amanita therapy.
 Leukocyte level today: 3,700 cells/ μ l blood

A fresh *Borrelia* infection might appear with erythema migrans in about 10 percent of all cases. *Borrelia* can persist without any symptoms. Years after a tick bite, usually rheumatic disorders lead to diagnosis of *Borrelia* infection. A weakened immune system might lead to an outbreak of the disease. It could be argued, that leukemia weakens the immune system and let the *Borrelia* grow. This does not seem to be the case. *Amanita phalloides* is a reliable drug, efficiently inhibiting tumor growth of cells for years. In the patient presented here, *Amanita* treatment fails after eight months. Leukocytes grow, despite *Amanita* treatment, LDH increases showing destruction of cells, and CRP levels increase. Severe symptoms of borreliosis appear in conjunction with leukocyte proliferation. Therefore, not malignant growth of cells might occur, but *Borrelia* induced growth of leukocytes, combined with cell destruction and inflammation.

These findings lead to the supposition that the *Borrelia* infection could appear as CLL.

In the serum of the patient, CRP levels increase ten months after begin of the *Amanita* therapy, pointing towards an inflammation process. *Amanita* therapy can lead to inflammation symptoms, so far not accompanied with an elevation of CRP. Therefore elevated CRP level might point towards a bacterial infection.

In B-cells, usually unspecific IgM then specific IgM is produced first after infection, after some weeks the same antibody specificity is shifted to IgG. In case of this patient, this shift does not occur. This is frequent in patients with *Borrelia* infection as well without CLL (unpublished results). Meaning the IgM to IgG shift is irreversibly blocked. The question remains, how *Borrelia* is able to avoid the shift and thereby weaken the immune response. IgM responses are humoral and independent from the potent T-cell response. B-cell activation by *Borrelia* in lymph nodes is known, and reveals IgM-skewed isotype [6]. *Borrelia* infection in bone marrow might activate B-cells with IgM skewed isotype to proliferation. This would explain the histological diagnosis of a CLL in bone marrow from this patient, containing 63% B-cells and the finding, that IgM response does not shift to IgG.

Why can *Amanita phalloides* initially break the activity of B-cell growth? Amanitin inhibits RNAP in all cells. In tumor cells RNAP is fully used, and therefore a partial inhibition reduces the growth

activity there. Obviously B-cell proliferation in CLL shows malignant signs, eventually switch gene over expression.

Why did the *Amanita* therapy fail after some months? Experience shows, that a once successful therapy leads to stabilization for years, without selecting resistance. This is due to the effect, that the drug reprograms the tumor cells without selective pressure. Obviously the bacteria find a way to further circumvent the immune system and to undermine the *Amanita* effect, leading to further progression of the disease. This finally revealed their presence.

Other infectious agents are associated with a number of tumor diseases. *Borrelia* infection was diagnosed in a patient with chronic lymphocytic leukemia. This neuroborreliosis mimics leukemic meningeosis. The involvement of the central nervous system is a rare complication in progressive CLL disease [15]. The spirochete *Treponema pallidum* can mimic tumor disease [16]. Thus spirochete infection initiates hyperproliferative growth of tissue. Oncogenic viruses like Human Papilloma virus or Hepatitis C virus induce hyperproliferative lesions and cancer [17,18].

This is the first case presented, that a *Borrelia* infection could mimic CLL. The questions arise, how many of all apparent CLL are *Borrelia* infections, how many other tumors originate from infections, and how infectious agents can induce proliferation without proliferative mutation of the host cell.

4. CONCLUSION

It is accepted, that genetic alterations induce malignant tumor formation. Tumors can be induced by a proliferative mutation, like in ALL-1 leukemia [19]. The molecular mechanisms in other tumor forming processes like CLL are unknown. Despite great effort no genetic alteration could be associated with these diseases.

Another type of tumor induction could originate from an infectious agent. This process seems to be independent from genetic alteration of the human cell. Proliferative B-cells disappear completely due to the therapy presented here. Half a year later, still anti-*Borrelia* IgM instead of IgG are persistent, indicating, the original proliferating B-cells still are present. Complete reversion indicates that the B-cells have no

proliferative mutation. *Borrelia* might induce proliferation of B-cells directly.

This finding indicates that physicians should observe caution when diagnosing patients and planning the therapy. No chemotherapy should be applied to freshly diagnosed patients. An exclusion of *Borrelia* infection is indicated first. Even if antibody titers are negative, a therapy with *Terebinthina laricina* for some weeks is indicated, because the diagnostic tests are not sufficiently precise now a days.

Undetected and unexpected infections could be the cause of many tumor diseases. All multiforme tumor appearances like glioblastoma should be revisited.

CONSENT AND ETHICAL APPROVAL

Written informed consent was obtained from the patient for publication of this case report and any accompanying images. Due to therapy with existing phytotherapeutic/homeopathic drugs, no ethical approval was necessary.

ACKNOWLEDGEMENTS

I thank the patient for patience, confidence, openness and curiosity. The study was not supported by a sponsor.

COMPETING INTERESTS

Author has declared that no competing interests exist.

REFERENCES

1. Riede I. Switch the Tumor Off: From Genes to Amanita Therapy. American Journal of Biomedical Research. 2013; 1(4):93-107. DOI:10.12691/ajbr-1-4-5. Available:<http://www.sciepub.com/ajbr/content/1/4>
2. Rozovskaia T, Feinstein E, Mor O, Foa R, Blechman J, Nakamura T, Croce CM, Cimino G, Canaani E. Upregulation of Meis1 and HoxA9 in acute lymphocytic leukemias with the t(4:11) abnormality. Oncogene. 2001;20(7):874-8.
3. Riede I. Tumor therapy with *Amanita phalloides* (Death Cap): Stabilization of B-cell chronic lymphatic leukemia. J. Altern. Complement. Med. 2010;16;10:1129-1132. DOI:10.1089/acm.2010.0035.

- Available:<http://www.liebertonline.com/doi/pdfplus/10.1089/acm.2010.0035>
4. Ramesh G, Borda JT, Gill A, Ribka EP, Morici LA, Mottram P, Martin DS, Jacobs MB, Didier PJ, Philipp MT. Possible role of glial cells in the onset and progression of Lyme neuroborreliosis. J Neuroinflammation. 2009;6:23.
 5. Ramesh G, Borda JT, Dufour J, Kaushal D, Ramamoorthy R, Lackner AA, Philipp MT. Interaction of the Lyme disease spirochete *Borrelia burgdorferi* with brain parenchyma elicits inflammatory mediators from glial cells as well as glial and neuronal apoptosis. Am J Pathol. 2008; 173(5):1415-27.
 6. Halperin JJ. Neurologic Manifestations of Lyme Disease. Curr Infect Dis Rep. 2011;13(4):360-6. DOI:10.1007/s11908-011-0184-x.
 7. Earl TJ. Cardiac manifestations of Lyme disease. Med Health R I. 2010;93(11):339-41.
 8. Tunev SS, Hastey CJ, Hodzic E, Feng S, Barthold SW, Baumgarth N. Lymphadenopathy during lyme borreliosis is caused by spirochete migration-induced specific B cell activation. Plos Pathog. 2011;7(5):e1002066. DOI:10.1371/journal.ppat.1002066.
 9. Schöllkopf C, Melbye M, Munksgaard L, Ekström Smedby K, Rostgaard K, Glimelius B, Chang ET, Roos G, Hansen M, Adami HO, Hjalgrim H. *Borrelia* infection and risk of non-Hodgkin lymphoma Blood. 2008;111(12):5524–5529. DOI:10.1182/blood-2007-08-10961.
 10. Ang CW, Notermans DW, Hommes M, Simoons-Smit AM, Herremans T. Large differences between test strategies for the detection of anti-*Borrelia* antibodies are revealed by comparing eight ELISAs and five immunoblots. Eur J Clin Microbiol Infect Dis. 2011;30(8):1027-32. DOI:10.1007/s10096-011-1157.
 11. Riede,I. *Terebinthina laricina* in Borreliosis: Comparison with Antibiotic Therapies J. Homeop. Ayurv. Med. 2012;1:110. DOI:10.4172/2167-1206.1000110. Available:<http://www.omicsgroup.org/journals/2167-1206/2167-1206-1-110.php?aid=5682>
 12. Lloyd VE. The Jarisch-Herxheimer Reaction. Br J Vener Dis. 1945;21(1):42-4.
 13. Wendtner CM, Schmitt B, Bergmann M, Röhnisch T, Buhmann R, Hallek M. New aspects on the pathogenesis, diagnostic

- procedures, and therapeutic management of chronic lymphocytic leukemia. *Int J Hematol.* 2001;73(1):32-8.
14. Riede I. Membrane fluidity: About the origin of autoimmunity. *Open Journal of Immunology.* 2014;4:9-13. DOI:10.4236/oji.2014.41002. Available:<http://dx.doi.org/10.4236/oji.2014.41002>
15. Schweighofer CD, Fätkenheuer G, Staib P, Hallek M, Reiser M. Lyme disease in a patient with chronic lymphocytic leukemia mimics leukemic meningeosis. *Onkologie.* 2007;30(11):564-6. Epub 2007Oct16.
16. Teo SY1, Morris G, Fairley I. The great mimic: syphilis mimicking testicular tumour. Conservative management using antibiotics alone with testicular sparing. *Int J STD AIDS.* 2013;24(5):415-8. DOI:10.1177/0956462412472833.
17. Morshed K1, Polz-Gruszka D2, Szymański M3, Polz-Dacewicz M2. Human Papillomavirus (HPV) - Structure, epidemiology and pathogenesis. *Otolaryngol Pol.* 2014;68(5): 213219. DOI:10.1016/j.otpol.2014.06.001. Epub2014Jun27.
18. Herzer K, Gerken G, Hofmann TG. Hepatitis C-associated liver carcinogenesis: Role of PML nuclear bodies. *World J Gastroenterol.* 2014;20(35):12367-12371.
19. Cimino G, Moir DT, Canaani O, Williams K, Crist WM, Katzav S, Cannizzaro L, Lange B, Nowell PC, Croce CM, et al. Cloning of ALL-1, the locus involved in leukemias with the t(4;11)(q21;q23), t(9;11)(p22;q23), and t(11;19)(q23;p13) chromosome translocations. *Cancer Res.* 1991;51(24):6712-4.

© 2015 Riede; This is an Open Access article distributed under the terms of the Creative Commons Attribution License (<http://creativecommons.org/licenses/by/4.0>), which permits unrestricted use, distribution, and reproduction in any medium, provided the original work is properly cited.

Peer-review history:

The peer review history for this paper can be accessed here:
<http://www.sciencedomain.org/review-history.php?iid=947&id=12&aid=8421>