

# Morphometric Analysis of Great Cardiac Vein and its Clinical Implication- A Cadaveric Study

JOLLY AGARWAL<sup>1</sup>, ANURAG AGRAWAL<sup>2</sup>, VIRENDRA KUMAR<sup>3</sup>, DN SINHA<sup>4</sup>

## ABSTRACT

**Introduction:** Great Cardiac Vein (GCV) is the longest venous vessel of heart. It is the main tributary of the coronary sinus and anterior wall of the left ventricle and interventricular septum are drained by GCV.

**Aim:** To study the morphometry of GCV and its variations in north-western region of India.

**Materials and Methods:** The present cross-sectional study was conducted in the Department of Anatomy, SRMS IMS, Bareilly, Uttar Pradesh, India, from January 2012 to December 2013. Thirty hearts of different ages and of both sexes (22 males and 8 females) procured from cadavers in the department were studied. The length and diameter of GCV were measured with help of thread and digital vernier callipers. The mean, standard

deviation and correlation were calculated using Microsoft office excel 2007.

**Results:** In present study, 30 hearts (mean age: 41.83±12.37 years) of both sexes (22 males and 8 females) were studied. The mean length of GCV was 79.26±22.78 mm and the range of length was from 55.50±27.57 to 112.33±36.07 mm. The mean diameter of GCV was 2.85±1.32 mm. The mean length of GCV in males was 83.26±22.05 mm, while in females, the mean length of GCV was 74.72±22.08 mm. The diameter of GCV was having significant relation with weight ( $r=-0.663$ ,  $p\text{-value}=0.0007$ ) and age group ( $r=0.481$ ;  $p\text{-value}=0.023$ ) in cadaveric males.

**Conclusion:** The present morphometric study of GCV provides data for measurement of interventional devices required during interventional procedure in Indian setting.

**Keywords:** Cadaver, Coronary, Diameter, Length

## INTRODUCTION

The main and longest tributary of coronary sinus is GCV. Coronary sinus is present in all hearts and it drains anterior wall of the left ventricle and interventricular septum [1]. GCV receives tributaries like left marginal vein that ascends along the left border of the heart, obtuse marginal vein, left inferior veins from left ventricle and vein of Marshall [2]. GCV and the middle cardiac vein is the most stable tributary of the coronary sinus [3]. The anastomosis between GCV and middle cardiac vein forms an arch at the apex of heart [4].

Brocq and Mouchet's arterio-venous triangle is formed by the intersection of the GCV, the circumflex artery and the anterior interventricular artery branches of the left coronary artery. The coronary vessels, pericardium, myocardium are identified by doing intravascular ultrasound in the area of Brocq and Mouchet triangle. GCV also forms one of the boundaries of Brocq and Mouchet triangle and this triangle is commonly used for Percutaneous In-situ Coronary venous Arterialisations (PICA) [5].

The length of GCV is important for providing data about left ventricular leads in the postero-lateral branches of the coronary sinus. Therefore, morphology and morphometry of GCV assumes clinical importance for invasive cardiac procedures. So that management of patients will be improved and chances of complications are less during interventional procedures [6]. During drainage of GCV into coronary sinus, GCV forms an obtuse angle with coronary sinus [7].

The GCV is the most stable tributary of coronary sinus, thus it may be more suitable for interventional devices [3]. Therefore, present study was conducted to study the dimensions of GCV (diameter and length) which may be used in future for interventional devices (left ventricular leads) in India.

Till date, very few studies [6,8] have been reported for GCV regarding its morphometry and morphology particularly in north Indian population. Hence, present study was conducted to study the morphometry of GCV and its variations in north western region.

## MATERIALS AND METHODS

This cross-sectional study was performed in the Department of Anatomy, SRMS IMS, Bareilly on 30 hearts from embalmed cadavers, from January 2012 to December 2013. The present study was exempted from institutional ethical clearance as all hearts were obtained from voluntarily donated cadavers to the Department of Anatomy. The prior written consent from the immediate relatives was taken for use of body for research purpose.

**Inclusion criteria:** Thirty hearts, procured from the cadavers, aged between 15-65 years, available in the Department of Anatomy, SRMS IMS, Bareilly, Uttar Pradesh, were included.

**Exclusion criteria:** The diseased, decomposed, and hearts with congenital anomaly were excluded from the study.

### Study Procedure

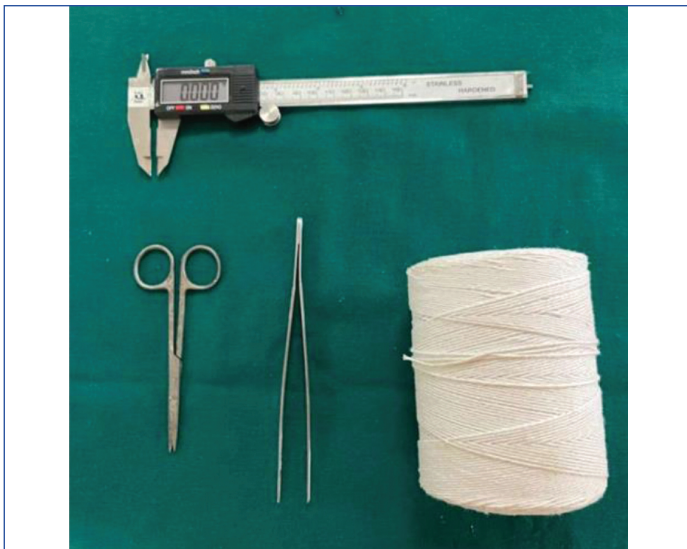The hearts were cleaned gently under running water to remove any blood clots, if any. The human hearts were fixed in 10% formalin and dissected. The morphology of GCV in human hearts was observed. The length and diameter of GCV (at the site of opening into coronary sinus) was measured with the help of digital Vernier callipers and thread [Table/Fig-1-3]. The authors noted information about weight and age of cadavers from departmental records which were submitted at the time of death. Hearts were divided into 5-year age groups because number of hearts available was less in each age group.

## STATISTICAL ANALYSIS

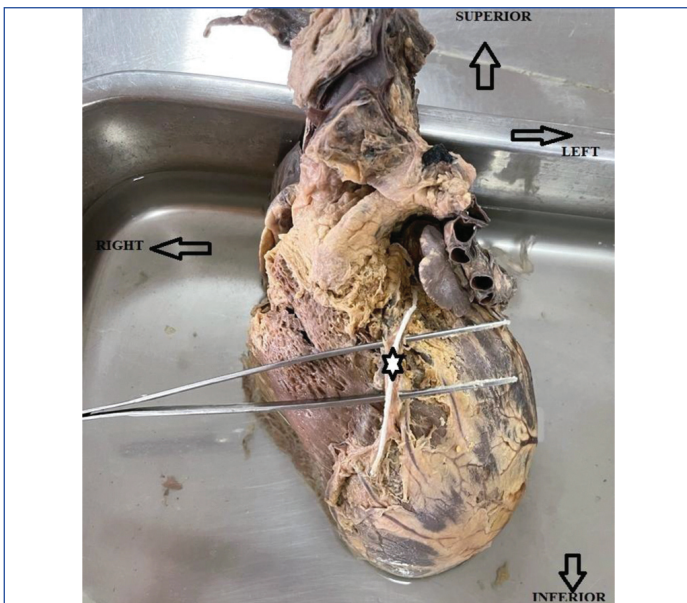
The data were analysed by Microsoft Office Excel 2007 and presented as mean value and Standard deviation. Data were statistically analysed using Pearsons Correlation and Chi-square test.

## RESULTS

The mean age of cadavers was 41.83±12.37 years. The 22 hearts were from males and 8 hearts were from females. In this study,



[Table/Fig-1]: Instruments used for measuring GCV.



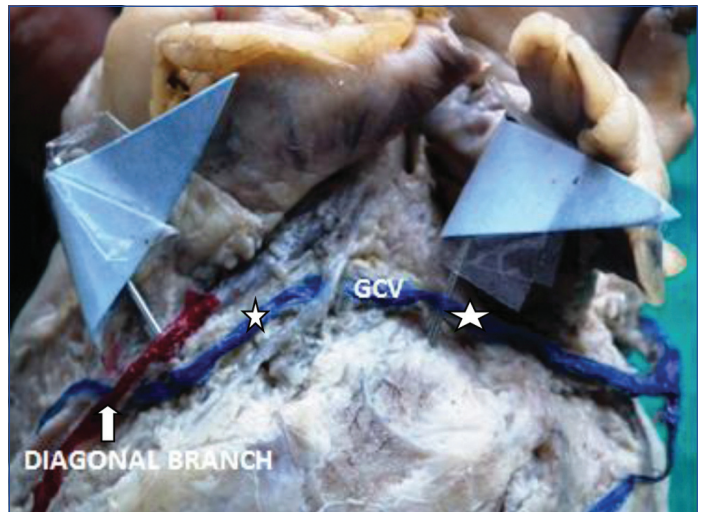[Table/Fig-2]: Diagram showing measurement of length of GCV (Heart put in anatomical position and white filled star showing measurement of GCV with the help of white thread).



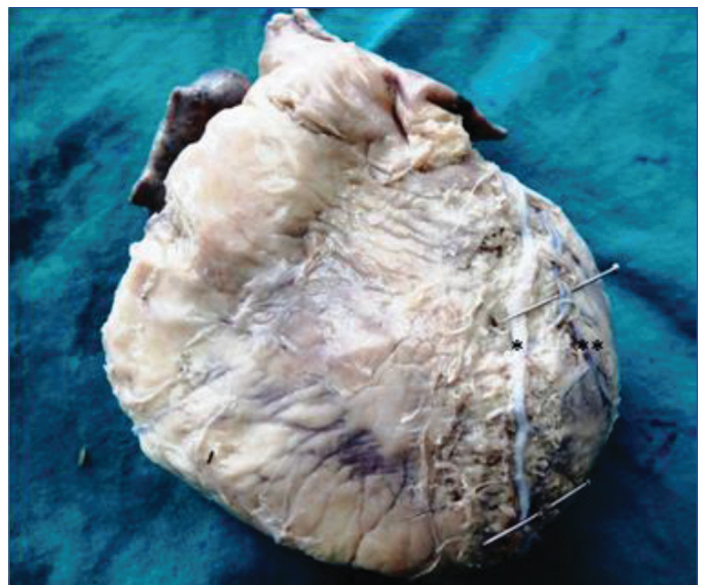[Table/Fig-3]: Diagram showing measurement of diameter of GCV with the help of digital vernier callipers.

the authors found the presence of GCV on entire length of anterior interventricular sulcus in 13 (43.33%) cadaveric hearts whereas in 17 (56.67%) cadaveric hearts, the GCV was present in upper 2/3 part of anterior interventricular sulcus. There was only 1 (3.33%) heart, where the GCV was starting from the apex of heart, while in rest of

the hearts GCV start from anterior interventricular sulcus. Majority of GCV were straight but in 1(3.33%) heart GCV showed kinkings. The diagonal branches of left coronary artery were superficially crossed by GCV in 1(3.33%) heart [Table/Fig-4]. GCV was on left-side of anterior interventricular artery in 1 (3.33%) heart [Table/Fig-5].



[Table/Fig-4]: Great Cardiac Vein (GCV) (white star) superficially crossed by diagonal branches (white arrow) of left coronary artery.



[Table/Fig-5]: Presence of Great Cardiac Vein (GCV) (single black star) on left-side of anterior interventricular artery (two black star) on sternocostal surface of heart.

The present study also revealed that Vieussens valve was present in 23 (76.66%) GCV. The mean length of GCV was  $79.26 \pm 22.78$  mm and the range of length was from  $55.50 \pm 27.57$  to  $112.33 \pm 36.07$  mm. The mean diameter of GCV was  $2.85 \pm 1.32$  mm and its range was from  $0.8 \pm 0.41$  to  $4.2 \pm 1.16$  mm. The statistical analysis also depicted the diameter of GCV is having significant variation in relation age of cadaver ( $r=0.376$  and  $p=0.0403$ ) [Table/Fig-6].

The mean length of GCV in males was  $83.26 \pm 22.05$  mm, while in females the mean length of GCV was  $74.72 \pm 22.08$  mm. Therefore the length of GCV was less in females as compared to males. The mean diameter of GCV in males was  $2.88 \pm 1.43$  mm and in females was  $2.87 \pm 0.75$  mm. Therefore, diameter of GCV in males and females are comparable [Table/Fig-7].

The diameter of GCV was having significant relation with weight of cadaver in male heart ( $r=-0.663$ ,  $p\text{-value}=0.0007$ ). The diameter of GCV was found to be significantly lower as compared to higher age group ( $r=0.481$ ;  $p\text{-value}=0.023$ ) in males and significant statistically. The relationships between length and age ( $r\text{-value} 0.15$ ,  $p\text{-value} 0.49$ ) and length and weight ( $r\text{-value} 0.19$ ,  $p\text{-value} 0.85$ ) were statistically insignificant [Table/Fig-8].

Group (years)	No. of hearts	Length of great cardiac vein (mm)	Diameter of great cardiac vein (mm)	Average Weight of person (Kg)	Pearson correlation coefficient and p-value in between diameter and age of Great Cardiac Vein (GCV)	Pearson correlation coefficient and p-value in between diameter and weight	Pearson correlation coefficient and p-value in between length and age	Pearson correlation coefficient and p-value in between length and weight
16-20	2	74±5.65	1.34±0.21	50±2.83	r=0.376, p=0.0403	r=0.22, p=0.22	r=0.36, p=0.46	r=0.51, p=0.44
21-25	2	79±7.07	1.88±0.16	52±2.82				
26-30	2	55.5±27.57	0.8±0.41	64±1.31				
31-35	5	77.61±17.44	3.06±1.21	50.6±5.77				
36-40	4	74.21±35.44	2.74±1.18	49±10.73				
41-45	3	112.33±36.07	3.64±1.17	58.66±3.21				
46-50	5	76.04±16.77	2.18±1.29	60.8±11.69				
51-55	2	84.5±9.19	2.84±2.33	63.5±2.12				
56-60	3	81.90±6.24	4.2±1.16	70.66±18.58				
61-65	2	72±0.00	3.32±0.45	68±11.31				
Mean		79.26±22.78	2.85±1.32					

**[Table/Fig-6]:** Showing length and diameter of Great Cardiac Vein (GCV).

Great Cardiac Vein (GCV)	Number of hearts (n)	Mean±SD	Minimum	Maximum
Length (male)	22	83.26±22.05 mm	52 mm	147 mm
Length (female)	8	74.72±22.08 mm	26.83 mm	98 mm
Diameter (male)	22	2.88±1.43 mm	0.51 mm	5.48 mm
Diameter (female)	8	2.87±0.75 mm	1.5 mm	3.64 mm

**[Table/Fig-7]:** Showing length of Great Cardiac Vein (GCV) in male and female hearts.

Age groups (years)	No. of hearts (N=22)	Length of great cardiac vein (mm)	Diameter of great cardiac vein (mm)	Average weight of person (kg)	Pearson correlation coefficient and p-value in between diameter and age of Great Cardiac Vein (GCV)	Pearson correlation coefficient and p-value in between diameter and weight of cadaver
16-20	2	74±5.65	1.34±0.21	50±2.82	r=0.481, p=0.023	r=-0.663, p-value=0.0007
21-25	1	84	1.77	54		
26-30	2	55.5±27.57	0.8±0.41	56		
31-35	4	72.51± 15.24	3.45±0.96	52±5.59		
36-40	2	98±19.79	3±1.41	57±4.24		
41-45	2	131±32.62	4.05±1.34	57.5±3.53		
46-50	3	67.41±14.21	2.74±1.47	62±10.92		
51-55	2	84.5±9.19	2.84±2.33	63.5±2.12		
56-60	3	81.90±6.24	4.2±1.16	70.66±18.58		
61-65	1	72	3	60		

**[Table/Fig-8]:** Showing length and diameter of Great Cardiac Vein (GCV) in males.

There was a positive correlation between diameter of GCV and weight of cadaver in female heart but this relation was not statistically significant ( $r=0.34$ ,  $p\text{-value}=0.409$ ). The diameter of GCV was found to be lower as compared to higher age group and but was statistically insignificant ( $r=0.3$ ,  $p\text{-value}=0.47$ ). The relationships between length and age ( $r\text{-value}=0.107$ ,  $p\text{-value}=0.79$ ) and length and weight ( $r\text{-value}=0.423$ ,  $p\text{-value}=0.44$ ) were statistically insignificant [Table/Fig-9].

## DISCUSSION

The authors in the present study found the presence of GCV in entire length of anterior interventricular sulcus in 43.33% cadaveric hearts and its presence in upper 2/3 part of anterior interventricular sulcus in 56.67%. Kaczmarek M and Czerwiński F, found that the GCV in 17% cases came both into middle 1/3 and superior third of interventricular sulcus which also endorsed present findings that

Age groups (years)	No. of hearts (N=8)	Length of great cardiac vein (mm)	Diameter of great cardiac vein (mm)	Average weight of person (kg)	Pearson correlation coefficient and p-value in between diameter and age of Great Cardiac Vein (GCV)	Pearson correlation coefficient and p-value in between diameter and weight of cadavers
16-20	0	0	0	0	r=0.3, p=0.47	r=0.34, p=0.409
21-25	1	74	2	50		
26-30	0	0	0	0		
31-35	1	98	1.5	45		
36-40	2	50.43±33.38	2.49±1.40	41±8.48		
41-45	1	75	2.84	61		
46-50	2	89±12.72	1.35±0.21	64±16.97		
51-55	0	0	0	0		
56-60	0	0	0	0		
61-65	1	72±0.00	3.64	76		

**[Table/Fig-9]:** Showing length and diameter of Great Cardiac Vein (GCV) in females (mm).

the majority of the GCV covers upper 2/3 of anterior interventricular sulcus [8]. While in another study, it was observed that GCV originated from the cardiac apex in 57.4% of cases and from lower third of the anterior interventricular sulcus in 39.7% [9].

The present study showed that the GCV starts from the apex of heart (3.33%) and forms anastomotic arch with middle cardiac vein. Kaczmarek M and Czerwiński F, reported that in 25% cases GCV united at the apex of heart with the MCV, forming a large venous arc which endorsed the present study finding [8].

In the present study, the authors found that the length of GCV ( $79.26 \pm 22.39$  mm) was maximum in middle age group (41-45 years) whereas it was found lesser in early and late age group (mean maximum length- $112.33 \pm 36.07$  mm and mean minimum length  $72 \pm 00$  mm) though statistical analysis did not reveal any significant relationship. In one study, it was reported that maximum length of GCV which was measured from the beginning of the longest branch and finishing in the lower left part of coronary sulcus, amounted 25.53 cm, the minimum length 12.4 cm and the average length 17.7 cm [8].

The present study found that the mean diameter of GCV is  $79.26 \pm 22.78$  mm which is close to study of Kulkarni V et al., while the mean diameter of GCV is  $182.4 \pm 23.5$  mm from the study of Abbara S et al., [6,10]. These differences may be due to difference in study population. Comparison of findings in present study with contrast studies are summarised in [Table/Fig-10] [3,6,10-14]. The present study revealed that GCV was present in all hearts. Gilard M et al., also reported that two veins are consistently present: the middle cardiac vein and the GCV [11].

Authors	Great Cardiac Vein (GCV) (Diameter) (mean±SD) (mm)	Great Cardiac Vein (GCV) (Length) (mean±SD) (mm)	Sample size	Study place	Year of study
Zhaoming Z, [12]	$3.16 \pm 0.87$ mm	-	-	China	2013
Gilard M et al., [11]	$3.55 \pm 1.24$ mm	-	100	France	1998
El Maasarany S et al., [13]	$5.6 \pm 1.6$ mm	-	40	British	2005
Mazur M et al., [3]	2.5 to 5 mm	-	80	Poland	2015
Kulkarni V et al., [6]	$2.76 \pm 0.93$	$67.77 \pm 25.55$	52	South India	2022
Mehra L et al., [14]	$5.99 \pm 1.02$ mm	$96.23 \pm 22.52$	40	North India	2016
Abbara S et al., [10]	$5.6 \pm 1.3$ mm	$182.4 \pm 23.5$ mm	54	America	2005
Present study	$2.71 \pm 1.35$ mm	$79.26 \pm 22.78$	30	North-western India	2012-13

**[Table/Fig-10]:** Comparison of diameter and length of Great Cardiac Vein (GCV) from present study with others as reported in literature [3,6,10-14].

The GCV lies on the left-side of anterior interventricular artery in 60% and on the right-side of anterior interventricular artery 20%. Ortale JR et al., found that in 36 (97%) out of 37 specimens the anterior interventricular branch of the left coronary artery was accompanied by the anterior interventricular vein, with the vein usually located parallel and left to the artery [15]. Kaczmarek M and Czerwiński F, reported that anterior interventricular vein, in its course, accompanied the anterior interventricular branch of the left coronary artery in 83% of the cases and the vein was present parallel and left-side of the artery [8]. Ballesteros LE et al., reported that the GCV located to the left of the anterior interventricular artery in 77.9% [9]. All above studies endorsed finding of the present study that GCV most commonly present on left-side of anterior interventricular artery.

The GCV was observed in the lower 2/3 of interventricular sulcus on the right-side of anterior interventricular artery and in upper 1/3 on the left-side of the anterior interventricular artery (10%) in 3 hearts. In one heart, the authors observed that in the lower part of anterior interventricular sulcus the GCV was intertwined by anterior descending branch of left coronary artery (3.33%). Maric I et al., reported in one case out of 40 case that anterior interventricular vein (GCV) curved twice around the anterior interventricular branch of left coronary artery in their article [16]. Meguid EA and Rahman WA observed that in one case GCV curved around the anterior interventricular branch of left coronary artery [17].

Agarwal J et al., observed that 36.66% of the GCV anastomose with middle cardiac vein to form a complete venous ring surrounding the left ventricle [5]. The variation in respect to presence, location, and superficial and deep relationship of cardiac vein with single crossings of the anterior interventricular and circumflex branch of are rare but intertwined variation are important to understand the mechanism of vasculo-angiogenesis and clinical implications for catheter based procedures and surgeries in the region of coronary sulcus [18].

The GCV while passing through atrioventricular groove superficially crossed by diagonal branches of the descending branch of left coronary artery (6.66%). In one cadaveric heart, the beginning of GCV observed as having two tributaries which were located on either side of anterior interventricular artery in anterior interventricular groove and in one heart, the GCV lies deep to diagonal branches of anterior interventricular branch of left coronary artery (3.33%). In nine hearts the GCV lie deep to anterior interventricular artery (30%). The end part of the GCV crosses superficial to the circumflex artery at the level of left marginal vein [13]. Kaczmarek M and Czerwiński F, found in 39% of cases the GCV ran near the coronary sulcus over the diagonal and circumflex branches of left coronary artery, in another 39% GCV passed over the circumflex artery and simultaneously under the diagonal branches, in 8% cases, it ran over the diagonal branch and under the circumflex in 14% cases GCV ran under the diagonal and circumflex both the branches [8]. During postmortem, Vieussens valve of GCV may cause obstruction to passage of catheter [19].

Maros TN et al., found that the valve of Vieussens was present in 78%, but well developed in 6% of the cases [20], while other study reported that the Vieussens valve was present in 65.1% of hearts [21]. Zawadzkie M et al., reported that valve presence to vary from 65-87% [22]. In the present study, the authors observed the presence of Vieussens valve in 23 out of 30 hearts (76.66%) like other studies.

### Limitation(s)

The sample size of the present study was small.

### CONCLUSION(S)

There was gender-wise difference in length of GCV while diameter is comparable in GCV of male and female human hearts. The morphometric study of GCV provides data for interventional devices required during interventional procedure of heart. This study also provides data for GCV in Indian setting. It is recommended to conduct the multicentric studies on a larger sample size to endorse the findings of this study.

### REFERENCES

- Zabina B, Singla RK, Sharma RK, Bala N. Morphological and morphometric study of coronary sinus in North Indian Population. *J Clin Diagn Res.* 2017;11(9):15-19.
- Loukas M. Heart. *Gray's anatomy: The Anatomical Basis of Clinical Practice.* Standring S (ed): Elsevier, London; 2021. 42<sup>nd</sup> edition: 1068-96.
- Mazur M, Holda M, Koziej M, Klimek-Piotrowska W, Kuniewicz M, Matuszyk A, et al. Morphology of tributaries of coronary sinus in humans-corrosion casting study. *Folia Medica Cracoviensia.* 2015;55(2):05-13.
- Agarwal J, Agarwal A, Sinha DN, Kumar V. Morphological study of middle cardiac vein in human hearts of north western UP and its application for interventional procedure. *Ind J Clin Anat Physiol.* 2020;7(2):130-33.

- [5] Agarwal J, Agrawal A, Sinha DN, Virendra. Study of BROCC and Mouchet triangles in human hearts-A cadaveric study and its clinical implication. *IP Indian J Anat Surg Head, Neck Brain*. 2020;6(2):36-39.
- [6] Kulkarni V, Geethanjali HT, Lokanathan TH. Morphometry of the great cardiac vein in cadaveric hearts of South Indian Origin. *Cureus*. 2022;14(3):02-08.
- [7] Ankolekar VH, Quadros LS, D'Souza AS. Morphometric and morphological variations of coronary venous system and its tributaries—an anatomical study. *Journal of Pharmaceutical and Biomedical Sciences*. 2013;34(34):1663-69.
- [8] Kaczmarek M, Czerwiński F. Assessment of the course of the great cardiac vein in a selected number of human hearts. *Folia Morphologica*. 2007;66(3):190-93.
- [9] Ballesteros LE, Ramirez LM, Forero PL. Study of the coronary sinus and its tributaries in Colombian subjects. *Revista Colombiana de Cardiología*. 2010;17(1):09-15.
- [10] Abbara S, Cury RC, Nieman K, Reddy V, Moselewski F, Schmidt S, et al. Noninvasive evaluation of cardiac veins with 16-MDCT angiography. *American Journal of Roentgenology*. 2005;185(4):1001-06.
- [11] Gilard M, Mansourati J, Etienne Y, Larlet JM, Truong B, Bosch J, et al. Angiographic anatomy of the coronary sinus and its tributaries. *Pacing and Clinical Electrophysiology*. 1998;21(11):2280-84.
- [12] Zhaoming Z. Applied anatomical study of coronary sinus and its tributaries. *J Luzhou Med Coll*. 2013:2003-02.
- [13] El-Maasarany S, Ferrett CG, Firth A, Sheppard M, Henein MY. The coronary sinus conduit function: Anatomical study (relationship to adjacent structures). *EP Europace*. 2005;7(5):475-81.
- [14] Mehra L, Raheja S, Agarwal S, Rani Y, Kaur K, Tuli A. Anatomical consideration and potential complications of coronary sinus catheterization. *J Clin Diagn Res*. 2016;10(2):AC12-15.
- [15] Ortale JR, Gabriel EA, lost C, Marquez CQ. The anatomy of the coronary sinus and its tributaries. *Surgical and Radiologic Anatomy*. 2001;23(1):15-21.
- [16] Marić I, Bobinac D, Ostojčić LJ, Petković M, Dujmović M. Tributaries of the human and canine coronary sinus. *Cells Tissues Organs*. 1996;156(1):61-69.
- [17] Meguid EA, Rahman WA. An anatomical study on the human coronary sinus and its tributaries. *Bulletin of Alexandria Faculty of Medicine*. 1997;32(2):285-97.
- [18] Bales GS. Great cardiac vein variations. *Clinical Anatomy: The Official Journal of the American Association of Clinical Anatomists and the British Association of Clinical Anatomists*. 2004;17(5):436-43.
- [19] Corcoran SJ, Lawrence C, McGuire MA. The valve of Vieussens: An important cause of difficulty in advancing catheters into the cardiac veins. *Journal of Cardiovascular Electrophysiology*. 1999;10(6):804-08.
- [20] Maros TN, Racz L, Plugor S, Maros TG. Contributions to the morphology of the human coronary sinus. *Anatomischer Anzeiger*. 1983;154(2):133-44.
- [21] Duda B, Grzybiak M. About variability of Vieussens valve in the adult human heart. *Folia Morphologica*. 2000;59(1):43-45.
- [22] Zawadzkie M, Pietrasik A, Pietrasik K, Marchel M, Ciszek B. Endoscopic study of the morphology of Vieussens valve. *Clinical Anatomy: The Official Journal of the American Association of Clinical Anatomists and the British Association of Clinical Anatomists*. 2004;17(4):318-21.

#### PARTICULARS OF CONTRIBUTORS:

1. Associate Professor, Department of Anatomy, GDMC, Dehrakhas, Patel Nagar, Dehradun, Uttarakhand, India.
2. Professor and Head, Department of Pulmonary Medicine, GDMC, Dehrakhas, Patel Nagar, Dehradun, Uttarakhand, India.
3. Ex-Professor, Department of Anatomy, SRMSIMS, Bareilly, Uttar Pradesh, India.
4. Ex-Professor, Department of Anatomy, GMC, Haldwani, Uttarakhand, India.

#### NAME, ADDRESS, E-MAIL ID OF THE CORRESPONDING AUTHOR:

Jolly Agarwal,  
Associate Professor, Department of Anatomy, GDMC, Dehrakhas, Patel Nagar,  
Dehradun, Uttarakhand, India.  
E-mail: drjolly21177@gmail.com

#### PLAGIARISM CHECKING METHODS: [Jain H et al.]

- Plagiarism X-checker: Sep 13, 2022
- Manual Googling: Dec 01, 2022
- iThenticate Software: Dec 22, 2022 (21%)

#### ETYMOLOGY: Author Origin

#### AUTHOR DECLARATION:

- Financial or Other Competing Interests: None
- Was Ethics Committee Approval obtained for this study? No
- Was informed consent obtained from the subjects involved in the study? Yes (from relatives)
- For any images presented appropriate consent has been obtained from the subjects. NA

Date of Submission: **Aug 31, 2022**  
Date of Peer Review: **Oct 03, 2022**  
Date of Acceptance: **Dec 23, 2022**  
Date of Publishing: **Feb 01, 2023**