

Bertolotti's Syndrome: An Underdiagnosed Cause of Lower Back Pain; A Case Report of Two Cases and Current Management Options

Ling Lee Siang^{1*}, Seo Soon Teck¹ and Sivapathasundaram A/L C. Nadarajah¹

¹Department of Orthopaedics, Hospital Melaka, Jalan Mufti Haji Khalil, 75400 Melaka, Malaysia.

Authors' contributions

This work was carried out in collaboration among all authors. All authors read and approved the final manuscript.

Article Information

Editor(s):

(1) Dr. Ikem, Innocent Chiedu, Professor, Department of Orthopaedic Surgery and Traumatology, Obafemi Awolowo University, Ile-Ife, Nigeria.

Reviewers:

(1) Mitsuhiko Takahashi, Tokushima Prefectural Central Hospital, Japan.

(2) Vinotha Sanmugarajah, University of Jaffna, Sri Lanka.

(3) Belenky Vadim, Russia.

Complete Peer review History: <http://www.sdiarticle4.com/review-history/53439>

Case Report

Received 20 October 2019

Accepted 23 December 2019

Published 31 December 2019

ABSTRACT

Bertolotti's syndrome is a disorder of the spine characterized by chronic lower back pain associated with lumbosacral transitional vertebra (LSTV) in which there is an abnormal enlargement of the transverse process of the fifth lumbar vertebra. It may be a source of chronic pain in 10% of lower back pain patients younger than 30 years. In Bertolotti's syndrome, the fifth lumbar vertebra transverse process may be enlarged either unilaterally or bilaterally and may articulate or fuse with the sacrum or ilium. It is an anatomical variant of sacralization of fifth lumbar vertebra. This causes alterations in the biomechanical characteristics of the lumbar spine resulting from asymmetrical motion between the sacrum and LSTV. It is often a factor that is not taken into consideration in the workup and management of lower back pain. The syndrome affects 4% to 8% of the population. It can cause pain due to involvement of various structures: lumbosacral neo-articulation, contralateral facet arthrosis, sciatica, discogenic, or sacroiliac pain. Physical examination usually shows normal findings. Bertolotti's syndrome is oftentimes underdiagnosed and should be suspected as a differential diagnosis for lower back pain. Therefore, this case report highlights two cases with Bertolotti's syndrome and explains its epidemiology, pathophysiology and management which is an important topic of general knowledge to all doctors.

*Corresponding author: Email: leesiang90@hotmail.com;

Keywords: Bertolotti syndrome; lumbar transitional vertebra; lower back pain; sacralization.

1. INTRODUCTION

Bertolotti's syndrome is a spinal disorder characterised by lumbosacral transitional vertebra (LSTV) in which the fifth lumbar vertebra transverse process may be enlarged either unilaterally or bilaterally and may articulate or fuse with the ilium or sacrum, thus producing a chronic, persistent lower back pain [1]. It represents an anatomical variant of fifth lumbar vertebra sacralization. In 1917, Mario Bertolotti stated that these abnormal vertebrae may produce low back pain due to arthritic changes that occur at the pseudarthrosis site [2]. The overall incidence of Bertolotti's syndrome has been reported to be between 4% to 8% in patients with low back pain and 10% in patients presenting with back and leg pain under the age of 30 years old. It is an important aetiology of low back pain in young adults. The majority of LSTV cases are asymptomatic and are discovered incidentally [3-11]. The biomechanics of LSTV is attributed to an alteration or reduction of movement between the transitional vertebra and the sacrum that can ultimately lead to pain that results from stress in the facet joint and/or is exacerbated by degeneration of disc [12]. Currently there is no consensus as to the best mode of treatment for patients with Bertolotti's syndrome. Low back pain in Bertolotti's syndrome has been addressed by various treatment options but there is no consensus regarding definitive management.

2. PRESENTATION OF CASE

Case 1: A 23 years old well and healthy Malay lady who works as a clerk presented to Hospital Melaka emergency department for treatment of lower back pain for 1 year which worsened in the past 1 week. It was a dull aching on and off localised pain which was aggravated by prolonged standing and relieved upon rest. There was no weakness or numbness of bilateral lower limbs. No history of antecedent fall or trauma and no bladder or bowel incontinence. There was no history of prolonged cough; loss of appetite; loss of weight or tuberculosis contact. On examination, there was no midline spinal tenderness. There was mild tenderness over right lower paraspinal muscles. Neurology of bilateral lower limbs was normal. Straight leg raising test over bilateral lower limbs was normal. Inflammatory markers were within normal limits. Lumbosacral x ray showed abnormal articulation between the medial aspect of the right ilium and the L5 transverse process consistent with Bertolotti's syndrome as shown in Fig. 1. She was admitted to orthopaedics ward and started on analgesics like celecoxib and methylcobalt and referred physiotherapist for back strengthening exercises. Subsequently, the patient was discharged on second day of admission and upon review in clinic after 1 month, 3 month and 6 months and currently patient is otherwise well and pain control is adequate and she is able to do daily activities and work without much difficulties.

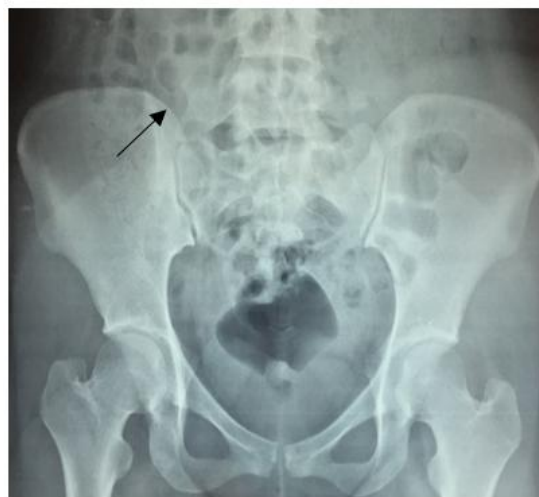

Fig. 1. (Case 1): Lumbosacral X ray shows abnormal articulation between the L5 transverse process and the medial aspect of the right ilium consistent with Bertolotti's syndrome with Castellvi's type Ia LSTV (labelled by arrow)

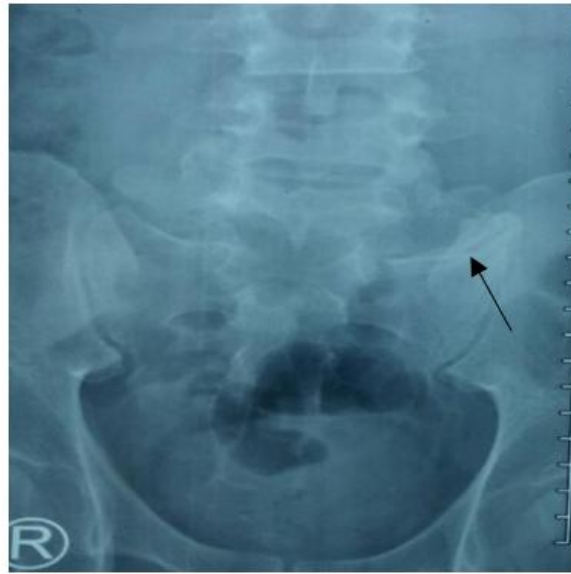

Fig. 2. (Case 2): Lumbosacral X ray shows abnormal articulation between the L5 transverse process and the medial aspect of the left ilium consistent with Bertolotti's syndrome with Castellvi's type IIa LSTV (labelled by arrow)

Case 2: A 43 years old otherwise well and healthy Malay gentleman who works as a gardener presented to Hospital Melaka outpatient orthopaedics clinic with lower back pain for 5 months which worsened in the past 2 weeks. It was a dull aching on and off localised pain which was aggravated by strenuous activities and relieved upon rest. There was no weakness or numbness of bilateral lower limbs. No history of antecedent fall or trauma and no bladder or bowel incontinence. There was no history of prolonged cough; loss of appetite; loss of weight or tuberculosis contact. On examination, there was no midline spinal tenderness. There was mild tenderness over left lower paraspinal muscles. Neurology of bilateral lower limbs was normal. Straight leg raising test over bilateral lower limbs was normal. Inflammatory markers were within normal limits. Lumbosacral x ray showed abnormal articulation between the medial aspect of the left ilium and the L5 transverse process consistent with Bertolotti's syndrome as shown in Fig. 2. Patient was started on analgesics like tramadol and paracetamol and referred physiotherapist for back strengthening exercises. He was reviewed in clinic after 3 month and 6 months and currently patient is otherwise well and pain control is adequate and he is able to do daily activities and work without much difficulties.

3. DISCUSSION

Low back pain in the presence of an LSTV was originally noted by Mario Bertolotti in 1917 and

termed "Bertolotti's Syndrome" [13,14]. Low back pain is a prevalent problem with multiple causes. Approximately 80% of adults seek a doctor's help to manage their low back pain at some point in their lives [15]. Therefore, it is crucial that patients with Bertolotti's syndrome be accurately diagnosed and treated. According to Castellvi's classification as shown on Fig. 3, there are four types of lumbosacral transitional vertebrae on the basis of morphologic characteristics. Type I includes unilateral (Ia) or bilateral (Ib) dysplastic transverse processes, measuring at least 19 mm in width (craniocaudal dimension) [16]. Type II exhibits incomplete unilateral (IIa) or bilateral (IIb) lumbarization/sacralization with an enlarged transverse process that has a diarthrodial joint between itself and the sacrum. Type III LSTV describes unilateral (IIIa) or bilateral (IIIb) lumbarization/sacralization with complete osseous fusion of the transverse process(es) to the sacrum. Type IV involves a unilateral type II transition with a type III on the contralateral side [13,17-20]. Literature indicates that Type II and IV have the most positive association with lower back pain [18].

Unilateral LSTV is more common than bilateral LSTV (9% vs. 3%) [21]. Men are more likely to be affected than women (28.1% vs. 11.1%) [22]. Patients with LSTV usually present to clinic with lower back pain after second decade of life [23]. According to Quinlan et al, Bertolotti's syndrome has been reported to have an overall incidence of between 4% to 8% in patients with low back pain and 10% in patients presenting with back

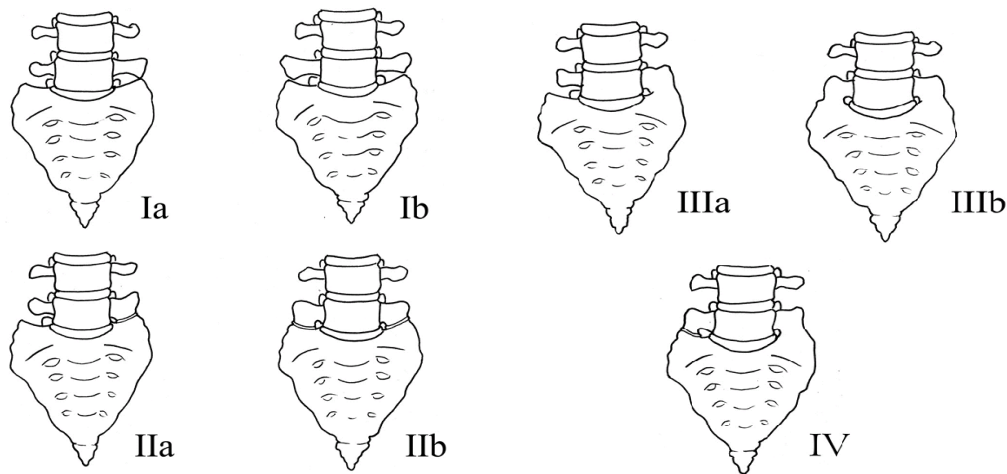


Fig. 3. Illustration demonstrating the Castellvi classification of LSTVs

and leg pain under 30 years of age [3]. Throughout the literature, the prevalence of LSTV in patients looking for treatment of low back pain ranges from 4.6%-35.6% [24]. Due to its wide prevalence, Quinlan et al. encourages doctors to include Bertolotti's syndrome in the differential diagnosis for low back pain, especially in younger patients [3].

Various aetiologies for pain in symptomatic cases of Bertolotti's syndrome have been postulated. Aihara et al. [25], Luoma et al. [26], and Brown et al. [27] have all published MRI-based studies demonstrating that the disc above a transitional vertebra appears to be at increased risk of undergoing degenerative changes, whereas the disc below appears to be protected. The transverse process may be completely fused to the sacrum or ilium, or a pseudo-articulation may exist. This pseudo-articulation may undergo degenerative changes and be the source of pain in these patients. Alternatively, the fused transitional vertebrae may result in instability above the level of the fusion. Elster et al. found that the incidence of degenerative disc disease and spinal stenosis was almost nine times higher in the level adjacent to the LSTV [7]. Cases are often associated with transitional vertebrae and there may be six lumbar vertebrae. These changes are associated with disc degeneration or instability, suggesting that there may be abnormal biomechanical stress above the fusion [7].

The diagnosis of Bertolotti's syndrome is based on lumbar spine radiographs showing a transverse mega-apophysis. Cross-sectional imaging (bone scan) can support diagnostic

suspicion by specifying the morphological anomaly and highlighting the neo-articulation impingement (functional imaging: MRI and bone scintigraphy) [28]. A diagnostic test which infiltrates the neo-articulation with anaesthetic and anti-inflammatories is used to assess the possible relationship between the painful symptomatology and the morphological anomaly (neo-articulation). If the test is positive, the pathology is almost certainly Bertolotti's syndrome: i.e., pain related to a neo-articulation. The test is both diagnostic and therapeutic because it also serves as the medical treatment for this syndrome [17].

Treatment of low back pain associated with Bertolotti's syndrome should be initiated with a comprehensive conservative approach consisting of activity and lifestyle modification, physical therapy and home exercise, psychosocial support, and medications such as NSAIDs, muscle relaxants and antidepressants. Conservative nonsurgical management includes local injection of anaesthetic and corticosteroids within the pseudo-articulation or contralateral facet joint [4,29,30], radiofrequency ablation and surgical management with partial transverse process resection, and/or posterior spinal fusion [31]. Direct local anaesthetic and steroid injection or surgical resection of the anomalous or contralateral facet joint has produced successful relief of pain and can yield valuable diagnostic information [5,6,32,33].

Interventional approaches can be beneficial in cases refractory to conventional conservative management. A transforaminal or interlaminar epidural steroid injection maybe considered for

those who presented with lumbosacral radiculopathy or radiculitis symptoms due to the direct compression or irritation of the nerve root by an enlarged transverse process or pseudo-articulation. In a study done by Zhang et al, a diagnostic lumbar facet medial branch block can be performed for those with clinical evidence of lumbar facet pain due to the reduced motion between the L5TV and the sacrum. Radiofrequency neurotomy of the target medial branches may provide longer-term pain relief if the patient has greater than 50% pain reduction from the diagnostic medial branch block. For those suspected of sacroiliac dysfunction due to increased load to the sacroiliac joint with restricted motion between the L5TV and the sacrum, A diagnostic sacroiliac joint injection can be attempted. If the patient has greater than 50% pain reduction, radiofrequency neurotomy of the L5 dorsal ramus, S1 and S2 lateral branches may provide longer-term pain relief [34]. In a case report, Burnham described a successful radiofrequency technique for treatment of symptomatic lumbosacral junction pseudo-articulation in which he fluoroscopically guided local anaesthetic/ corticosteroid injection into the pseudoarthrosis circumferentially around the posterior pseudoarthrosis articular margin. Accordingly, bipolar radiofrequency strip thermal lesions were created at the same locations. Complete pain relief and full restoration of function was achieved for 16 months post procedure [5]. Almeida et also reported that radio-frequency denervation is another possible treatment option and provided temporary relief of pain due to an anomalous articulation [21].

Operative treatment is suggested in selected patients. For example, resection of the transverse process may be beneficial for those who demonstrate pain truly emerging from a transitional joint and doesn't respond to conservative treatment. If the pain is originated from a degenerated disc above a transitional level, posterior fusion is an option [1]. In a case report, Brault et al described successful treatment of contralateral facetogenic pain by resection of the ipsilateral anomalous articulation [5]. Jonsson et al reported relief of pain in 9 of 11 patients following surgical resection of a unilateral L5TV pseudo-articulation [35]. Ugokwe et al and Almeida et al similarly described successful treatment after surgical resection [22,33]. In a case series of 8 patients who underwent surgical resection of the unilateral anomalous articulation and 8 patients who underwent posterolateral fusion of the L5TV,

Santavirta et al reported improvement in pain in 10 of 16 patients at 9-year follow-up without a difference between the fusion and resection groups [1]. In a case report, Yousif et al performed a minimally invasive tubular resection of a transitional lumbosacral pseudo joint and the short-term outcomes were favourable with the patient discharged, pain free 36 hours postoperatively, with return to normal work duties in two weeks and remained pain free six weeks postoperatively. The use of a minimally invasive tubular approach was key in minimizing unnecessary tissue dissection via a small 35 mm incision. It allowed mobilisation over an obstructive osseous ridge and meant that bony resection was limited only to the pathological joint, minimizing the risk of back pain in the future [36]. Li et al also performed minimally invasive tubular resection of the anomalous transverse process in 7 patients with Bertolotti's syndrome. Three (43%) of 7 patients reported complete resolution of low-back pain, 2 (29%) of 7 patients had reduced low-back pain, and 2 patients (29%) experienced initial relief but return of low back pain at 1 and 4 years postoperatively. Three (50%) of the 6 patients with radicular pain had complete relief of this symptom. They suggest that minimally invasive resection of the L5TV can be used in selected patients in whom conservative therapy has failed and who have pain attributed to the L5TV [4].

4. CONCLUSION

Bertolotti's syndrome is frequently underdiagnosed and should be considered a differential diagnosis for lower back pain in young patients after ruling out all other causes of back pain. It is often a factor that is not addressed in the evaluation and treatment of lower back pain. Management of patients with low back pain associated with Bertolotti's syndrome has to be individualized. Multimodal care is often required for optimal patient outcome. The treatment, whether conservative or operative, is still debated. Understanding the biomechanical and pathophysiological mechanisms underlying the chronic low back pain is the key to choosing the appropriate procedures.

CONSENT AND ETHICAL APPROVAL

As per international standard guideline participant consent and ethical approval has been collected and preserved by the authors.

COMPETING INTERESTS

Authors have declared that no competing interests exist.

REFERENCES

- Santavirta S, Tallroth K, Ylinen P, Suoranta H: Surgical treatment of Bertolotti's syndrome. Follow up of 16 patients. *Arch Orthop Trauma Surg.* 1993; 112:82-87.
- Bertolotti M. Contributo alla conoscenza dei vizi differenziazione regionale del rachide con speciale riguardo all assimilazione sacrale della V. lombare. *Radiol Med.* 1917;4:113-144.
- Quinlan JF, Duke D, Eustace S. Bertolotti's syndrome. A cause of back pain in young people. *J Bone Joint Surg.* 2006;88:1183-1186.
- Li Y, Lubelski D, Abdullah KG, Mroz TE, Steinmetz MP. Minimally invasive tubular resection of the anomalous transverse process in patients with Bertolotti's syndrome. *Journal of Neurosurgery: Spine SPI.* 2014;20(3):283-290.
- Brault JS, Smith J, Currier BL. Partial lumbosacral transitional vertebra resection for contralateral facetogenic pain. *Spine (Phila Pa 1976).* 2001;26:226-29.
- Burnham R. Radiofrequency sensory ablation as a treatment for symptomatic unilateral lumbosacral junction pseudarticulation (Bertolotti's syndrome): A case report. *Pain Med.* 2010; 11(6):853-855.
- Elster AD. Bertolotti's syndrome revisited: transitional vertebrae of the lumbar spine. *Spine.* 1989;14:1373-7.
- O'Driscoll CM, Irwin A, Saifuddin A. Variations in morphology of the lumbosacral junction on sagittal MRI: Correlation with plain radiography. *Skeletal Radiol.* 1996;25:225-230.
- Otani K, Konno S, Kikuchi S. Lumbosacral transitional vertebrae and nerve-root symptoms. *J Bone Joint Surg Br.* 2001;83: 1137-1140.
- Seçer M, Muradov JM, Dalgiç A. Evaluation of congenital lumbosacral malformations and neurological findings in patients with low back pain. *Turk Neurosurg.* 2009;19:145-148.
- Tilley P. Is sacralization a significant factor in lumbar pain? *J Am Osteopath Assoc.* 1970;70:238-241.
- Ju CI, Kim SW, Kim JG, Lee SM, Shin H, Lee HY, et al. Decompressive L5 transverse processectomy for Bertolotti's syndrome: A preliminary study. *Pain Physician.* 2017;20:E923-E932.
- Ravikanth R, Majumdar P. Bertolotti's syndrome in low-backache population: Classification and imaging findings. *Tzu Chi Med J.* 2019;31(2):90-5.
- Delpont EG, Cucuzzella TR, Kim N, Marley J, Pruitt C, Delpont AG, et al. Lumbosacral transitional vertebrae: Incidence in a consecutive patient series. *Pain Physician.* 2006;9:53-6.
- Anderson GBJ. The epidemiology of spinal disorders, in Frymoyer JW (ed): *The Adult Spine: Principles and Practice.* Philadelphia, Lippincott-Raven. 1997;4:93-141.
- Grøn S, Jensen RK, Jensen TS, Kongsted A. Back beliefs in patients with low back pain: A primary care cohort study. *BMC Musculoskeletal Disorders.* 2019;20(1):578.
- Castellvi AE, Goldstein LA, Chan DPK. Lumbosacral transitional vertebra and their relationship with lumbar extradural defects. *Spine.* 1983;9:493-495.
- Jancuska JM, Spivak JM, Bendo JA. A review of symptomatic lumbosacral transitional vertebrae: bertolotti's syndrome. *Int J Spine Surg.* 201;9:42.
- Neelakantan S, Anandarajan R, Shyam K, Philip B. Multimodality imaging in Bertolotti's syndrome: An important cause of low back pain in young adults. *BMJ Case Rep.* pii: Bcr2016217121; 2016.
- Kapetanakis S, Chaniotakis C, Paraskevopoulos C, Pavlidis P. An Unusual Case Report of Bertolotti's Syndrome: Extraforaminal Stenosis and L5 Unilateral Root Compression (Castellvi Type III an LSTV). *J Orthop Case Rep.* 2017;7(3):9-12.
- Mahato NK. Morphometric analysis and identification of characteristic features in sacra bearing accessory articulations with L5 vertebra. *Spine J.* 2010;10(7):616-621.
- Nardo L, Alizai H, Virayavanich W, Liu F, Hernandez A, Lynch JA, et al. Lumbosacral transitional vertebrae: association with low back pain. *Radiology.* 201;265(2):497-503.
- Almeida DB, Mattei TA, Soria MG, et al. Transitional lumbosacral vertebrae and low back pain: diagnostic pitfalls and management of Bertolotti's syndrome. *Arq Neuropsiquiatr.* 2009;67:268-72.

24. Apazidis A, Ricart PA, Diefenbach CM, Spivak JM. The prevalence of transitional vertebrae in the lumbar spine. *The Spine Journal: Official Journal of the North American Spine Society*. 2011; 11(9):858-862.
25. Aihara T, Takahashi K, Ogasawara A, Itadera E, Ono Y, Moriya H. Intervertebral disc degeneration associated with lumbosacral transitional vertebra: A clinical and anatomical study. *J Bone Joint Surg Br*. 2005;87:687–691.
26. Luoma K, Vehmas T, Raininko R, Luukkonen R, Riihimaki H: Lumbosacral transitional vertebra: Relation to disc degeneration and low back pain. *Spine*. 2004;29:200–205.
27. Brown MF, Rockall AG, Hallam P, Hall-Craggs MA, Edgar MA. Transitional lumbosacral vertebra: Incidence of disc degeneration above and below. *J Bone Joint Surg Br*. 2000;82-B (Suppl II):180.
28. Cuenca C, et al. Bertolotti's syndrome in children: From low-back pain to surgery. A Case Report. *Neurochirurgie*; 2009.
29. Marks RC, Thulbourne T. Infiltration of anomalous lumbosacral articulations. Steroid and anesthetic injections in 10 back-pain patients," *Acta Orthop Scandi*. 1991;62(2):139–141.
30. Mitra R, Carlisle M. Bertolotti's syndrome: A case report. *Pain Practice*. 2009;9(2): 152–154.
31. Konin GP, Walz DM. Lumbosacral transitional vertebrae: Classification, imaging findings and clinical relevance. *Am J Neuroradiol*. 2010;31(10):1778-1786.
32. Marks RC, Thulbourne T. Infiltration of anomalous lumbosacral articulations: steroid and anesthetic injections in 10 back pain patients. *Acta Orthop Scand*. 1991; 62:139–41.
33. Ugokwe KT, Chen TL, Klineberg E. Minimally invasive surgical treatment of Bertolotti's syndrome: case report. *Neurosurgery*. 2008;62:454–55.
34. Zhang R, Cheng J. Interventional management of chronic low back pain associated with Bertolotti's syndrome: Report of case series. *Ann Clin Case Rep*. 2017;2:1348.
35. Jonsson B, Stromqvist B, Egund N. Anomalous lumbosacral articulations and low back pain: evaluation and treatment. *Spine (Phila Pa 1976)*. 1989;14:831–34.
36. Yousif S, Wood M. Minimally invasive resection of lumbosacral pseudojoint resulting in complete resolution of a lower back pain – A case report and review of Bertolotti syndrome. *J Clin Neurosci*; 2018.

© 2019 Siang et al.; This is an Open Access article distributed under the terms of the Creative Commons Attribution License (<http://creativecommons.org/licenses/by/4.0>), which permits unrestricted use, distribution, and reproduction in any medium, provided the original work is properly cited.

Peer-review history:

The peer review history for this paper can be accessed here:
<http://www.sdiarticle4.com/review-history/53439>