

A Case Report of Hepatic Venous Outflow Tract Obstruction in Patient with Ulcerative Colitis

**Nitesh Bassi^a, Aakash Shah^a, Ishan Mittal^a,
Shishirendu Parihar^a, Anurag Tiwari^a, Vinod Kumar^a,
S. K. Shukla^a, V. K. Dixit^a and Devesh Prakash Yadav^{a*}**

^a *Department of Gastroenterology, Institute of Medical Sciences, Banaras Hindu University, Varanasi, Uttar Pradesh, India.*

Authors' contributions

This work was carried out in collaboration among all authors. Authors NB and AS conceptualized the manuscript, collected data, wrote the first draft of the manuscript. Authors IM and SP helped in editing the manuscript draft and managed the literature search. Authors AT, VK, SKS, VKD and DPY contributed to supervision of manuscript. All authors read and approved the final manuscript.

Article Information

Open Peer Review History:

This journal follows the Advanced Open Peer Review policy. Identity of the Reviewers, Editor(s) and additional Reviewers, peer review comments, different versions of the manuscript, comments of the editors, etc are available here: <https://www.sdiarticle5.com/review-history/102791>

Case Report

Received: 06/05/2023
Accepted: 15/07/2023
Published: 25/07/2023

ABSTRACT

We report a case of 23 year old female diagnosed as Hepatic Venous Outflow tract obstruction (HVOTO) with ulcerative colitis (UC) with Cytomegalovirus (CMV) Colitis. HVOTO with UC is a very rare entity, to the best of our knowledge there have been only few published case reports of HVOTO with UC. Our patient presented with fever, bloody stools with tenesmus, colicky abdominal pain from last 6 months, and pedal edema with abdominal distention from last 2 months. Sigmoidoscopy and biopsy was done on presentation which was suggestive of active ulcerative colitis with CMV colitis. Color Doppler of spleno-portal axis was done suggestive of HVOTO. Patient was started on Ganciclovir, Mesalamine, anticoagulants and was subjected to balloon angioplasty after which anticoagulants were continued. Patient is being followed up for 6 months now and is doing well.

*Corresponding author: Email: devesh.thedoc@gmail.com;

Keywords: Ulcerative colitis; hepatic venous outflow tract obstruction; CMV colitis; ganciclovir.

1. INTRODUCTION

Patients with inflammatory bowel disease (IBD) are prone to many extra-intestinal manifestations, amongst which risk for thromboembolic complications [1] is one, but hepatic vein thrombosis has been reported as a rare extra intestinal complication of UC [2]. The tendency for hyper coagulation has been attributed to many factors like cytokine activation, platelet activity, disease activity, endothelial dysfunction, superadded infection and more, but none of them is proven. Being a rare scenario, no clear consensus about presentation, complications, management of the condition is present. Hence, we report a case of a patient with UC and CMV colitis, complicated by the development HVOTO.

2. CASE REPORT

Our patient was a 23 years old female presented with complaints of 4-5 episode per day of semisolid stools mixed with blood associated with tenesmus, colicky abdominal pain and fever for 6 months. She had complaints of abdominal distention with bilateral lower limb swelling since 2 months which was not associated with jaundice, hematemesis or melena. The patient was not taking any medications. On clinical examination, BP was 110/68 mm Hg, Pulse rate was 88/min, tender hepatomegaly, splenomegaly and shifting dullness were present along with dilated veins over anterior abdominal wall and flanks (Fig. 1). Other systemic findings were unremarkable. Haematological and Biochemical investigations of the patient are mentioned in Table 1. On Sigmoidoscopy there was patchy loss of vascularity with increased friability and granularity, overlying superficial and deep ulcers with spots of coagulated blood were present; Baron score 2, Ulcerative Colitis Endoscopic Index of Severity– 5/8 suggestive of IBD-UC (Fig. 2). On biopsy, there were changes consistent with ulcerative colitis with cryptitis and crypt abscess formation without dysplasia or granuloma. Few cells were showing nucleomegaly with nuclear inclusions (Fig. 3). CMV DNA was detected, hence the biopsy picture was suggestive of Acute Ulcerative colitis with features of CMV colitis. The ascitic fluid analysis was done suggestive of high Serum Albumin Ascitic fluid Gradient (SAAG) and low protein indicating portal hypertension as the etiology. She was subjected to Color Doppler of hepatportal system which showed ostial narrowing of all the hepatic veins suggesting

Hepatic venous outflow tract obstruction, portal hypertension with liver parenchymal disease and multiple nodules? Dysplastic? regenerative. She was subjected to Triphasic computed tomography of abdomen which showed short segment narrowing of Middle hepatic vein and Right hepatic vein with left hepatic vein ostial narrowing suggestive of HVOTO with features of Liver parenchymal disease with portal hypertension and multiple nodules? dysplastic? regenerative (Fig. 4). Alpha fetoprotein was normal. CT guided targeted biopsy of Hepatic nodules was done with biopsy report suggestive of high grade dysplastic nodules. Upper GI Endoscopy showed features of early portal hypertension. For ruling out other causes of hypercoagulability like Protein C and S deficiency, AT III deficiency, Factor V leiden mutation, Prothrombin Gene mutation G20210A, Antinuclear antibodies, Antiphospholipid antibodies investigations were sent which turned out to be negative. As mentioned earlier, our patient was not on any oral contraceptive medication. After admission she was started on Mesalamine and Ganciclovir, her stools frequency reduced to 1-2 episodes per day without blood. Patient was also started on diuretics and anticoagulation. Patient was subjected to ostial dilatation of Right Hepatic Vein and Middle Hepatic Vein via balloon angioplasty and anticoagulation was continued after procedure.

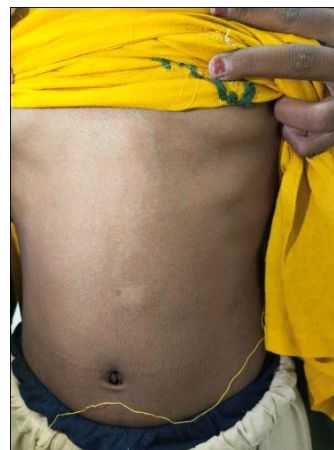

Fig. 1. Dilated veins present on anterior abdominal wall

3. DISCUSSION

Hepatic Vein thrombosis is a rare extra intestinal manifestation associated with IBD. Worldwide only few cases have been reported. Patients with

UC are associated with increased risk for venous thromboembolism (VTE) at baseline but the risk is eight times higher during a flare up [3]. UC is also associated with an increased risk of arterial thromboembolic events [4]. The risk of VTE development among IBD patients is positively associated with both disease extent and activity. VTE in IBD patients occurs earlier in life than in those without IBD [5,6]. These and other findings support the classification of IBD as an independent risk factor for the development of VTE. The Acquisition of non heritable risk factors for thromboembolic disease among IBD patients particularly during acute flare ups is likely contributory. One study also suggested IBD patients remain at higher risk of venous thromboembolism even after proctocolectomy [7]. IBD patients have abnormalities in coagulation [8,9,10], Platelet function [11-13], fibrinolysis [14], endothelial dysfunction [15] and active inflammatory cascade [16]. Cytokines such as IL-1, IL -6, and Anti TNF alpha remain at a higher function during the course of disease [17]. These cytokines function as proinflammatory substances and increase the risk of hypercoaguability. Underlying hypercoaguable disorders can meld with IBD hypercoaguable state. Many studies have shown that thrombosis in IBD is not always related to an underlying genetic or acquired thrombophilia [18]. However the hypercoaguability profile in our patient was negative. HVOTO can present in acute, subacute and chronic form. The diagnosis of HVOTO can be made in patients presenting with abdominal pain, ascites, dilated veins and tender hepatomegaly or with other findings raising a high level of suspicion in the clinician. The diagnostic modalities that have been found to be most helpful are Doppler ultrasound [19] and Computed Tomography [20]. Magnetic Resonance Angiography has been shown in a few studies to be more accurate in delineating the hepatic vasculature to more precisely define the location of the obstruction [21]. The gold standard for diagnosis is hepatic venography but it is more invasive and is typically performed when less invasive methods of evaluation are equivocal or negative. Therapeutic options for HVOTO with IBD are varied and depend on clinical presentation. Anticoagulation should be initiated immediately and continued for life unless contraindicated. Our patient underwent ostial dilatation of Right Hepatic Vein and Middle Hepatic Vein via Balloon angioplasty and was kept on anticoagulants. Patient is being followed up and is doing well. No untoward side effects of anticoagulants were noticed till now.

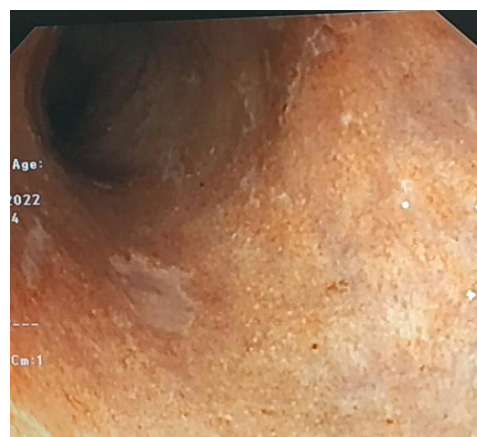


Fig. 2. Sigmoidoscopy finding of patchy loss of vascularity with increased friability and granularity, overlying superficial and deep ulcers with spots of coagulated blood; baron score 2, ulcerative colitis endoscopic index of severity– 5/8 suggestive of IBD-UC

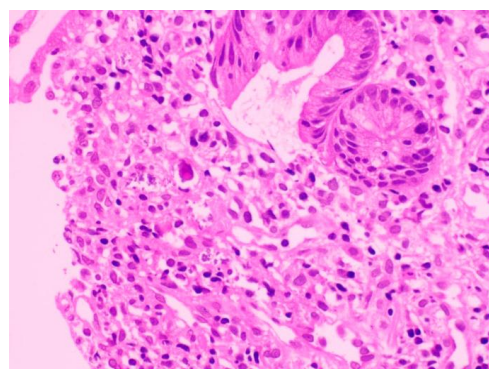


Fig. 3. Histopathological picture of UC with few cells showing nucleomegaly and nuclear inclusions suggestive of CMV colitis

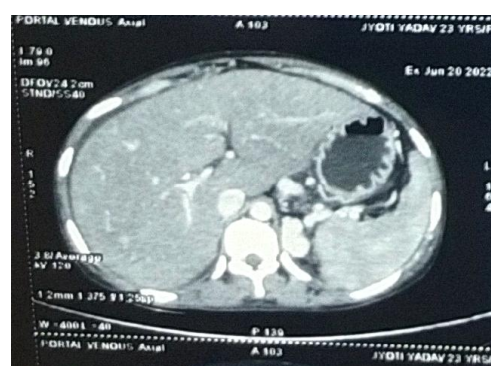

Fig. 4. TPCT image suggestive of short segment narrowing of middle hepatic vein and right hepatic vein with left hepatic vein ostial narrowing suggestive of HVOTO with features of liver parenchymal disease with portal hypertension and multiple nodules? dysplastic? regenerative

Table 1. Hematological and biochemical investigations of the patient

Haemoglobin	10.6 g/dL (14-16 g/dL)
Total Leukocyte Counts	5870/ cu.mm(4000-11000 / cu.mm)
Platelet Counts	0.55 L/cu.mm (1.5-4.5 L/cu.mm)
C-Reactive Protein	35.4 mg/L(<3mg/L)
Kidney function tests	Urea – 10mg/dL (20-40 mg/dL) Creatinine – 0.9mg/dL (0.6-1.2 mg/dL) Sodium – 132 mEq/L(135-145 mEq/L) Potassium –3.4 mEq/L(3.5-5.5mEq/L)
liver function tests	SGPT – 13 IU/L (5-37 IU/L) SGOT – 49 IU/L (7-40 IU/L) ALP – 359 IU/L (40-150 IU/L) Total Bilirubin – 1.9 mg/dL (0.2-1.3 mg/dL) Direct Bilirubin –1.0 mg/dL (0-0.3 mg/dL)
Albumin	2.1g/dL
Globulin	2.9 g/dL
Prothrombin Time	16.8s (11-15)
International Normalised Ratio	1.12
HIV/HBsAG/ANTI-HCV	NR/NR/NR
Ascitic Fluid Analysis	Total Protein – 1.48g/dL Albumin – 0.79 g/dL Total Leukocyte Counts – 80 cells/cu.mm Differential Leukocyte Counts – N -14/L -79 Serum Ascitic Albumin Gradient – 1.31

4. CONCLUSION

IBD-UC patients can have varied range of intestinal and extra-intestinal manifestations. Patients with IBD are at increased risk of venous and arterial thrombosis. Hepatic vein or inferior vena cava thrombosis is a rare extra-intestinal complication of ulcerative colitis. There should be a high level of suspicion for HVOTO in patients with IBD presenting with ascites, dilated veins and tender hepatomegaly.

CONSENT

All authors declare that written informed consent was obtained from the patient for publication of this case report and accompanying images.

ETHICAL APPROVAL

As per international standard or university standard written ethical approval has been collected and preserved by the author(s).

COMPETING INTERESTS

Authors have declared that no competing interests exist.

REFERENCES

1. Papa A, Gerardi V, Marzo M, Felice C, Rapaccini GL, Gasbarrini A. Venous

- thromboembolism in patients with inflammatory bowel disease: focus on prevention and treatment. *World J Gastroenterol.* 2014;20(12):3173-3179. DOI: 10.3748/wjg.v20.i12.3173
2. Sloan WP, Barga JA, Gage RB. Life histories of patients with chronic ulcerative colitis: a review of 2,000 cases. *Gastroenterology* 1968;54:819-822.
3. Spina L, Saibeni S, Battaglioli T, Peyvandi F, de Franchis R, Vecchi M. Thrombosis in inflammatory bowel diseases: Role of inherited thrombophilia. *Am J Gastroenterol.* 2005;100:2036-2041.
4. Ha C, Magowan S, Accortt NA, Chen J, Stone CD. Risk of arterial thrombotic events in inflammatory bowel disease. *Am J Gastroenterol.* 2009;104:1445-1451.
5. Jackson LM, O’Gorman PJ, O’Connell J, Cronin CC, Cotter KP, Shanahan F. Thrombosis in inflammatory bowel disease: Clinical setting, procoagulant profile and factor V Leiden. *QJM.* 1997;90: 183-188.
6. Grip O, Svensson PJ, Lindgren S. Inflammatory bowel disease promotes venous thrombosis earlier in life. *Scand J Gastroenterol.* 2000;35:619-623.
7. Wallaert JB, De Martino RR, Marsicovetere PS, et al. Venous thromboembolism after surgery for inflammatory bowel disease:

- are there modifiable risk factors? Data from ACS NSQIP. *Dis Colon Rectum*. 2012;55(11):1138-1144.
DOI: 10.1097/DCR.0b013e3182698f60
8. Heneghan MA, Cleary B, Murray M, O'Gorman TA, McCarthy CF. Activated protein C resistance, thrombophilia, and inflammatory bowel disease. *Dig Dis Sci*. 1998;43:1356-1361.
 9. Saibeni S, Vecchi M, Valsecchi C, Faioni EM, Razzari C, de Franchis R. Reduced free protein S levels in patients with inflammatory bowel disease: Prevalence, clinical relevance, and role of anti-protein S antibodies. *Dig Dis Sci*. 2001;46:637-643.
 10. Hudson M, Chitolie A, Hutton RA, Smith MS, Pounder RE, Wakefield AJ. Thrombotic vascular risk factors in inflammatory bowel disease. *Gut*. 1996;38:733-737.
 11. Danese S, Motte Cd Cde L, Fiocchi C. Platelets in inflammatory bowel disease: Clinical, pathogenic, and therapeutic implications. *Am J Gastroenterol*. 2004;99:938-945.
 12. Collins CE, Cahill MR, Rampton DS. Clinical significance of platelet size in inflammatory bowel disease? *Thromb Haemost*. 1997;77:218-219.
 13. Bohra GK, Chhabra V, Midha N, Sureka B. Budd-Chiari syndrome in a patient with ulcerative colitis. *BMJ Case Rep*. 2018;2018:bcr2017222300.
DOI: 10.1136/bcr-2017-222300
 14. Vrij AA, Rijken J, van Wersch JW, Stockbrügger RW. Coagulation and fibrinolysis in inflammatory bowel disease and in giant cell arteritis. *Pathophysiol Haemost Thromb*. 2003;33:75-83
 15. Meucci G, Pareti F, Vecchi M, Saibeni S, Bressi C, de Franchis R. Serum von Willebrand factor levels in patients with inflammatory bowel disease are related to systemic inflammation. *Scand J Gastroenterol*. 1999;34:287-290.
 16. Danese S, Vetrano S, Zhang L, Poplis VA, Castellino FJ. The protein C pathway in tissue inflammation and injury: pathogenic role and therapeutic implications. *Blood*. 2010;115:1121-1130.
 17. Danese S, Papa A, Saibeni S, Repici A, Malesci A, Vecchi M. Inflammation and coagulation in inflammatory bowel disease: The clot thickens. *Am J Gastroenterol*. 2007;102:174-186.
 18. Bouchrit Sara, Benjouad K, Lemfadli Yassine, Aiterrami A, Oubaha S, Samlani Z, Krati K. *Scholars Journal of Medical Case Reports Ulcerative Colitis Complicated By Budd-Chiari Syndrome: A Case Report*; 2021.
DOI: 10.36347/sjmcr.2021.v09i05.009
 19. Bolondi L, Gaiani S, Li Bassi S, Zironi G, Bonino F, Brunetto M, Barbara L. Diagnosis of budd-chiari syndrome by pulsed doppler ultrasound. *Gastroenterology*. 1991;100:1324-1331.
 20. Lupescu IG, Dobromir C, Popa GA, Gheorghe L, Georgescu SA. Spiral computed tomography and magnetic resonance angiography evaluation in Budd-Chiari syndrome. *J Gastrointest Liver Dis*. 2008;17:223-226.
 21. Noone TC, Semelka RC, Siegelman ES, Balci NC, Hussain SM, Kim PN, Mitchell DG. Budd-Chiari syndrome: Spectrum of appearances of acute, subacute, and chronic disease with magnetic resonance imaging. *J Magn Reson Imaging*. 2000;11:44-50.

© 2023 Bassi et al.; This is an Open Access article distributed under the terms of the Creative Commons Attribution License (<http://creativecommons.org/licenses/by/4.0>), which permits unrestricted use, distribution, and reproduction in any medium, provided the original work is properly cited.

Peer-review history:
The peer review history for this paper can be accessed here:
<https://www.sdiarticle5.com/review-history/102791>