

# Frontal Sinus Fractures: Management at the Yalgado Ouedraogo University Hospital Centre (Burkina Faso)

Arsène Coulibaly<sup>1\*</sup>, Patrik Gane-Bang<sup>2</sup>, Joseph Wend-Toin Biogo<sup>3</sup>, Ibraïma Traoré<sup>4</sup>, Tarcissus Konsem<sup>5</sup>

<sup>1</sup>Department of Maxillofacial Surgery, Regional University Hospital Centre of Ouahigouya, Ouahigouya, Burkina Faso

<sup>2</sup>Department of Stomatology and Maxillofacial Surgery, Regional Hospital Centre of Banfora, Banfora, Burkina Faso

<sup>3</sup>Department of Neurosurgery, Regional University Hospital Centre of Ouahigouya, Ouahigouya, Burkina Faso

<sup>4</sup>Department of Stomatology and Maxillofacial Surgery, Souro SANOU University Hospital Centre, Bobo Dioulasso, Burkina Faso

<sup>5</sup>Department of Stomatology and Maxillofacial Surgery, Yalgado OUEDRAOGO University Hospital Centre, Ouagadougou, Burkina Faso

Email: \*arsenecool@yahoo.fr, pganebang@gmail.com, joseph\_biogo@yahoo.fr, titison2005@yahoo.fr, tarcissus@hotmail.com

**How to cite this paper:** Coulibaly, A., Gane-Bang, P., Biogo, J.W.-T., Traoré, I. and Konsem, T. (2024) Frontal Sinus Fractures: Management at the Yalgado Ouedraogo University Hospital Centre (Burkina Faso). *Open Journal of Stomatology*, 14, 42-54.

<https://doi.org/10.4236/ojst.2024.141004>

**Received:** November 17, 2023

**Accepted:** January 20, 2024

**Published:** January 23, 2024

Copyright © 2024 by author(s) and Scientific Research Publishing Inc. This work is licensed under the Creative Commons Attribution International License (CC BY 4.0).

<http://creativecommons.org/licenses/by/4.0/>



Open Access

## Abstract

**Introduction:** Frontal sinus fractures are potentially serious. They are defined as a solution of continuity, open or closed, of one or both bone tables of the frontal sinus. This study aims to report on the management of them at the Yalgado OUEDRAOGO University Hospital Centre. **Methodology:** It is a descriptive cross-sectional study with retrospective collection from January 01, 2016 to December 31, 2018. Patients with frontal sinus fractures were managed at the Yalgado OUEDRAOGO University Hospital Centre through CT-scan proof. **Results:** Over three years, a total of 102 cases of frontal sinus fractures were collected with 29.9 years as average age. There were 96 men. Workers in the informal sector and pupils/students represented 58.90% of patients. The residence of the patients was urban in 68.80% of cases and rural in 31.40%. Road traffic accidents (RTAs) happened in 90.20%, and involved 2-wheelers in 98.20%. None of these drivers was wearing a helmet. The type III frontal fracture of Ioannides *et al.* represented 51.9% of cases. In 89.21% of cases, other facial and/or cranioencephalic injuries were compounded to frontal sinus fractures. No surgical management was observed in 82 (80.39%) patients and surgical management in 20 (19.61%) patients. The outcome was favourable, but sequelae and/or complications were noted in 10 patients who had surgery and 30 patients who did not. **Conclusion:** These results enforce helmet wearing for all riders of two-wheeled machines. In addition, vaccinations to prevent meningitis in frontal sinus fractures with dural breach should be systematic.

---

## Keywords

Management, Frontal Sinus Fracture, Burkina Faso

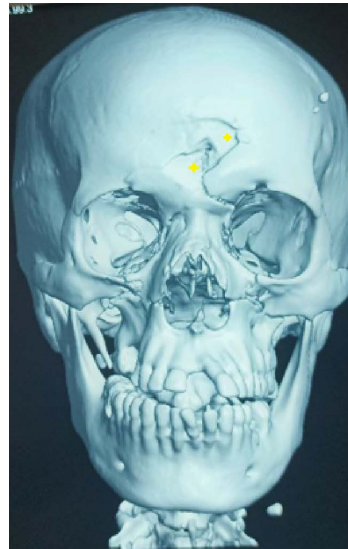
---

### 1. Introduction

Fractures of the frontal sinus are one of the fractures situated between the cranial region and the facial region. They account for 5% to 15% of facial fractures [1]. They result from high kinetic energy trauma due to the thickness of the anterior wall, which is solid and resistant [2]. These are potentially serious fractures, with the main risk being meningoencephalic damage. The main circumstances of injury are road traffic accidents (RTAs), interpersonal violence, falls and sports accidents [3] [4] [5]. Diagnosis is based on clinical signs, confirmed by craniofacial CT scans. The classification of frontal sinus fractures and their management are not standardized, because of the diversity of algorithms proposed by authors [6]-[13]. In fact, the management of these fractures depends on answering two fundamental questions: which fractures, if not treated, will lead to an immediate or late complication? And what is the appropriate surgical procedure if treatment of the fracture is considered necessary [14]? Whatever the answers to these two questions, the main concern remains complications, which may be short-term (meningitis, brain abscess) or long-term (mucocele, osteitis) and could be fatal for the patient [15]. In Burkina Faso, although the technical facilities are inadequate, frontal sinus fractures are managed in the maxillofacial surgery and neurosurgery departments. However, in the absence of a specific study on this subject in our context, there is great variability in the management of these fractures between surgical teams. A review of the management of frontal sinus fractures in our context is imperative in order to harmonize practices and achieve optimal patient care. The aim of this study is to report on the management of frontal sinus fractures at the Yalgado Ouédraogo University Hospital (CHUYO).

### 2. Patients and Methods

This was a descriptive cross-sectional study collected retrospectively from 01 January 2016 to 31 December 2018. It included all patients admitted to the Stomatology/Maxillofacial Surgery and Neurosurgery departments of the CHUYO for frontal sinus fracture confirmed by a craniofacial CT scan. A frontal sinus fracture was defined as continuous, open or closed solutions for one or both walls of the frontal sinus (Figure 1). The urban setting was defined as all the provincial capitals of Burkina Faso, and the rural setting as the departmental capitals, villages and farming hamlets. The consultation delay was defined as the time between the injury and the first admission to the CHUYO. The surgical intervention delay is defined by the time between the injury and the first surgical intervention at the CHUYO. The patient's general condition was evaluated using



**Figure 1.** 3D CT image of a left frontal sinus fracture radiating to the roof of the orbit in a 35-year-old patient at CHUYO.

the World Health Organisation (WHO) classification scale, which ranges from 0 to IV. Stage 0: corresponds to normal activity with no restrictions. Stage I: corresponds to a restriction of important physical activities, but the patient is ambulant and able to do light work. Stage II: corresponds to a patient who is ambulant and able to look after himself, but unable to do any work and bedridden for less than 50% of his time. Stage III: corresponds to a patient who is capable of much more limited self-care and spends more than 50% of their time in bed or in a chair. Stage IV: corresponds to a patient who is completely bedridden and unable to take care of themselves. The patient remains totally confined to bed or in a chair.

The types of injury have been classified according to the Ioannides *et al.* [10] classification of frontal sinus fractures. It comprises four types, the first three of which are subdivided into subtypes defined by the letters a, b, c, d or e. The Ioannides *et al.* [10] classification is as follows:

- Type I: Fractures of the anterior Wall
  - Ia: Without dislocation, no damage to the nasofrontal duct.
  - Ib: High fracture of dislocation, not of the nasofrontal duct.
  - Ic: Fracture with bone loss, not of the nasofrontal duct.
  - Id: Low fracture with involvement of the nasofrontal duct.
  - Ie: Fracture of all anterior wall with involvement of the nasofrontal duct.
- Type II: Posterior Wall fractures
  - IIa: No dislocation, no cerebrospinal fluid (CSF) leakage.
  - IIb: Dislocation and/or bone loss, no CSF leak.
  - IIc: Dislocation and CSF leak.
  - IId: Extensive and comminuted for the posterior wall with the CSF leak.
- Type III: Fractures of both the anterior and the posterior walls
  - IIIa: Type I + IIa or IIb.

- IIIb: Type I + IIc or IID.
  - Type IV: Comminuted fractures of all complex nasofronto-ethmoido-orbital
- The variables studied were the following: epidemiological (age, sex, socio-professional categories, residence, circumstances of occurrence of the injury), clinical (consultation delay, physical signs, type of frontal fracture and associated facial and extra-facial injuries), therapeutic (medical treatment, non-surgical treatment, surgical delay, approaches, surgical procedures), evolutionary (favourable, complications and sequelae).

The data were collected by filling in a data collection form containing the study variables from the patient's medical records, hospitalized patients' registers, emergency registers and operative report registers. The data were processed and analysed using Epi info 7.2 software.

The confidentiality of the information collected and the anonymity of the patients were respected.

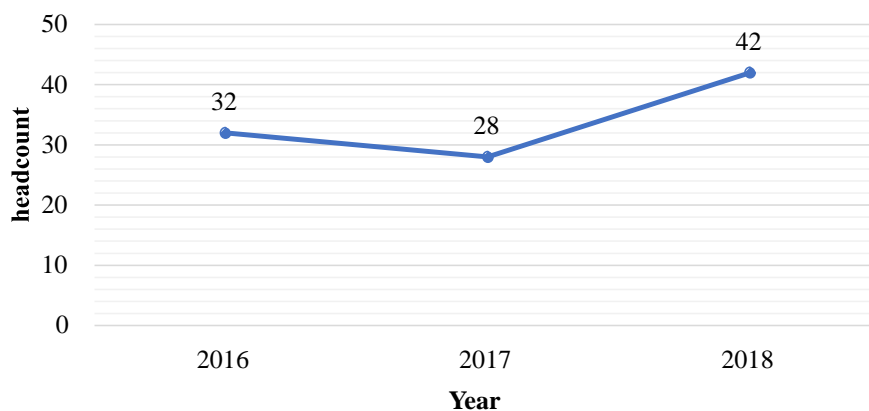
### 3. Results

#### 3.1. Epidemiological Data

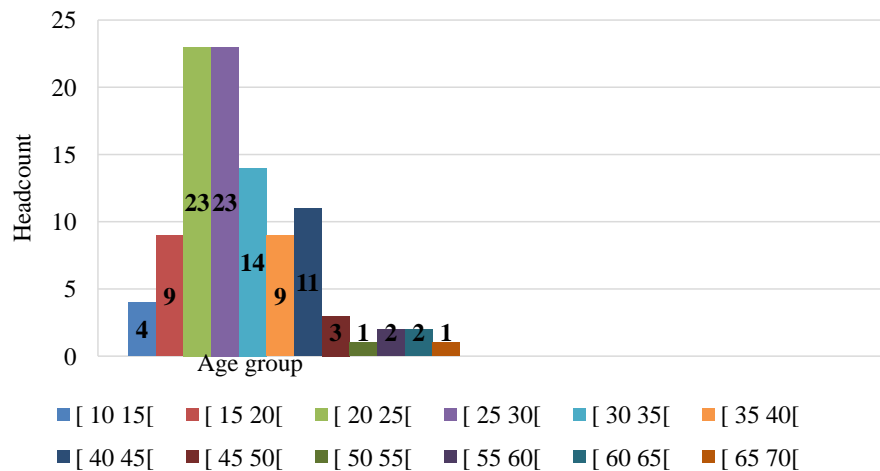
A total of 102 cases of frontal sinus fractures were collected over a three-year study period, *i.e.* an average of 34 cases per year (**Figure 2**). The mean age was 29.9 years, with extremes of 12 and 66 years. The [20 - 30[ age group accounted for 46 (45.10%) patients (**Figure 3**). There were 96 men (94.10%) and six women (5.90%), giving a sex ratio of 16. Workers in the informal sector and pupils/students accounted for 58.90% of patients. The residence of the patients was urban in 68.80% of cases and rural in 31.40%. Road traffic accidents (RTAs) occurred in 90.20% of cases (**Table 1**). These RTAs involved 2-wheeled vehicles in 98.20% of cases. None of the drivers of these two-wheeled vehicles was wearing a helmet.

#### 3.2. Clinical Data

Patients consulted a doctor after the onset of the trauma within an average of 1.3 days, with extremes of less than 0 and 21 days. Patients with initial unconscious



**Figure 2.** Distribution of patients by year of study (N = 102).



**Figure 3.** Distribution of patients by age group (N = 102).

**Table 1.** Distribution of patients according to the circumstances in which the maxillofacial trauma occurred (N = 102).

Circumstances of trauma	Headcount (n = 102)	Percentage (%)
RTA	92	90.20
Assault	4	3.92
Fall from a tree	3	2.94
Work accident	1	0.98
Sports accident	1	0.98
Guns	1	0.98

accounted for 37.25% of cases. Patients' general condition was classified as WHO stage I, II and III in 24.51%, 39.22% and 36.27% of cases respectively. Frontal deformity, isolated or associated with other injuries (soft tissue wounds, frontal hypoesthesia, ecchymosis) was found in 58.8% of cases. Physical signs were associated in several patients (Table 2). Type III frontal fracture according to Ioannides *et al.* [10] accounted for 51.9% of cases (Table 3). Other maxillofacial and extrafacial injuries were associated with frontal sinus fractures in 91 patients (89.21%). Associated maxillofacial fractures were found in 46 patients (Table 4) and cranioencephalic injuries (Figure 4) in 45 patients (Table 5). These injuries coexisted in the same patient.

### 3.3. Therapeutic and Evolutionary Data

Drug treatment was instituted in all patients. It consisted of rehydration solution, analgesics, anti-inflammatory drugs and antibiotics on admission and after surgery. Three patients were vaccinated against pneumococcal disease. Tetanus serum and vaccine were given to 26 (25.49%) patients with soft tissue wounds.

No surgery was performed for frontal sinus fractures in 82 (80.39%) patients. Repair of frontal sinus fractures was performed in 20 (19.61%) patients under general anaesthesia. Associated facial injuries (soft tissue and bone) were managed

**Table 2.** Distribution of patients according to physical signs (N = 102).

Physical signs	Headcount (n = 102)	Frequency (%)
Frontal deformity	100	98.39
Soft tissue wounds	26	25.49
Cerebrospinal rhinorrhoea	20	19.6 1
Rhinorrhage	17	16.67
Subcutaneous emphysema	5	4.90
Hypoesthesia	2	1.96
Periorbital ecchymosis	2	1.9 6

**Table 3.** Distribution of patient by type of frontal fracture according to Ioannides *et al.* [10] (N = 102).

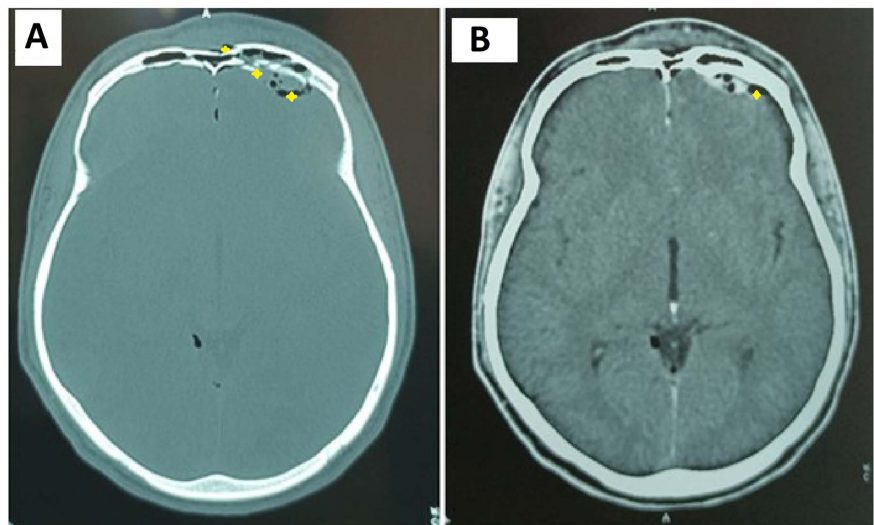
Type of frontal fracture	Headcount (n = 102)	Frequency (%)
<b>Type I: Fractures of the anterior Wall</b>	<b>35</b>	<b>34.31</b>
Ia: Without dislocation, no damage of the nasofrontal duct	14	12.72
Ib: High fracture of dislocation, not of the nasofrontal duct	9	8.82
Ic: Fracture with bone loss, not of the nasofrontal duct	1	0.98
Id: Low fracture with involvement of the nasofrontal duct	8	7.84
Ie: Fracture of all anterior wall with involvement of the nasofrontal duct	3	2.94
<b>Type II: Posterior Wall fractures</b>	<b>6</b>	<b>5.88</b>
IIa: No dislocation, no cerebrospinal fluid (CSF) leakage	1	0.98
IIb: Dislocation and/or bone loss, no CSF leak	1	0.98
IIc: Dislocation and CSF leak	4	3.92
<b>Type III: Fractures of both the anterior and the posterior walls</b>	<b>53</b>	<b>51.96</b>
IIIa: Type I + Type IIa or IIb	30	29.41
IIIb: Type I + Type IIc or IId	23	22.54
<b>Type IV: Comminuted fractures of all complex nasofronto-ethmoido-orbital</b>	<b>8</b>	<b>8.82</b>

**Table 4.** Distribution of patients according to associated maxillofacial fractures (N = 102).

Associated maxillofacial fractures	Headcount (n = 46)	Frequency (%)
Fracture of the upper orbital margin	13	12.75
Fracture of the maxillary sinus	12	11.76
Orbito-zygomatic fracture	12	11.76
Orbito-maxillary fracture	10	9.80
Fracture of the nasal bones	6	5.88
Nasoethmoidomaxillary fracture	6	5.88
Zygomatic fracture	5	4.90
Mandibular fracture	5	4.90
Naso-orbital fracture	2	1.96
Lefort II craniofacial disjunction	1	0.98

**Table 5.** Distribution of patients according to associated cranioencephalic injuries (N = 102).

Cranioencephalic injuries	Headcount (n = 45)	Frequency (%)
Oedemaemorrhagic contusion	38	37.25
Dural breach	30	29.41
Extra-dural haematoma	13	12.75
Subdural haematoma	8	7.84
Subarachnoid haemorrhage	7	6.86
Temporoparietal fracture	6	5.88
Craniocerebral wound	5	4.90
Rock fracture	4	3.92
Ethmoidal fracture	3	2.94
Cerebral oedema	3	2.94
Sphenoidal sinus fracture	2	1.96
Frontal hygroma	1	0.98
Subarachnoid haemorrhage	1	0.98

**Figure 4.** Axial craniofacial CT scan: (bone window (A): comminuted fracture of both walls of the left frontal sinus with pneumocephalus and parenchymal window (B): blade of acute left frontal extradural haematoma) in a 22-year-old patient with RTA of the motorbike type.

by wound repair (20.59% of cases), orthopaedic treatment (6.86% of cases) under local anaesthetic and osteosynthesis using 4/10ths steel wire sutures (14.70% of cases) under general anaesthetic. The operation was performed either by the neurosurgery and/or maxillofacial surgery teams. The average delay for surgery was 6.6 days, with extremes of one and 21 days. The approach for repair of frontal sinus fractures was coronal in 14 (70%) patients, trans-cicatricial in five (25%) patients and frontal-medial in one (5%) patient. Reduction of the front



embarrure plus fixing with screw plates was performed in 13 (65%) patients, followed by cranialization in 11 (55%) patients (**Table 6**). Several surgical procedures were performed at the same time on the same patient. The post-operative course was favourable in the 20 patients who underwent the operation, although aesthetic sequelae such as unsightly scars and frontal depression occurred in seven and three patients respectively. In the other patients for whom abstention was indicated, there were 30 cases of frontal depression and unsightly scars, seven cases of chronic headaches, six cases of meningitis, three cases of persistent rhinorrhoea, one case of brain abscess and one case of anosmia. The cases of meningitis and brain abscess were transferred to the Infectious Diseases Department, where an antibiotic therapy protocol using injectable ceftriaxone brought the infection under control. All patients in the study were monitored for between one and three months.

#### 4. Discussion

A total of 102 cases of frontal sinus fractures were reported, giving an annual average of 34 cases. This average is higher than that reported by Mabika *et al.* [16] and Mahran *et al.* [5], who reported respective averages of 12 and 25.6 cases per year. The high frequency of frontal sinus fractures in this study could be explained by the fact that the data were collected in two departments (maxillofacial and neurosurgery) and by the predominance of RTAs (90.20%) frequently involving drivers of two-wheeled machines (98.20%) without helmets. Mabika *et al.* [16] and Mahran *et al.* [5] also found that RTAs predominated in 72.22% and 49% of cases respectively. In developed countries, on the other hand, the incidence of frontal sinus fractures has declined over the last 20 years thanks to improved living standards and the use of public transport [17]. Fractures of the frontal sinus seem to be the prerogative of young males and this was confirmed by this study which reported a mean age of 29.9 years and 94.10% of males [4] [5] [16] [18].

The clinical signs found in this series are consistent with those reported in the literature [19]. Type III of frontal fractures according to the classification of Ioannides *et al.* [10], accounted for more than half the cases (51.9%). Lopez *et al.* [20] made the same observation, with a frequency of 50.1%. On the other hand, Mahran *et al.* [5], Bell *et al.* [21] and Schultz *et al.* [4] reported a predominance

**Table 6.** Distribution of patients according to surgical procedure (n = 20).

Surgical procedure	Headcount (n = 20)	Frequency (%)
Reduction of the front embarrure plus fixation with a screw plate	13	65%
Cranialization of the sinus	11	55%
Dural repair	8	40%
Trimming of craniocerebral wounds	5	25%
Bone reconstruction with iliac graft	1	5%



of anterior wall fractures (Type I of Ioannides *et al.*) with frequencies of 53%, 59.5% and 89.7% respectively. Mabika *et al.* [16], on the other hand, reported the predominance of type IV frontal fractures according to Ioannides *et al.* [10]. The type of injury varied from one author to another. The absence of helmets in all the patients in this series is thought to be correlated with the extent of the injuries (fractures of both tables of the frontal sinus). Furthermore, structurally, the posterior table is thin (0.1 - 4 mm) and generally offers little protection to the intracranial contents, whereas the anterior table has an average thickness of 2 - 12 mm and requires a pressure of approximately 360 - 1000 pounds for a fracture to occur [2]. Consequently, the majority of frontal sinus fractures are secondary to high kinetic energy impacts, with a significant risk of associated facial and extra-facial injuries [2]. This would explain the predominance of associated maxillofacial fractures (45.10%) and cranioencephalic injuries (44.12%) found in the patients in the present study. Johnson *et al.* [3] also found that 79.6% of patients had associated maxillofacial fractures and 61.8% cranioencephalic injuries. In addition to these injuries, Schultz *et al.* [4] reported intra-thoracic injuries (17%), intra-abdominal injuries (5%), vertebral column (13%) and long bone fractures (17%), which were not found in this study. The management of frontal sinus fractures in our setting often involves both maxillofacial surgeons and neurosurgeons. Surgical abstention (conservative treatment) was observed in 80.39% of patients. This frequency is comparable to Schultz *et al.* [4] who observed conservative treatment in 80.4% of patients. However, Lopez *et al.* [20] found that conservative treatment represented an average frequency of 32.9% of cases following a review of the literature. According to the management algorithms for frontal sinus fractures proposed by the authors, there is no consensus on the indication for conservative treatment [7] [8] [19] [21]. For some authors, it is indicated in cases of non-displaced fractures (less than 1 - 2 mm) of the anterior wall [8] [21]. For others, the indication for conservative treatment depends on whether the nasofrontal canal and the posterior table of the frontal sinus have been affected [7] [19]. However, in the present study, conservative treatment was indicated not only in cases of non-displaced frontal sinus fractures but also in situations where there was a financial barrier to surgery.

Surgical management was performed in 19.61% (20) of patients under general anaesthesia. The average time to surgery was 6.6 days. This was less than the 12 days reported by Chegini *et al.* [11]. However, for Bellamy *et al.* [15], a delay of more than 48 hours was associated with a high risk of complications. There is no consensus among authors as to the ideal delay for surgical intervention, since it is thought to be related to the type of injury [6] [15] [16]. Indeed, correction of anterior table fractures should be delayed by at least 7 to 10 days following the trauma to allow resolution of swelling and clear delineation of the frontal deformity [6].

The aim of surgical treatment of frontal sinus fractures is to preserve sinus function, ensure a seal between the nasal cavity and the brain, prevent infection and restore facial aesthetics [11]. To achieve this, several approaches and surgical

procedures have been reported [7] [8] [21].

The coronal approach was preferred in 70% of cases in this series. It is the preferred approach [5] [21]. It has the advantage of better exposure to bony injuries. However, it is more invasive, extends the operating time and results in more blood loss. The main disadvantage is the occurrence of alopecia, which can be avoided by a zigzag incision [19]. The approach can be made through the traumatic wound (trans-cicatricial), as was the case in the present study in 25% of patients. This frequency was higher than that reported by Mabika *et al.* [16] and Mahran *et al.* [5], who reported frequencies of respectively 16.7% and 8.5% of cases. The trans-cicatricial approach allows easy, direct and non-invasive exposure of the frontal sinuses, but has the disadvantage of scarring which can be minimised by respecting the skin tension lines [8].

The choice of this approach was motivated by the existence of a relatively large forehead wound that could be used as a minimally invasive approach with minimal scarring. A direct forehead incision was made in one patient in this series. The direct transcutaneous approach to the forehead allows direct access to the fracture site with less operating time and blood loss than the coronal approach. However, it is responsible for unsightly forehead scars and hypoesthesia secondary to damage to the supraorbital and supratrochlear nerves [8]. Finally, the endoscopic approach, which was not used in this study, is an alternative to the other approaches. It is less invasive and makes it possible to check the integrity and patency of the nasofrontal canal. However, closed reduction is best suited to simple anterior table fractures with few fragments. The major disadvantage is that it is impossible to assess the effectiveness of the reduction with any certainty [8] [22]. Equipment for the endoscopic approach is not available in our context.

In terms of surgical procedures, Reduction of the front embarrure plus fixation with a screw plate was performed in 13 (65%) cases. It is indicated for displaced anterior table fractures (greater than 2 mm) with or without posterior table involvement. It may be the only treatment, as in the study by Bell *et al.* [21], where it represented 58% of the treatment. In the case of loss of substance of the anterior table, reconstruction may be performed using biomaterials or a graft [6] [16]. The only iliac graft taken in this series was used for this reconstruction. The economic profitability of the graft motivated our choice of biomaterials, which are not accessible to the majority of patients. Cranialization of the sinus was performed in 11 (55%) cases. This frequency is higher than those reported by Mahran *et al.* [5], Lopez *et al.* [20] and Schultz *et al.* [4], who reported frequencies of 28.5%, 17.2% and 6.2% of cases respectively. In fact, it is indicated in complex, comminuted fractures of the posterior wall of the frontal sinus involving the nasofrontal canal. This is an invasive procedure involving complete resection of the posterior wall of the frontal sinus, meticulous removal of the entire sinus mucosa, milling of the bony walls and obturation of the nasofrontal canal [19] [21]. It was frequently performed in this study because of the severity of the injuries and the surgeon's experience. Sinus obliteration, which is indicated in

certain fractures of the frontal sinus with damage to the nasofrontal canal but with a stable posterior table, was not performed in this study. It consists of filling the sinus cavity with autologous grafts or biomaterials. However, grafts, particularly fat grafts, are more effective due to their high biocompatibility [19]. The dural repair was carried out in 8 (40%) cases in the form of direct sutures or by plasty according to the principles described. It follows the obliteration or crania- lization of the frontal sinus [19]. This repair was indicated for fractures of the posterior wall of the frontal sinus associated with damage to the dura mater with or without cerebrospinal fluid drainage. Even if all the aims of frontal sinus fracture management outlined above have been achieved, long-term follow-up is essential. Patients were monitored for periods ranging from one to three months, during which time complications and sequelae were noted. Complications such as meningitis (6 cases), brain abscesses (1 case) and sequelae such as frontal de- pression (30 cases), unsightly scars (30 cases), chronic headaches (7 cases), per- sistent rhinorrhoea (3 cases) and anosmia (1 case) were noted in the patients who received conservative treatment. These same complications have been reported by other authors with varying frequency [3] [5] [15]. The occurrence of certain complications could be explained by the financial barrier, which prevented sur- gery from being performed on eligible patients. In addition, only three patients were vaccinated against pneumococcal disease, for the same reasons of financial need. As for the patients who were operated on, the after-effects were unsightly scars (7 cases) and frontal depression (3 cases). These sequelae can be explained by the importance of soft tissue injuries and insufficient correction of the frac- tures of the anterior table of the frontal sinus.

## 5. Limits to the Study

The limits of this study are attributable to its retrospective nature. As the data were collected from medical records, it was difficult to explain with certainty all the information collected, as the patient was not present. In addition, follow-up lasted between one and three months, which is insufficient in relation to the oc- currence of certain complications such as mucoceles and osteitis of the frontal bones. Finally, the data are not so recent, as the study involved patients from 2016 to 2018. Indeed, the work was part of a medical thesis that began in 2019 and was not defended on time. However, although more recent data is required, it has provided insight into the management of frontal sinus fractures in our set- ting.

## 6. Conclusion

Fractures of the frontal sinus are relatively frequent in our context. However, their management remains a challenge in view of the financial barrier to care and the limited technical resources available. Complications and sequelae result, making management complex in the context of limited resources. Prevention through compliance with road safety measures, including the wearing of hel-

mets, and the removal of financial barriers to care, could both reduce the number of cases and improve the way patients are managed.

### Conflicts of Interest

The authors declare no conflicts of interest regarding the publication of this paper.

### References

- [1] Giovanni, G., Fabio, R., Arnaldo, B. and Claudio, C. (2000) Analysis of 158 Frontal Sinus Fractures: Current Surgical Management and Complications. *Journal of Cranio-Maxillofacial Surgery*, **28**, 133-139. <https://doi.org/10.1054/jcms.2000.0134>
- [2] Nahum, A.M. (1975) The Biomechanics of Maxillofacial Trauma. *Clinics in Plastic Surgery*, **2**, 59-64. [https://doi.org/10.1016/S0094-1298\(20\)30097-3](https://doi.org/10.1016/S0094-1298(20)30097-3)
- [3] Johnson, N.R. and Roberts, M.J. (2021) Frontal Sinus Fracture Management: A Systematic Review and Meta-Analysis. *International Journal of Oral and Maxillofacial Surgery*, **50**, 75-82. <https://doi.org/10.1016/j.ijom.2020.06.004>
- [4] Schultz, J.J., Chen, J., Sabharwal, S., Halsey, J.N., Hoppe, I.C., Lee, E.S., et al. (2019) Management of Frontal Bone Fractures. *Journal of Craniofacial Surgery*, **30**, 2026-2029. <https://doi.org/10.1097/SCS.00000000000005720>
- [5] Mahran, H., Elshamaa, M., Abdelfattah, M., Mohammed, M., Abdelhamid, A. and Elborolsy, S. (2023) Epidemiology and Outcome of Management of Frontal Sinus Fractures. *Egyptian Dental Journal*, **69**, 111-117. <https://doi.org/10.21608/edj.2022.174257.2345>
- [6] Vincent, A., Wang, W., Shokri, T., Gordon, E., Inman, J.C. and Ducic, Y. (2019) Management of Frontal Sinus Fractures. *Facial Plastic Surgery*, **35**, 645-650. <https://doi.org/10.1055/s-0039-3399521>
- [7] Doonquah, L., Brown, P. and Mullings, W. (2012) Management of Frontal Sinus Fractures. *Oral and Maxillofacial Surgery Clinics of North America*, **24**, 265-274. <https://doi.org/10.1016/j.coms.2012.01.008>
- [8] Delaney, S.W. (2016) Treatment Strategies for Frontal Sinus Anterior Table Fractures and Contour Deformities. *Journal of Plastic, Reconstructive & Aesthetic Surgery*, **69**, 1037-1045. <https://doi.org/10.1016/j.bjps.2016.06.006>
- [9] Dedhia, R.D., Morisada, M.V., Tollefson, T.T. and Strong, E.B. (2019) Contemporary Management of Frontal Sinus Fractures. *Current Opinion in Otolaryngology & Head and Neck Surgery*, **27**, 253-260. <https://doi.org/10.1097/MOO.0000000000000546>
- [10] Ioannides, C. and Freihofer, H.P. (1999) Fractures of the Frontal Sinus: Classification and Its Implications for Surgical Treatment. *American Journal of Otolaryngology*, **20**, 273-280. [https://doi.org/10.1016/S0196-0709\(99\)90027-3](https://doi.org/10.1016/S0196-0709(99)90027-3)
- [11] Chegini, S., Gallighan, N., Mcleod, N., Corkill, R., Bojanic, S., Griffiths, S., et al. (2016) Outcomes of Treatment of Fractures of the Frontal Sinus: Review from a Tertiary Multispecialty Craniofacial Trauma Service. *British Journal of Oral and Maxillofacial Surgery*, **54**, 801-805. <https://doi.org/10.1016/j.bjoms.2016.05.016>
- [12] Raveh, J., Laedrach, K., Vuillemin, T. and Zingg, M. (1992) Management of Combined Fronto-naso-Orbital/Skull Base Fractures and Telecanthus in 355 Cases. *Archives of Otorhinolaryngology-Head & Neck Surgery*, **118**, 605-614. <https://doi.org/10.1001/archotol.1992.01880060053014>
- [13] Gonty, A., Marciani, R.D. and Adornato, C. (1999) Management of Frontal Sinus

- Fractures: A Review of 33 Cases. *Journal of Oral and Maxillofacial Surgery*, **57**, 372-379. [https://doi.org/10.1016/S0278-2391\(99\)90270-7](https://doi.org/10.1016/S0278-2391(99)90270-7)
- [14] Stanley, R.B. (1989) Fractures of the Frontal Sinus. *Clinics in Plastic Surgery*, **16**, 115-123. [https://doi.org/10.1016/S0094-1298\(20\)31372-9](https://doi.org/10.1016/S0094-1298(20)31372-9)
- [15] Bellamy, J.L., Molendijk, J., Reddy, S., Flores, J.M., Munding, G.S., Manson, P.N., et al. (2013) Severe Infectious Complications Following Frontal Sinus Fracture: The Impact of Operative Delay and Perioperative Antibiotic Use. *Plastic and Reconstructive Surgery*, **132**, 154-162. <https://doi.org/10.1097/PRS.0b013e3182910b9b>
- [16] Mabika, B.D.D., Ngoua, L., Aziz, Z., Garango, A., Bouihi, M. and Mansouri, N.H. (2019) Appropriate Pathways and Surgical Approaches in the Fractures of the Frontal Sinus. *International Journal of Oral and Maxillofacial Surgery*, **5**, 22-28. <https://doi.org/10.11648/j.ijcoms.20190501.16>
- [17] Jing, X.L. and Luce, E. (2019) Frontal Sinus Fractures: Management and Complications. *Craniofacial Trauma & Reconstruction*, **12**, 241-247. <https://doi.org/10.1055/s-0038-1675560>
- [18] Calis, M., Kaplan, G.O., Küçük, K.Y., Altunbulak, A.Y., Akgöz Karaosmanoğlu, A., Işıkay, A.İ., et al. (2022) Algorithms for the Management of Frontal Sinus Fractures: A Retrospective Study. *Journal of Cranio-Maxillofacial Surgery*, **50**, 749-755. <https://doi.org/10.1016/j.jcms.2022.09.007>
- [19] Strong, E.B. (2009) Frontal Sinus Fractures: Current Concepts. *Craniofacial Trauma & Reconstruction*, **2**, 161-175. <https://doi.org/10.1055/s-0029-1234020>
- [20] Lopez, C.D., Rodriguez Colon, R., Lopez, J., Manson, P.N. and Rodriguez, E.D. (2022) Frontal Sinus Fractures: Evidence and Clinical Reflections. *Plastic and Reconstructive Surgery*, **10**, e4266. <https://doi.org/10.1097/GOX.0000000000004266>
- [21] Bell, R.B., Dierks, E.J., Brar, P., Potter, J.K. and Potter, B.E. (2007) A Protocol for the Management of Frontal Sinus Fractures Emphasizing Sinus Preservation. *Journal of Oral and Maxillofacial Surgery*, **65**, 825-839. <https://doi.org/10.1016/j.joms.2006.05.058>
- [22] Gal, T.J. and Pappal, R. (2021) Delayed Endoscopic Assisted Percutaneous Reduction of Anterior Table Frontal Sinus Fractures. *Otolaryngology Case Reports*, **19**, Article ID: 100282. <https://doi.org/10.1016/j.xocr.2021.100282>